

RIGA STRADINS UNIVERSITY
DEPARTMENT OF ORAL AND MAXILLOFACIAL
SURGERY

KASPARS STĀMERS

**SALIVARY GLAND MORPHOLOGY AND
FUNCTION IN CONDITIONS OF REDUCED AND
RESTORED REGIONAL BLOOD SUPPLY**

(Experimental study)
(speciality – oral and maxillofacial surgery)

SUMMARY OF PROMOTION WORK

Scientific supervisors:

Dr. habil. med., professor *Māra Pilmane*

Dr. habil. med., professor *Andrejs Skaģers*

Research work has been carried out by support of the ESF draft national programme
“Support of doctoral and post-doctoral studies in medicine”



RIGA 2010

The promotion work was performed in the Department of Oral and maxillofacial surgery of Riga Stradins University

Official reviewers:

Dr.hab.med., professor *Ingrīda Čēma* (Riga Stradins University)

Dr.habil.agr., Dr.med.vet. professor *Aleksandrs Jemeljanovs* (Latvia University of Agriculture)

Dr.hab.med., professors *Ričardas Kubilius*(Kaunas University of Medicine)

The defense of the Promotion Paper will take place on the 29th December, 2010, at 5.00 p.m. in an open session in the Biezina lecture-hall of Rīga Stradiņš University, Dzirciema st. 16

The Promotion Paper is available at the library of Riga Stradins University.

Secretary of the Promotion Council:

Dr. hab. med., professor *Ingrīda Čēma*

ABBREVIATIONS

GF	Growth factor
NGF	Nerve growth factor
FGF	Fibroblast growth factor
VEGF	Vascular endothelial growth factor
EGF	Epidermal growth factor
EGFR	Epidermal growth factor receptor
FGFR	Fibroblast growth factor receptor
NGFR	Nerve growth factor receptor p75
TNFα	Tumor necrosis factor α
IL10	Interleukine 10
IMH	Immunohistochemistry

INTRODUCTION

Normal functioning of salivary glands plays an important role in maintaining the oral and general health, food consumption and digestion. Salivary glands also perform the function of isolating metabolites and other chemical compounds, as well as having an endocrine function. The most common clinical non-oncological pathology deals mainly with reduced secretion of saliva, xerostomia and secondary pathology of the teeth and oral mucosa. So far experimentally, as well as clinically, there have been mostly studied salivary gland pathology in relation to the obstructive diseases of salivary pathways. Salivary gland pathology due to salivary reflux and its therapeutic possibilities are known now, thus preventing the obstruction of salivary output.

Although the vascularized a. carotis area without vital importance for brain includes also the oral, facial and jaw region, the latter is little studied as to the vascular pathology and little evaluated from a clinical aspect. One can find single publications (Skaĝers and co-authors 1981; Skaĝers 1985) on the ischemic disease of maxillofacial region, which involves also angiogenous atrophic and dystrophic changes of salivary glands. In the latest literature publications there are also practically no reports on correlations between widespread obliterating carotid area diseases and changes in maxillofacial organs. There is no information as to the effect of the reconstructive surgery of a.carotis on salivary gland revascularization, restoration of morphology and function. At the same time there is a great number of patients with decreased salivary secretion, xerostomia and diseases of the teeth and oral mucosa due to them. Occlusive carotid artery disease is greatly widespread and results in cerebrovascular disorders, for instance, stroke, which is quite a significant public

health problem. In 2004 in the USA stroke was diagnosed in one lethal case from 16 and each 4th case was due to carotid artery stenosis. 98000 patients were treated in hospital for stenoses by means of endarterectomy (American Heart Association 2007).

In 2008 in Latvia Pauls Stradins Clinical University hospital 339 carotid artery endarterectomies were performed on 317 patients. In 59% cases carotid artery disease was asymptomatic (*Ivanova et al., 2009*). Commonly encountered carotid artery obliterating atherosclerosis of various degree cannot eventually be without any consequences in relation to maxillofacial organs, although more pronounced ischemic symptoms are not a common phenomenon and, similarly to cerebral ischemia, can often be asymptomatic.

AIM

To investigate morphologic and functional changes of major salivary glands in cases of carotid artery occlusion and possibilities for the identified change regression after restoration of regional circulation in experimental conditions.

OBJECTIVES

1. To make an experimental model of ischemic disease of major salivary glands.
2. To evaluate the major salivary gland function in rabbits by scintigraphy after ischemia and revascularization.
3. To do morphological and morphometric examination of major salivary glands in experimental animals after a.carotis communis ligature and reconstruction of the closed part.
4. To determine the growth factor in rabbits' major salivary glands in the control and test side after ischemia and revascularization: NGF, FGF, VEGF and growth factor receptors NGFR, FGFR and EGFR.
5. To determine tissue degeneration cytokines IL-10 and TNF α in rabbits' major salivary glands in the control and test side after ischemia and revascularization.
6. To determine apoptosis in rabbits' major salivary glands in the control and test side after ischemia and revascularization.
7. To analyze the obtained data statistically.
8. To formulate and write conclusions.

HYPOTHESIS OF STUDY

1. Reduction of regional arterial blood supply causes morphological and functional changes in salivary glands.
2. Reconstruction of closed a.carotis communis can decrease morphological and functional disorders of salivary glands.

Structure and volume of study

Promotion thesis is written in the Latvian language. It contains 11 parts: introduction, literature survey, material and methods, results, discussion, conclusions, list of literature and appendix. Thesis comprises 143 pages, including the tables, pictures and appendix. The list of literature includes 250 references. There have been 13 reports on the promotion theme delivered in conferences, 14 theses and 6 publications.

1. Material and methods

1.1. Structure of study

In the study experiment were used 30 female rabbits of Californian breed. The average weight of rabbits was 3 kg. In order to do the experimental study, a permission had to be acquired from LR Food and Veterinary Service. Rabbits were divided into 3 groups: 20 rabbits for the investigation of ischemia, 10 rabbits for revascularization.

Surgical manipulations were carried out at Experimental Animal Laboratory of Riga Stradins University hospital. Post-operative follow-up was done by a certified veterinary doctor. No general health disorders in experimental animals were observed.

Unilateral a.carotis communis ligation was performed in the right side under general anesthesia. Intramuscular injection of ketamine hydrochloride solution of 15mg/kg and diazepam solution of 0.5 mg/kg were used for anaesthesia. For local sedation 1% lidocaine solution of 4 mg/kg was used.

Using transdermal approach the skin and subcutaneous layer were incised, performing the incision along *m.sternocleidomastoideus* anterior margin, dissecting the vascular bundle and identifying a.carotis communis and the ligation was done by 2-0 silk for about 2 cm below the bifurcation. The wound was closed by layers with poliglactine (Vicryl 3-0) sutures.

After 4 weeks 20 rabbits were performed the major salivary gland functional examination by technetium 99 pertechnate (Tc99) scintigraphy method (*Hakim et al., 2002*). Scintigraphy was done under general anesthesia using the above-mentioned preparations. After examination the rabbits were removed from the experiment by intrapulmonary T61 injection. Major salivary glands were removed. Histological material was fixed in Stefanini solution, emerged in paraffin, 3-5 micron thick cuts were done and stained by hematoxylin and eosine. By immunohistochemical means VEGF, NGF, NGFR, FGF, FGFR1, EGFR, IL-10 and TNF alfa expression and apoptosis indices (TUNEL) were stated in the preparations. Preparations were analyzed under classical light microscope.

According to the above-mentioned anaesthesia protocol, 10 rabbits being under general anaesthesia were performed elimination of a.carotis communis closure by means of microsurgery. Two methods were used: resection of the ligated site and vascular anastomosis or autovenous transplantation. In the operation the magnifying glasses 6x (*Clarks Optical, UK*) and 8-0 monofilament (*Ethicon*) suture material were used. Prior to introduction of anastomosis, the artery was flushed intravasally by heparin solution.

Functional examination of revascularized salivary glands was done 4 weeks after blood flow restoration under general anaesthesia with a following euthanasia of experimental animals according to the above-mentioned protocol. There was performed morphological and immunohistochemical examination of salivary glands, determining VEGF, NGF, NGFR1, FGF, FGFR1, EGFR, IL-10 and TNF alfa expression and apoptosis indices (TUNEL).

For control material the opposite side salivary glands were chosen and those of non-operated rabbits.

The obtained histological material is being preserved at the Morphological Laboratory of RSU Institute of Anatomy and Anthropology, where are carried out histological and immunohistochemical examinations.

1.2. Scintigraphy of salivary glands

Scintigraphy was performed at the Institute of Diagnostic Radiology of Pauls Stradins Clinical University hospital.

Gamma camera Siemens E.CAM (*Siemens Medical Solutions Ltd*, ASV) was used, rabbits, being under anaesthesia, were introduced i/v bolus dose with technetium pertechnetate in a dose of 6 MBq/kg. The rabbit was positioned spinally. Dynamic scintigraphy was done by 64x64 pixels with a 30 second time window just after Tc99 introduction, on the 15th examination minute the lemon juice was introduced per os to stimulate the salivary secretion. Total examination took 30 minutes. Accumulation phase of salivary glands was measured and the measurements were expressed in the number of impulses per one second, in such a way the test and control sides were compared, as well as isotope removal from the gland both on the test and control side (*Hermann et al.*, 1999).

1.3. Morphological method

Salivary gland tissues were fixed in Stefanini solution for 24 hours, dehydrated and emerged into paraffin block. The block, by means of microtome, was cut into 5 – 8 µm thick cuts and stained with hematoxylin and eosine (*Лилли*, 1969). After this staining the acidophilic cell parts were stained in pink to crimson, but basophilic parts – blue-violet.

For testing of the preparations there was used *Leic DC300F* microscope with 400x magnification. Histological preparations were investigated descriptively and morphometrically. Glandulocyte and acinus diameters of salivary glands were measured by oculars which were equipped with a micrometer. These measurements were done in the parotid gland, submandibular and buccal glands. Measurements of test side glands were compared to those of the control side. By *Image Pro Plus 4.1* version (*Media Cybernetics*, Silver Springs, ASV) there were acquired digital images of preparations and by analysis of picture structure, using isoline method of optical density (*Grandis et al.*, 1996; *Salma et al.*, 2001), the parenchyme and stroma relationship was determined in the test and control sides of salivary glands after ischemia and after revascularization (*Butler et al.*, 2003).

1.4. Immunohistochemistry method

Samples were fixed in 4-8 hrs mixture, which contained 2% formaldehyde and 0.2% picric acid 0.1 M phosphate buffer (pH 7,2), called Stefanini solution (*Erjefält et al.*, 1995). Samples were washed for 12 hrs in thyroid buffer, which contained 10% saccharose, then they were emerged into paraffin and cut by the microtome into 3-5 µm thick sections.

1.4.1. Biotin streptavidine method

3-5 µm thick sections were stained by Biotin – streptavidine method (*Hsu et al.*, 1981)
Table 1. Information on growth factors used, their receptors and cytokines by biotin-streptavidine method.

Factor	Antibody obtained from	Code	Solution	Source
TGF α	Mouse	1279	1: 1000	Cambridge Science Park, UK
FGF	Rabbit	16828	1:200	Cambridge Science Park, UK

FGFR1	Rabbit	10646	1:100	<i>Abcam, UK</i>
NGF	Rabbit	AB6199	1:500	<i>Abcam, UK</i>
NGFR1	Rabbit	M3507	1:150	<i>DacoCytomation, Dānija</i>
TNFα	Rabbit	ab6671	1:200	<i>Cambridge Science Park, UK</i>
EGFR1	Mouse	M3562	1:150	<i>DacoCytomation, California, USA</i>
IL10	Rabbit	ab 34843	1: 400	<i>Abcam, UK</i>

1.4.2. Designation of the relative frequency of immunohistochemical examinations

For the assessment of relative frequency of immunohistochemically determined indices, a semi-quantitative counting method was used which is widely described in the literature (*Tobin et al., 1990; Pilmane, 1997*). Frequency of factor expression was analyzed in three visual fields of one section (Table 2).

Table 2. For designation of relative frequency of semi-quantitative method

0	Positive structures are not found in visual field
0/+	Very few positive structures in visual field
+	Small amount of positive structures in visual field
++	On average, many positive structures in visual field
+++	Very many positive structures in visual field

1.5. TUNEL method

For determination of apoptosis by TUNEL method, there was used apoptosis set: „In Situ Cell Death Detection”, POD catalogue number 1684871, Roche Diagnostics DNase I (Roche) in accordance with *Negoescu et al.*, the protocol described in 1998, where apoptotic cell nuclei were stained in brown colour.

In order to process the data of TUNEL method, there was used the apoptotic index, where at randomly selected 3 visual fields the number of apoptotic cells out of 100 cells was counted, then the average number of cells was determined and the result divided by 100 (*Kandirali et al., 2009*).

1.6. Methods of data statistical analysis

For the processing of the scintigraphy, morphometry, growth factor semi-quantitative and apoptosis data, there was used the descriptive statistical methods (*Bland, 1986; Altman, 1991; Altman, 2000; Teibe, 2006*). For the comparison of study groups – test and control groups, there were used central tendency indicators with mean values and standard deviation,

dispersion rate and representation rates. For statistical analysis Student t test and single factor dispersion analysis (ANOVA) were used. To state the mutual evaluation of conformity closeness of two variables, correlation and linear regression analysis methods were used. Relationship between variables was estimated, using Pearson correlation and Spearman range scale correlation. Values which do not comply with normal probability distribution are represented by non-parametric statistical method – Chi square test. To make a statistical calculation, *PASW statistics V18.0* programme was used.

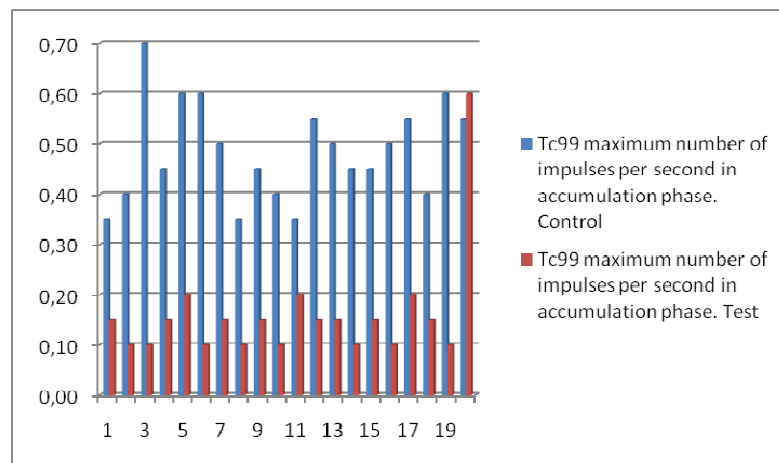
2. Results

2.1. Scintigraphy of salivary glands

Scintigraphy was used to determine the function of salivary glands, to determine buccal and parotid salivary gland function after ligation of a.carotis and after revascularization.

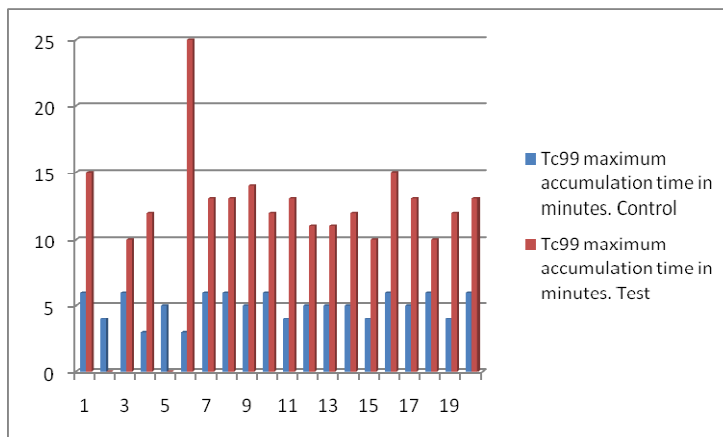
2.1.1. Scintigraphy of salivary glands 28 days after ischemia

Scintigraphy was used for detection of rabbits' buccal and parotid salivary gland functions in two stages of the experiment – 28 days after unilateral a.carotis communis ligation and 28 days after revascularization of the ligated artery. Buccal and parotid salivary glands after 28-days-long ischemia demonstrated the following functional activity: after intravenous introduction of Technetium pertechnetate into the right side salivary glands, there was observed a slight accumulation of radioactive isotope – on average 0.13 impulses per second with standard deviation 0.04; the left side salivary glands accumulated the isotope two to three times faster – on average 0.49 impulses per second with standard deviation 0.12. The difference between the control and test side salivary gland results was 0.34 impulses per second. Mean standard error in test and control side gland was 0.02 and statistic significance for test and control groups $p=0,001$. Correlation between these measurements was 0,6 - moderate (Picture 1).



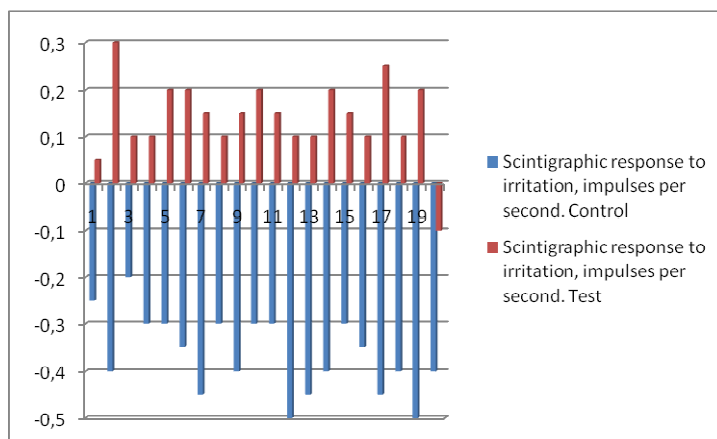
Picture1. Tc⁹⁹ maximum number of impulses per second in accumulation phase after 28-day-long ischemia.

Setting the time which is used for reaching maximum Tc^{99} concentration in salivary glands, by which the accumulation phase gets completed, the following results were acquired – the test side salivary glands required on average 13 minutes, but the control side salivary glands – five minutes. Standard deviation on the test side was 3 minutes and 20 seconds with a mean standard error 0.79, but on the control side -standard deviation was 1 minute with a mean standard error 0.30. Two of the rabbits on the test side were seen to have unchanged isotope accumulation curve. Statistical significance, comparing the test and control groups, was $p=0.001$. Correlation of results was 0.16 - poor (Picture 2).



Picture 2. Tc^{99} maximum accumulation time in minutes after 28-day-long ischemia.

Elimination of the isotope from salivary glands on test and control sides proceeded differently. After stimulation of salivary glands with the lemon juice on the test side, there was seen an extra isotope accumulation on average by 0.14 impulses per second with standard deviation 0.08 and the mean standard error 0.02, but after stimulation of salivary glands on the control side, one could observe a fast reduction of the amount of isotope on average by 0.37 impulses per second with standard deviation 0.08 and the mean standard error 0.02. Statistic significance $p=0.001$ with an average correlation 0.51 (Picture 3).

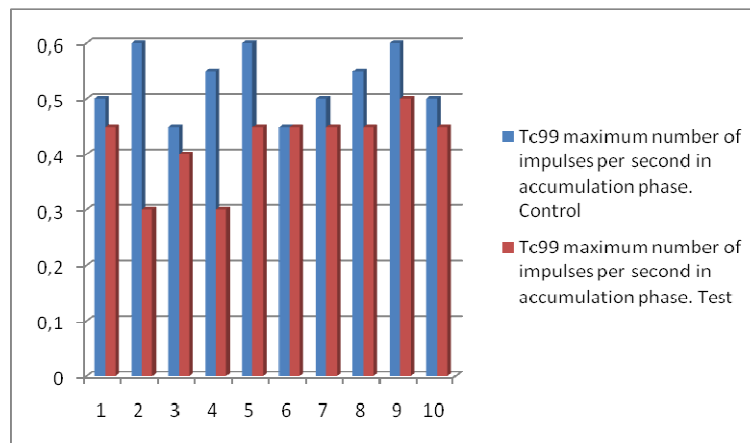


Picture 3. Scintigraphic response to irritation, impulses/per second after 28-day-long ischemia.

2.1.2. Scintigraphy of salivary glands 28 days after revascularization

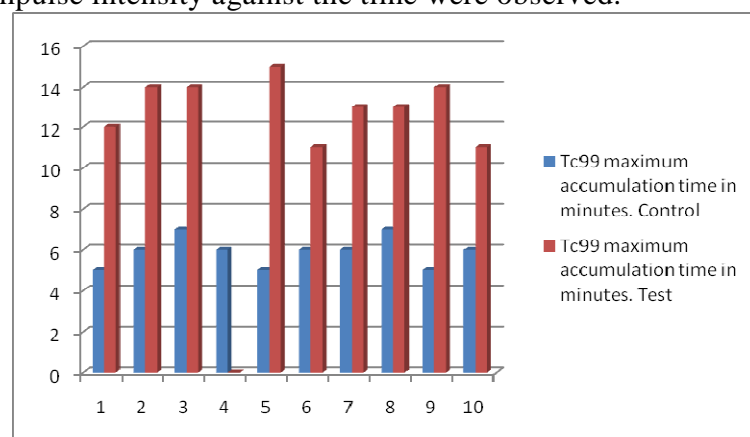
In the second study group, 28 days after a carotis communis ligature, there was performed revascularization and, respectively, 28 days later, sialoscintigraphy was done. Buccal and parotid salivary gland on the test side showed functional improvement in comparison to rabbits which were performed only a carotis communis ligature.

Maximum isotope accumulation amount on the test side after revascularization on average is 0.42 impulses per second with standard deviation 0.06 and the mean standard error 0.02. On the control side the accumulation was on average 0.53 impulses per second with standard deviation 0.06 and the mean standard error 0.02 (Picture 4). Statistic significance of measurement p value is 0.006 and correlation 0.64 - moderate.



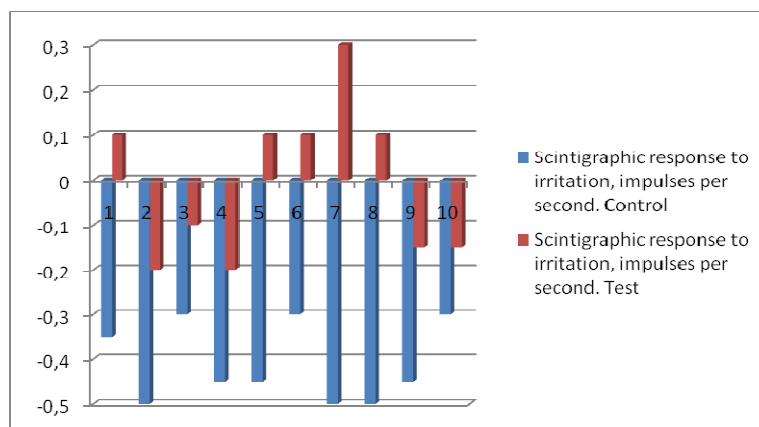
Picture 4. Number of maximum Tc⁹⁹ impulses per second in accumulation phase on test and control side salivary glands 28 days after revascularization.

The time for reaching the maximum accumulation level in revascularized salivary glands on the test side was on average the same as for the ligated group – 13 minutes with standard deviation 1 minute 24 seconds and the mean standard error 0,47. For salivary glands on the control side, in order to reach the maximum accumulation, there were needed on average 5 minutes 54 seconds with standard deviation 48 seconds and the mean standard error 0.26. Statistical significance $p=0,001$ and correlation $n=0.77$ - high (Picture 5). In one case no changes in impulse intensity against the time were observed.



Picture 5 Tc^{99} maximum accumulation time in minutes 28 days after a.carotis communis revascularization.

Doing the chemical stimulation of salivary glands with citric acid, there was seen the the ability of the salivary gland on the test side to excrete Tc^{99} . Comparing to the ligated group of salivary glands after stimulation, they in 19 cases of 29 continued to accumulate Tc^{99} . On the test side the ability of salivary glands to excrete the isotope after the number of chemical irritant impulses per second decreased on average by 0.01 impulses per second, yet the dispersion of measurements was wide - 0.17 impulses with the mean standard error 0.05. Five experimental animals out of ten were seen to have isotope excretion after the irritant, but five were seen to continue the accumulation. The results obtained on the control side showed isotope reduction on average by 0.41 impulses per second with standard deviation 0.09 and the mean standard error 0.03 (Picture 6). Statistical significance $p < 0.001$ with a close correlation 0.7.



Picture 6. Scintigraphic response (impulses/per second) to irritation 28 days after a.carotis communis revascularization.

2.2. Morphology of salivary glands

2.2.1. Morphology of salivary glands 28 days after ischemia

2.2.1.1. Morphology of buccal salivary glands 28 days after ischemia

Histological preparations of the buccal salivary glands of the test side in hematoxylin and eosine staining after 28-day-long ischemia were seen to have an increased interstitial connective tissue amount in comparison to the control group preparations. There were found signs of atrophy of ischemic buccal salivary gland acinus epithelium and the ductal epithelium, as well as interstitial edema. Acinus and the ductal epithelium atrophy was seen to form areas of their concentration. We observed also the multiplication of fibrous connective tissues. Increased amount of connective tissues was found mainly around the ducts and separate parenchymal islets. Secretion granules at acinus lumen and in the apical part of acinus epithelium were not found.

On the control side the buccal salivary gland after 28-day-long opposite side ischemia was similarly seen to have a moderate concentration of parenchymal atrophy with a slight multiplication of connective tissues. Next to buccal salivary gland parenchymal

atrophy regions there were found signs of hyperplasia of regenerative acinus epithelium. Against the hyperplazed acinus in epithelium lumen there are seen secretion granules.

2.2.1.2. Parotid salivary gland morphology 28 days after ischemia

In hematoxillin and eosine staining in parotid salivary glands after 28-day-long ischemia on the test side, there were seen changes due to venous stasis. In separate parotid salivary glands, there were seen diffusely hyperplazed gland acinary epithelium cells. Around separate ducts there was found a slight connective tissue edema. In the tissues around the ducts there was seen also a moderate lipomatosis and multiplication of connective tissues. Here and there one could find myoepithelial cell vacuolization.

On the control side of parotid salivary glands after 28-day-long ischemia, there was found the concentrated acinary epithelium cell hyperplasia, the control side parotid salivary gland structure was without pronounced pathological changes.

2.2.1.3. Submandibular salivary gland morphology 28 days after ischemia

Submandibular salivary gland changes on the test side after 28-day-long ischemia were seen to have acinus epithelium hyperplasia process. There was also seen a slight increase of connective tissue amount around the ducts. Concentration of connective tissue edema was found around the glandular ducts.

In submandibular salivary glands on the control side some rabbits were seen to have concentration of regenerative hyperplasia. The rest of histological preparations in hematoxillin and eosine staining were of normal structure and without any pathology.

2.2.2. Morphology of salivary glands 28 days after revascularization

2.2.2.1. Morphology of buccal salivary glands 28 days after revascularization

In the buccal salivary glands 28 days after a.carotis communis revascularization on the test side, total acinus hypertrophy and acinus epithelium atrophy were seen. In these regions secretion granules were not found. In acinus epithelium, here and there was seen a rare regenerative hyperplasia. Only in the lumen, against the hyperplazed epithelium, there were found secretion granules in great amount, as well as they were seen in the apical parts of hyperplazed epithelium cells. Hyperaemia was observed and small capillary repletion. In some places one could see the stasis with intravasal erythrocyte aggregation. Connective tissues were multiplying by concentrating around the secretory parts.

On the control side after revascularization of the opposite side, the changes in buccal salivary glands were seen as the concentration of acinus epithelial hyperplasia. Atrophy signs, in comparison to control preparation before revascularization, were less pronounced.

2.2.2.2. Morphology of parotid salivary gland 28 days after revascularization

In the parotid salivary glands on the test side 28 days after revascularization were observed venule repletion and dilatation. In capillaries, in some regions, one could see erythrocyte aggregation, as well as a slight interstitial connective tissue edema. Salivary gland ducts were lined by cubic epithelium.

The control side parotid salivary glands after revascularization were of normal structure.

2.2.2.3. Morphology of submandibular salivary glands 28 days after revascularization

In the submandibular salivary glands on the test side after revascularization were seen to have some epithelium duct cell proliferation, tiny blood vessel hyperaemia and a slight connective tissue edema around the ducts and secretory parts.

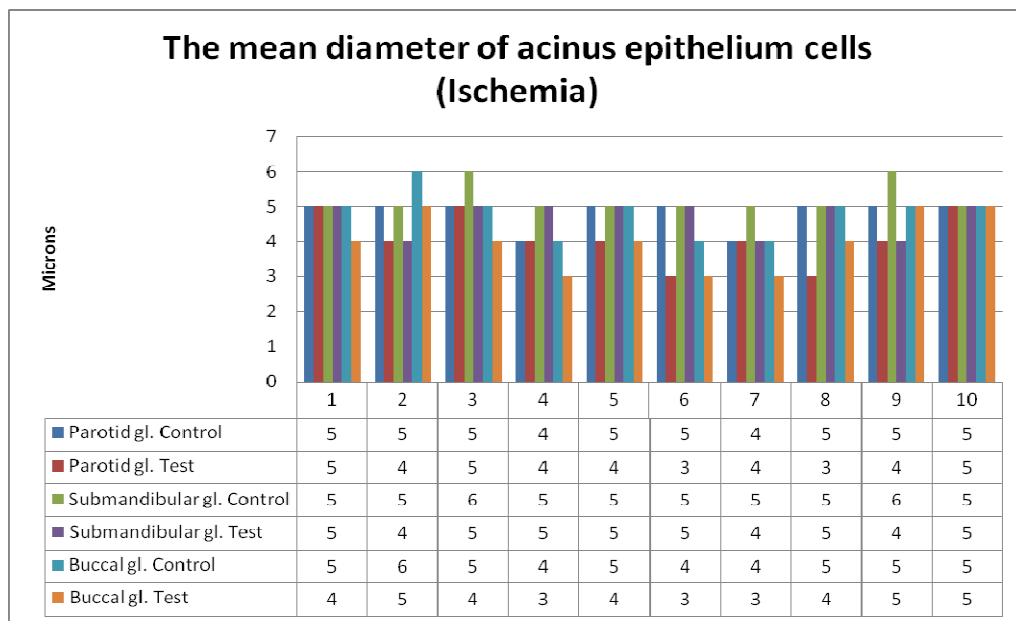
On the control side pathological changes in salivary glands were not seen. Salivary glands were of unchanged structure.

2.3. Morphometry of salivary glands

2.3.1. Acinus epithelium cells and acinus diameter 28 days after ischemia and 28 days after revascularization

2.3.1.1. Buccal salivary glands

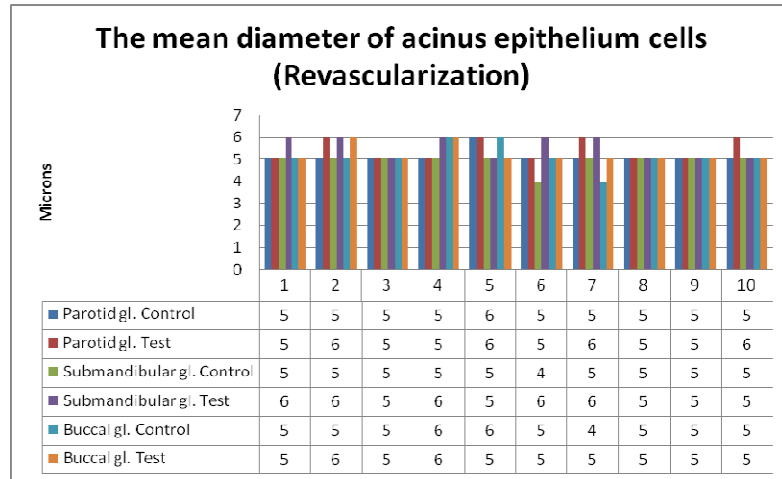
Diameter of acinus epithelium cells of buccal salivary glands on the test side after 28 day ischemia was on average 4.0 microns with mean value standard error 0.26 microns. On the control side the acinus epithelium cell diameter was on average 4.8 microns with the mean value standard error 0.2 microns. Comparing the control and test side cell diameters with the pair test, there was acquired the mean difference 0.8 microns with *t* value 6.0 and *p*<0.001 (Picture 7).



Picture 7. The mean diameter of acinus epithelium cells of salivary glands in microns after 28-day-long ischemia.

28 days after revascularization the buccal gland acinus epithelium cell diameters on the test side were on average 5.2 microns with the mean value standard error 0.13 microns and the control side cell diameter was on average 5.1 microns with the mean value standard error 0.18 microns. Comparing acinus epithelium cells on both sides by the pair test, we

acquired the difference 0.1 micron with t value 0.56 and p value 0.59. Thus, after revascularization the buccal salivary gland acinus epithelium cells do not have significant difference between the test and control side buccal salivary glands (Picture 8).



Picture 8. Mean diameter of salivary gland acinus epithelium in microns 28 days after revascularization.

The size of buccal salivary gland acinus was impossible to determine because acinus form was irregular.

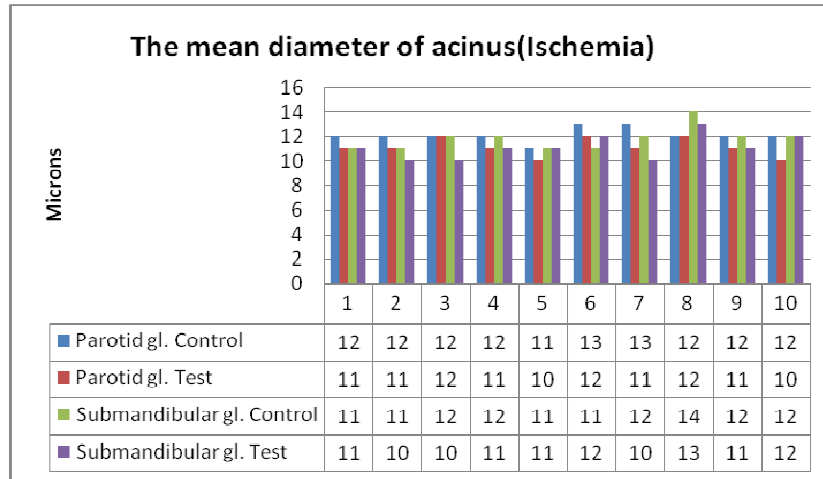
2.3.1.2. In parotid salivary glands

Acinary epithelium cell size of the parotid salivary glands on the test side after 28-day-long ischemia was on average 4.1 microns with the mean value standard error 0.23 microns, but the mean diameter of the control side gland epithelium cells was 4.8 microns with the mean value standard error 0.13 microns. Comparing the acinus epithelium cell diameter of control and test sides parotid salivary glands by the pair test, we acquired 0.7 micron difference, which is statistically significant $t=2.69$ and $p<0.025$ (Picture 7).

After revascularization the acinus epithelium cell diameter of parotid salivary glands on the test side was on average 5.4 microns with the mean value standard error 0.16 microns, but on the control side 5.1 microns with the mean value standard error 0.1 microns. Thus, the diameter of acinary epithelium of the revascularized side salivary gland is on average by 0.3 microns bigger. Processing the results by the pair test and comparing to the control and test groups after revascularization, we acquired $t=1.96$ and p value 0.08. Between these groups there exists a statistically significant difference (Picture 8).

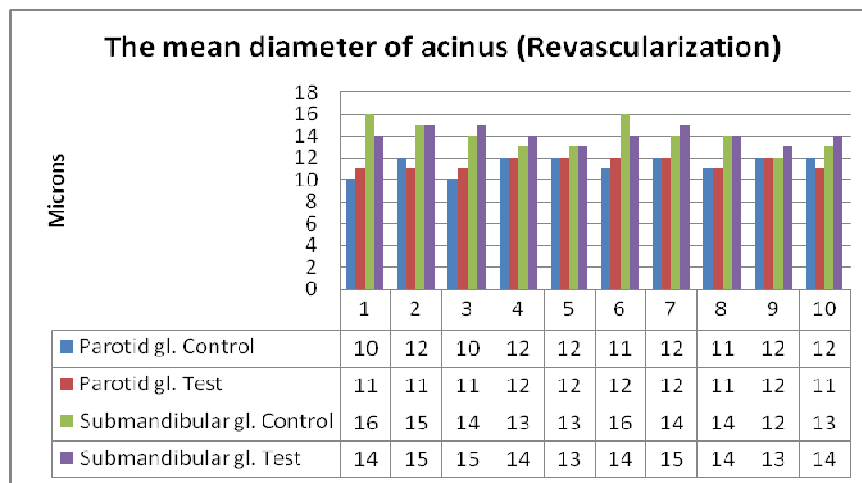
Mean diameter of acinus of the parotid salivary glands after ischemia on the test side was 11.1 microns with the mean value standard error 0.23 microns, on the control side 12.1 microns with the mean value standard error 0.18 microns. Comparing these indices, we

acquired on average by 1 micron statistically significant ($p < 0,001$) control and test group difference (Picture 9).



Picture 9. Acinus mean diameter of salivary glands after 28-day-long ischemia.

After revascularization the acinus mean diameter of the parotid salivary glands on the test side was 11.5 microns with the mean value standard error 0.17 microns and on the control side 11.4 microns with the mean value standard error 0.27 microns. The control and test groups after revascularization did not statistically differ because $p = 0.678$ (Picture 10).



Picture 10. Acinus mean diameter of salivary glands 28 days after revascularization.

2.3.1.3. In submandibular salivary glands

Mean diameter of submandibular salivary gland acinary epithelium cells on the test side after 28-day-long ischemia was 4.7 microns with the mean value standard error 0.15 microns, but on the control side 5.2 microns with the mean value standard error 0.13 microns. Comparing the mean diameter of acinus epithelium of the control and test side

submandibular salivary glands by the pair test, we acquired on average 0.57 micron difference, which is statistically significant $t=2.24$ and $p<0.052$ (Picture 7).

After revascularization acinus epithelium cell diameter of submandibular salivary glands on the test side was on average 5.5 microns with the mean value standard error 0.1 micron, but on the control side 4.9 microns with the mean value standard error 0.18 microns. Thus, the diameter of acinary epithelium of revascularized side submandibular salivary glands is on average by 0.6 microns bigger than on the control side. Processing the results by the pair test and comparing the control and test side groups after revascularization, we acquired t value 2.7 and p value 0.024. There is a statistically significant difference between the control and test groups (Picture 8).

Submandibular salivary gland acinus mean diameter after ischemia on the test side was 11.1 microns with the mean value standard error 0.31 microns, but on the control side on average 11.8 microns with the mean value standard error 0.29 microns. Comparing these values, there was acquired a statistically significant $p<0,045$ and the test group difference on average by 0.7 microns (Picture 9).

After revascularization the acinus mean diameter of submaxillary salivary glands on the test side and the control side was 14 microns with the mean value standard error 0.23 microns. The control and test groups after revascularization statistically did not differ because $p=0.8$ (Picture 10).

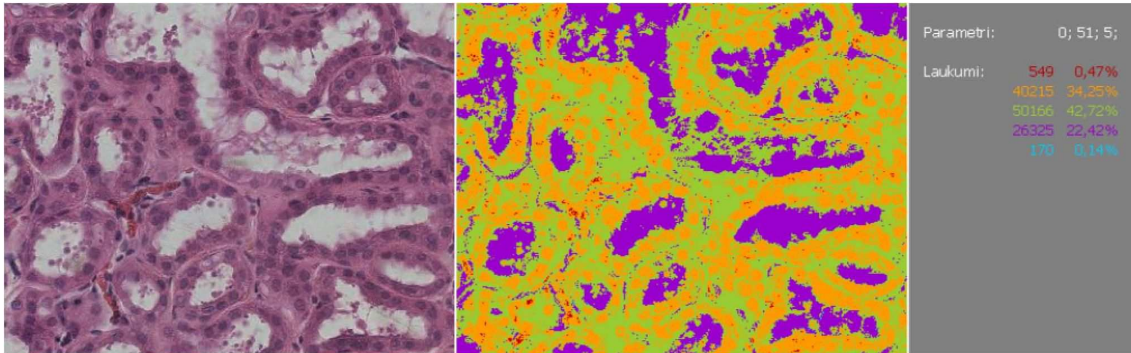
Morphometrically in ischemia one can see the decrease of the acinus in the salivary glands and acinus epithelium cell diameter ($p<0.001$) in ligature side. Acinus epithelium cells after revascularization are similar to the control and test sides and in separate cases become bigger than on the control side ($p<0.05$). Acinus diameter after revascularization becomes similar to the control side. These changes prove the regeneratory ability of salivary glands of rabbits to preserve after the restoration of blood flow.

2.3.2. Stromal and parenchymal fields and their relationship 28 days after ischemia and 28 days after revascularization.

Processing the digital morphological pictures of salivary glands by optic density isoline method, and by doing the structure analysis of pictures, there was acquired the picture of salivary gland stromal and parenchymal structure, expressed in percentile from the common picture field.

2.3.2.1. In buccal salivary glands

The increase of buccal salivary gland stroma was seen in all test samples after 28-day-long ischemia (Picture 11). Parenchymal field in part of samples decreased and in another part of samples it remained unchanged.



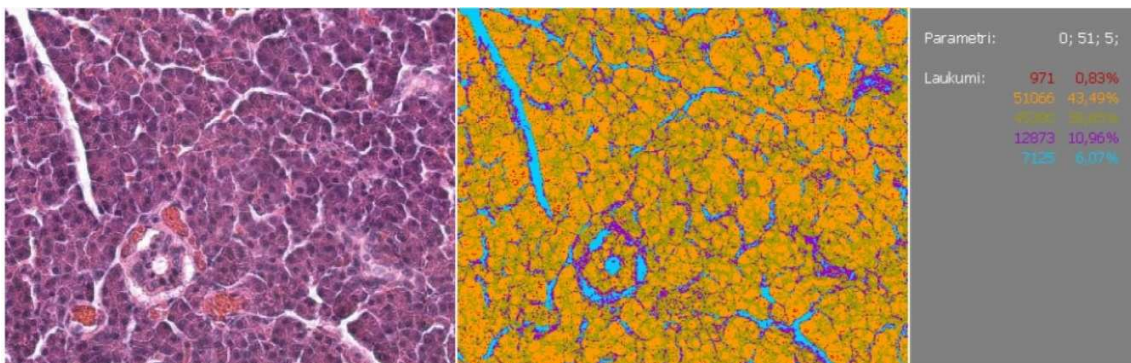
Picture 11. Microphotogram of buccal salivary gland after processing with optic density isoline method.

Relationship of parenchyme and stroma, comparing to the control side glands, decreased on average by 0.07 with the standard deviation 0.008. The difference acquired is statistically significant because t value 27.1 and $p < 0.001$. The acquired data closely correlate because $n = 0.97$. with the rise of control indices by one unit, the test indicator increases by 0.924 units. Thus, the test values are increasing slower in comparison to the control values.

After revascularization one could observed parenchymal field increase of salivary glands on the test side in comparison to the control side. No stromal differences were observed. Parenchymal and stromal relationship, comparing to the ischemic samples, changed on average by 0.03 with standard deviation 0.012. The acquired data closely correlated ($n = 0.97$) with the statistic significance $p < 0.001$

2.3.2.2. In parotid salivary glands

Stromal increase in parotid salivary glands was seen in all test side samples after 28-day-long ischemia. Parenchymal field in all samples decreased (Picture 12).



Picture 12. Microphotogram of parotid salivary gland after processing with optic density isoline method.

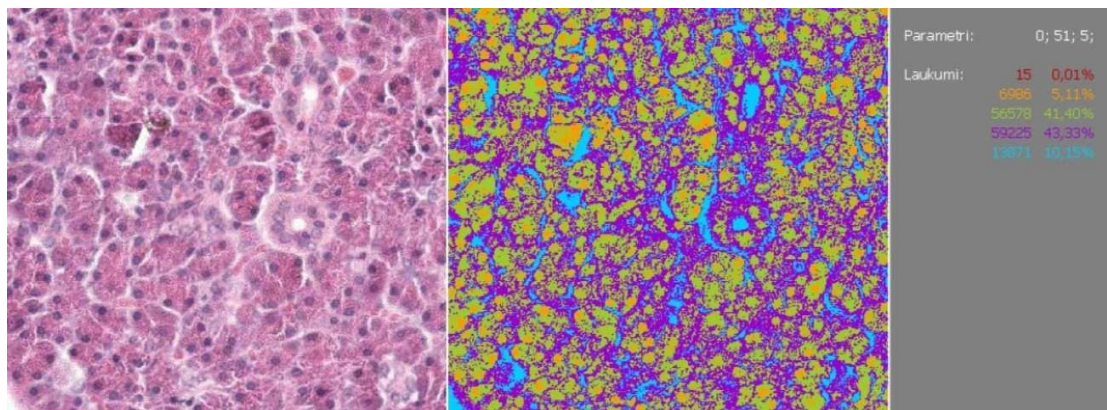
After ischemia the relationship of parenchyme and stroma, in comparison to the control side glands, decreased on average by 0.07 with standard deviation 0.008. The

acquired difference is statistically significant because t value 17.7 and $p < 0.001$. The data closely correlate ($n=0.87$).

After revascularization the stromal field decreased, while parenchymal field increased. The relationship of parenchyme and stroma, in comparison to the control side decreased by 0.03 with standard deviation 0.01. The statistic significance of the acquired data is $t = 9.0$ and $p < 0.001$

2.3.2.3. In submandibular salivary glands

Stromal increase in submandibular salivary glands was seen also in all test side samples after ischemia. Parenchymal field in most of samples decreased (Picture 13).



Picture 13. Microphotogram of submandibular salivary gland after processing with optic density isoline method.

The relationship of parenchyme and stroma of the test side after ischemia, in comparison to the control side salivary glands, decreased on average by 0.075 with standard deviation 0.017. The acquired difference is statistically significant t value 9.85 and $p < 0.001$. The data closely correlate because $n=0.94$.

After revascularization the stromal field decreased, while parenchymal field increased. The relationship of parenchyme and stroma, in comparison to the control side, decreased by 0.031 with standard deviation 0.009. The statistical difference of the acquired data is $t = 9.0$ and $p < 0.001$

2.4. Expression of growth factor and growth factor receptors in salivary glands

2.4.1. Expression of growth factor and growth factor receptors in salivary glands 28 days after ischemia

28 days after fastening of unilateral a.carotis communis, one could see on the test side and control side samples a lot of NGFR1 positive structures in the visual field. On the other hand, expression of nerve growth factor (NGF) was from few to moderately many positive structures in the visual field (+/++). In the salivary glands of the control side there was seen a more pronounced NGF and NGFR1 expression in comparison to the salivary glands in the test side. NGF was more prevalent in the interstitial connective tissue cell cytoplasm of salivary glands, in some myoepithelial cells, arteriole and venule walls, hyperplazed acinus

epithelial cells. NGFR1 was found in the connective tissue cell cytoplasm, connective tissue fibres around the salivary gland duct and blood vessels, in separate ductal epithelial cells and acinus epithelium cells and myoepithelial cells. NGFR1 expression is seen in atrophic acinus epithelium cells and hyperplazed acinus cells. Expression is not seen in the unchanged epithelium cells. Positive NGFR1 expression is seen also in the apical part of microcilia of acinus epithelium cells and secretion granules. By treating the acquired data with the cross-table method and checking the statistical significance p value by Chi square test, p value 0.185 was obtained in ischemic rabbit group, comparing the control and test sides. NGF expression in the control and test groups do not have statistically significant difference. NGFR1 expression data processed by cross-table method and Chi square test, showed that p value in the test group was 0.739. NGFR1 in the test and control groups do not have statistically significant difference (Table 3). Comparing NGF and NGFR1 correlation by Pearson correlation, we acquired the following results: NGF expression on the test side samples mutually correlates with NGFR1 expression in the test samples $n=0.639$ with statistical significance $p = 0.01$. NGFR1 expression in the test side samples mutually correlates with NGFR1 expression in the control side samples ($n=0.435$) with statistical significance $p = 0.05$

Fibroblast growth factor (FGF) and fibroblast growth factor receptor (FGFR1) in salivary glands in ischemia are expressed in about the same amount. Positive expression is seen in connective tissue cytoplasm around ducts and blood vessels, acinus and ductal epithelium cell cytoplasm, in smooth muscle cells of arterioles, in acinus cell nuclei and cytoplasm. FGF and FGFR1 expression was moderate up to pronounced both in parenchymal structures, and in stromal structures (Table 3). Acquired FGF data, processed by cross-table method and Chi square test, comparing the control and test groups, showed that p value was 0.005, thus, there does not exist any statistically significant difference between these groups. Comparing FGFR1 test group data to the control group data, p value was 0.002, thus, FGFR1 expression in the control and test groups is statistically significant. FGFR1 in the control group and test group mutually correlates ($n = 0.685$). FGF mutually correlates with NGF ($n = 0.454$) and FGFR1 mutually correlates also with NGF ($n = 0.362$). Statistical significance of these correlations is $p = 0.05$.

Vascular endothelial growth factor (VEGF) in rabbits' salivary glands was rarely (0/+) found in the gland parenchyme, and moderately much (++) of its positive structure was found only in the submandibular salivary gland parenchyme on the test side (Table 3). Expression in the blood vessel walls was more pronounced and ranged from moderate amount of positive structures up to quite a rich expression. In the blood vessels of parotid salivary glands and ductal cells, there was rich positive VEGF expression both on the test and control sides. In stromal elements the positive expression was seen in glandular blood vessels, venule and arteriole walls. Expression of stromal elements in the parotid salivary gland was similar both in the test and control side. Most intensively the expression was seen in stromal elements in the submandibular salivary gland where on the test side was seen to be a more intensive expression in comparison to the control side. Stromal elements in the buccal salivary glands showed a slight amount of positive structures both in the glands of ischemia side, and in the control side. The acquired data were processed by cross-table method and Chi square test, obtaining p value 0.001, thus, between the control and test side salivary

glands there exists statistically significant difference. VEGF control and test data mutually correlate ($n=0.421$) with p value 0.05.

Expression of epidermal growth factor receptor (EGFR) was seen in the parotid salivary gland on the test side and buccal salivary glands on the test side, and slightly on the control side. Expression was not found in submandibular salivary gland EGFR. In stromal structures of the parotid salivary glands there were seen more pronounced expressions of this factor than in parenchymal structures. But in the ischemia side of the buccal salivary glands, the expression was seen to be more in the apical part membrane of acinus epithelium cells, and in secretion granules. On the control side salivary glands, EGFR expression was seen like rare single positive structures. Processing the acquired data by Chi square test, there was obtained p value 0.01. EGFR expression between the test and control groups in the parotid and buccal salivary glands had statistically significant difference. EGFR expression mutually correlated on the control and test side glands ($n=0.535$), as well as there existed a correlation between EGFR expression on the test side salivary glands and NGFR control side salivary gland expression ($n=0.435$) with p value 0.05.

Expression of inflammatory markers of tumour necrosis factor alfa (TNF α) and interleukin 10 (IL-10) was found in neither of ischemic glands (Table 3).

Table 3. Expression of growth factor and their receptors, inflammatory markers in rabbit's salivary glands after ischemia

FACTOR	Parotid salivary gland		Submandibular salivary gland		Buccal salivary gland	
	Test	Control	Test	Control	Test	Control
NGF parenchyme	+	+ / ++	+	+ / ++	+	+
NGF stroma	++	++ / +++	++	+++	++	++ / +++ +
NGFR parenchyme	+ / ++	++	++	++	+ / ++	++
NGFR stroma	++ / +++	+++	++	+++	++	++
FGF parenchyme	++	++	0 / +	+ / ++	+	++
FGF stroma	+ / ++	++	++	+++	++	++ / +++ +
FGFR parenchyme	++	+++	+	++	++	++
FGFR stroma	++ / +++	+++	++	++ / +++	++	++ / +++ +
VEGF parenchyme	+	+	++	+	+	+
VEGF stroma	++	++	++ / +++	+ / ++	+	+ / ++
EGFR parenchyme	+	0	0	0	++	+
EGFR stroma	++	0	0	0	+	0

TNFα parenchyme	0	0	0	0	0	0
TNFα stroma	0	0	0	0	0	0
IL10 parenchyme	0	0	0	0	0	0
IL10 stroma	0	0	0	0	0	0

2.4.2. Expression of growth factor and growth factor receptors in salivary glands 28 days after revascularization

Expression of the growth factors in the salivary glands 28 days after revascularization was less pronounced comparing it to the ischemic group. All of the surveyed growth factors are expressed more markedly in salivary glands of the control side, comparing it to the test side (Table 4).

NGF in the parotid salivary gland after revascularization was seen in separate structure expressions on the control side, on the test side the expression was not observed. NGFR expression in the parenchyme of the parotid salivary gland is seen both on the test side glands, and in separate structures on the control side. In the parenchyme of the submandibular salivary gland NGF expression was seen also on both sides with a more pronounced expression in the control side glands. NGFR expression in the parenchyme of the submandibular salivary glands is also more pronounced on the control side. In the parenchyme of the buccal salivary gland on the test side no NGF expression is found, but in the parenchyme of the control side salivary gland there is observed a little amount of positive structure. In the parenchyme of all revascularized salivary gland cells, which showed positive expression, there were hyperplazed acinus epithelium cells, separate duct epithelium cells and separate myoepithelial cells. NGF expression was seen in the parotid salivary gland stroma on the test and control sides. On the control side the expression was more pronounced, comparing to the test side where rare positive structures were observed. NGFR expression in the parotid salivary gland stroma was seen on both sides in moderately many structures. In the submandibular salivary gland stroma, NGF expression was seen on both sides and was more intensive on the control side, where were found moderately many positive structures. NGFR expression was seen in the submandibular salivary gland stroma in moderately many structures. In the buccal salivary stroma one could see a little amount of positive structures, in which equal data were shown by NGF and its receptor NGFR. The chief stromal cells, which showed positive expression, were the connective tissue cells around the salivary gland ducts and blood vessels. No statistically significant difference for NGF and NGFR expression between the control and test groups was seen. Processing the results by Chi square test, there were acquired NGF $p=0.435$ and NGFR $p=0.739$. NGF indices mutually correlate with NGFR indices ($n=0.639$) with statistical significance $p<0.01$.

FGF expression in the parotid salivary gland after revascularization was observed in glands of both sides. In the control group glands the expression was preserved in about the same amount of structures than after ligation, while the number of positive structures in the salivary glands of the test side decreased. Parenchymal structures of the parotid salivary glands, which demonstrated a positive FGF expression, had the duct and acinus duct epithelial cell cytoplasm and separate myoepithelial cells. FGFR expression in the parotid salivary glands is seen to be in a little amount to a moderately great amount both in

parenchymal and stromal structures. A slightly greater expression was seen on the control side. In parenchymal structures FGFR expression was less intensive in comparison to FGF expression. In stroma the parotid salivary glands were seen to have moderately many FGF positive structures and, in the same way as in parenchyme, on the control side one could see a more pronounced expression, comparing it to the test side. Structures which demonstrated positive expression in stroma or the parotid salivary glands, were connective tissue cell cytoplasm around glandular ducts and blood vessels and cells of arterioles and smooth muscles. The difference of the structure of the submandibular salivary gland parenchyme on the test and control sides were with very rare FGF positive structures up to moderately many positive structures. On the control side the submandibular salivary gland parenchyme showed a more intensive expression. Structures which showed positive expression had in the submandibular salivary gland parenchyme the acinus and epithelial duct cell cytoplasm. Expression in the parenchyme was of concentration-type. FGFR expression in the submandibular salivary gland parenchyme was also poorer than FGF expression. FGFR expression was seen in acinus and epithelial duct cells. In stromal elements in the submandibular gland, we could see an equal number – moderately many either FGF or FGFR positive structures of connective tissue cells around the salivary gland ducts and blood vessels. In the buccal salivary gland parenchyme FGF expression on the control side was more pronounced, where one could observe moderately many positive structures, concentration of acinus in epithelial cells and in separate myoepithelial cells. On the test side in the parenchyme of the buccal salivary gland there was seen only a little number of FGF positive structures. FGF expression in the stroma of the buccal salivary gland was seen to have a similar tendency, since expression was stronger in the control side, comparing it to the test side. Expression in the stroma was observed in little amount in the connective tissue cells around the ducts. FGFR expression in the parenchyme and stroma of the buccal salivary glands had little to moderately great number of positive structures. On the control side the expression was more pronounced. When processing the data with Chi square test, there was no statistically significant difference between the test and control side data ($p=0.467$). FGF and FGFR mutually correlated ($n=0.685$) with statistical significance $p<0.05$ and FGF correlated also with NGF ($n=0.484$) with statistical significance $p<0.05$.

VEGF expression in the rabbits' salivary glands after revascularization was seen as rare structures in the glandular parenchyme, and moderate amount of positive structures were revealed only in the submandibular salivary gland parenchyme on the test side (Table 4). In the stromal elements one could see a more pronounced expression and it ranged from moderate number of positive structures to even a very rich amount, in the same way as in the glands after ischemia. Parenchymal elements, in which one could see VEGF expression, were acinus epithelial cell cytoplasm and rare epithelial duct cells. A more intensive positive expression was seen in the control side glands. In stromal elements the positive expression was seen in the walls of small blood vessels. Most intensively there were expressed the stromal elements on the control side in the parotid salivary glands and parenchymal and stromal elements of submandibular salivary glands of the test side, where one could see a moderate amount of positive structures. Stromal and parenchymal elements in the buccal salivary glands showed a little amount of positive structures both on the test and control sides. Processing the acquired data by the cross-table method and Chi square test, we acquired p value 0.05, thus, there exists a statistically significant difference of VEGF

expression between the control and test side salivary glands. VEGF control and test data mutually correlate ($n=0.485$) with p value 0.05.

Expression of epidermal growth factor (EGFR) in salivary glands after revascularization was seen in the parotid and buccal salivary glands. In the submandibular salivary glands EGFR expression was not observed. In the parotid salivary glands EGFR separate parenchyme and stromal structure expressions were seen only on the test side salivary glands. In the buccal salivary glands EGFR expression was seen in separate stromal elements on the test side salivary glands (Picture 36 in the appendix). On the control side of the buccal salivary glands EGFR expression was not observed. For EGFR expression there was not observed a statistically significant difference between the revascularized salivary glands and the control side salivary glands $p = 0.33$. Correlation for the control and test side data was poor.

Expression of inflammatory markers' tumour necrosis factor alfa (TNF α) and interleukin 10 (IL-10) was not observed in either of revascularized salivary, or ischemic glands (Table 4).

Table 4. Growth factors and their receptors, inflammatory marker expression in rabbit's salivary glands after revascularization

FACTOR	Parotid salivary gland		Submandibular salivary gland		Buccal salivary gland	
	Test	Control	Test	Control	Test	Control
NGF parenchyme	0	0/+	+	+ /+++	0	+
NGF stroma	+	+ /+++	+	++	+	+ /+++
NGFR parenchyme	+	0/+	+	+	0/+	+
NGFR stroma	+ /+++	++	+	++	+	+
FGF parenchyme	+	++	0/+	+ /+++	+	++
FGF stroma	+ /+++	++	++	++	++	+ /+++
FGFR parenchyme	+	++	+	++	+	++
FGFR stroma	+ /+++	++	++	+ /+++	+	+ /+++
VEGF parenchyme	+	+	++	+	+	+
VEGF stroma	+	++	+ /+++	0/+	+	+
EGFR parenchyme	+	0	0	0	0	0
EGFR stroma	+	0	0	0	+	0
TNF α parenchyme	0	0	0	0	0	0

TNFα stroma	0	0	0	0	0	0
IL10 parenchyme	0	0	0	0	0	0
IL10 stroma	0	0	0	0	0	0

2.5. Apoptosis in salivary glands 28 days after ischemia and 28 days after revascularization

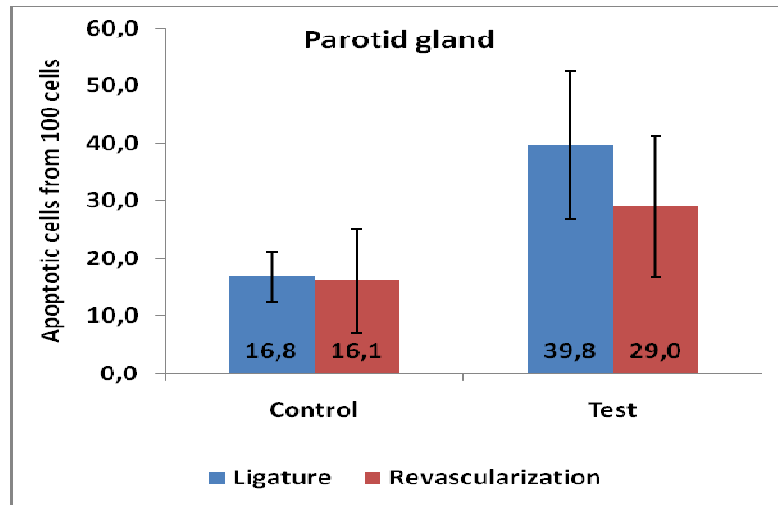
Comparing the control and test side under the light microscope, in the parotid salivary gland acinus cells one could find vacuoles, interstitially there was a higher connective tissue amount, lymphocyte infiltration and increased fat cell amount. Changes in acinus cells of submandibular salivary glands are less pronounced. In the buccal salivary gland on the test side, one could observe proliferation and degeneration of secretory parts. In the excretory parts of submandibular and parotid salivary glands, one could see epithelial proliferation and interstitial fibrosis.

Four weeks after experimental ischemia in the major salivary glands, there was seen the concentrations of apoptosis regions, where healthy tissues mix with marked apoptosis regions, in the nuclei there was seen chromatine margination. Concentration of apoptosis can be found both in the glandular ducts, and in glandulocytes. Mean number of apoptosis affected cells from 100 cells in the visual field in the salivary glands after ischemia is shown in Table 5.

Table 5. Apoptotic cell number from 100 cells in the visual field in major salivary glands 28 days after ischemia and 28 days after revascularization.

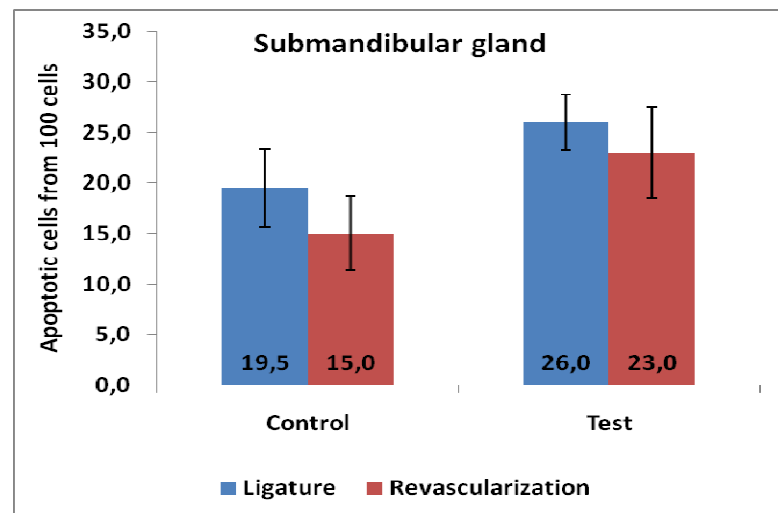
	Positive cells from 100 cells (apoptotic index)			
	28 days ligated		28 days revascularized	
	Test	Control	Test	Control
Parotid salivary gland	39.8(0.40)	16.8(0.17)	29(0.29)	16.1(0.16)
Submandibular salivary gland	26(0.26)	19.5(0.20)	23(0.23)	15(0.15)
Buccal salivary gland	18.4(0.18)	11.4(0.11)	16.9(0.17)	11.7(0.12)

Apoptosis in the parotid salivary glands after ischemia is seen on the test side with on average 39.8 cells from 100 cells with $SD\pm 12.9$, on the control side on average 16.8 cells from 100 cells with $SD\pm 4.4$. After revascularization in the salivary glands on the test side apoptosis was on average 29 cells from 100 cells with $SD\pm 12.2$, in the control side 16.1 cells from 100 cells with $SD\pm 9$. After revascularization there was seen the decrease of apoptosis in the parotid salivary glands, but on the control side salivary glands changes were not seen (Picture 14). Processing the acquired data with the pair test t value was 7.7 after ischemia and 4.1 after revascularization. There exists statistic significance between these data $p < 0.005$.



Picture 14. Number of apoptotic cells from 100 cells in the visual field in the parotid salivary glands after ischemia and after revascularization

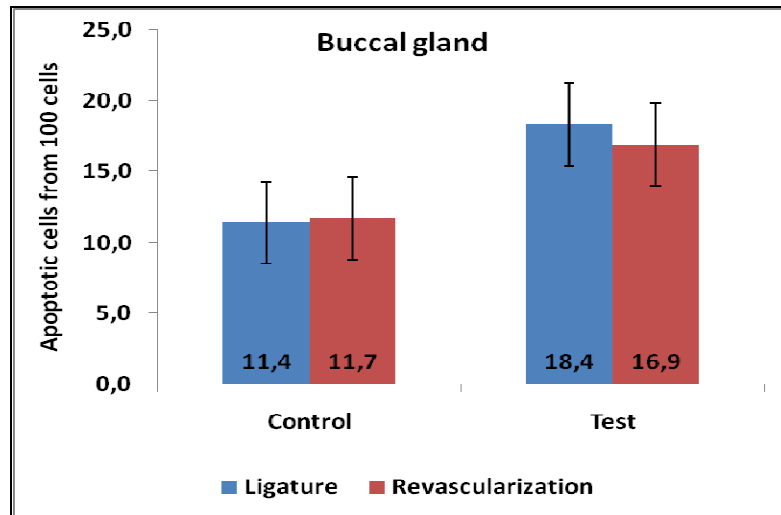
In the submandibular salivary glands after ischemia was seen apoptosis in the test side on average 26 cells from 100 cells with $SD \pm 2.7$, in the control side on average 19.5 cells from 100 cells with $SD \pm 3.9$. After revascularization in the submandibular salivary glands on the test side apoptosis was on average 23 cells from 100 cells with $SD \pm 4.5$, on the control side 15 cells from 100 cells with $SD \pm 3.7$. After revascularization there was seen apoptosis decrease in the test side submandibular salivary glands on average by 3 apoptotic cells but on the control side there were seen changes in the salivary glands on average by 4.5 apoptotic cells (Picture 15). Processing the acquired data by the pair test, t value was 8,73 after ischemia and 5.85 after revascularization. There exists statistic significance between these data $p < 0.001$.



Picture 15. Number of apoptotic cells from 100 cells in the visual field in submandibular salivary glands after ischemia and after revascularization

In the buccal salivary glands after ischemia there was seen apoptosis on the test side on average 18.4 cells from 100 cells with $SD \pm 2.7$, on the control side on average 11.4 cells

from 100 cells with $SD\pm 2.7$. After revascularization in the buccal salivary glands on the test side apoptosis was on average 16.9 cells from 100 cells with $SD\pm 4.4$, in the control side 11.7 cells from 100 cells with $SD\pm 3.8$. After revascularization there was seen apoptosis decrease on the test side buccal salivary glands, but on the control side no changes were seen in salivary glands (Picture 16). Processing the acquired data by the pair test, t value was 9.43 after ischemia and 7.71 after revascularization. There exists statistical significance between these data $p < 0.001$.



Picture 16. Number of apoptotic cells from 100 cells in the visual field in the buccal salivary glands after ischemia and after revascularization

Marked apoptosis (apoptotic index 0.40) is seen in the parotid salivary glands after ischemia, which decreases after revascularization (0.29). Lesser apoptotic activity (0.26) is in the submandibular salivary glands, which also decreases after revascularization (0.23). In the buccal salivary glands after ischemia apoptosis is the least (0.18) and after revascularization slightly decreases (0.16) ($p < 0.005$).

3. Conclusions

1. Ligature and revascularization of a. carotis communis of rabbits, together with histomorphologic and scintigraphic examination is an adequate experimental surgery model for studying angiogenous salivary gland pathology.
2. Radioscintigraphically determined functional activity changes of major salivary glands after a. carotis communis ligature show statistically significant decrease of Tc^{99} uptake, comparing to the control side glands ($p < 0.001$). After reconstruction of the ligated artery on the test side salivary glands, one can observe the improvement of salivary gland function, but during the observation it does not reach the functional activity of the healthy side salivary glands.
3. Histomorphologically in the rabbits' ligature side of the major salivary glands one can observe glandular parenchyme atrophy and stromal hyperplasia with lipmatosis, on the control side salivary glands one can observe the compensators' parenchyme hyperplasia. After revascularization the test side salivary glands show atrophic parenchyme

concentrations, hyperplazed regions and moderate parenchymal hyperplasia of the opposite side. Hyperplasia can be like a compensator's response to ischemia and indicates to a preserved glandular regenerating ability.

4. Morphometrically in ischemia the salivary glands are seen to have the decrease of the diameter of acinus and acinus epithelium cells ($p < 0.001$) in the ligature side. Acinus cells after revascularization are similar to the control and test sides and in some cases become bigger than in the control side ($p < 0.05$). Acinus diameter after revascularization becomes equal to that of the control side. Thses changes give proof for the rabbit's salivary gland regenerating ability to preserve after restoration of blood circulation.
5. Morphometrically the parenchyme, in reference to stroma in all salivary glands after ischemia decreases ($p < 0.001$), but after revascularization there occurs a reversable process.
6. Pronounced apoptosis (apoptotic index 0.40) is in the parotid salivary glands after ischemia, which decreases after revascularization (0.29). A lesser apoptotic activity (0.26) is seen in the submandibular salivary glands, which also decreases after revascularization (0.23). In the buccal salivary glands after ischemia the apoptosis is the least (0.18) and after revascularization slightly decreases (0.16). Thus, ischemia causes salivary gland cellular apoptosis, which decreases by restoration of blood circulation ($p < 0.005$).
7. Lack of expression of inflammatory cytokin – TNF α and IL-10 in the salivary glands indicates to significant changes due to cell degradation and inflammation in the salivary glands after a.carotis communis ligature.
8. Expression of the growth factors and their receptors in ischemic salivary glands is less expressed in the control side glands, which, possibly, can be explained by a more pronounced blood flow, thus providing the stimulation of the growth factor output in the control side salivary glands.
9. NGF expression in all salivary glands is equal and decreases after revascularization and does not change under the influence of perfusion. NGFR expression is markedly pronounced in the parotid salivary gland and moderately pronounced in the buccal glands, after revascularization the intensity of its expression does not decrease. However, in a longer period of time after reperfusion, there occurs the wearing out of the nerve stimulating factors, which is characterized by the decrease of NGFR expression.
10. FGF expression, in comparison to FGFR expression, is less pronounced and dominates in the submandibular and buccal salivary glands in the control side. In total, FGF and FGFR expression after revascularization decreases, giving proof to the decrease of compensatory regeneration.
11. Pronounced VEGF expression in the ischemic submandibular salivary glands gives prrof to a significant circulatory effect on the salivary glands. After revascularization VEGF expression (ischemia) decreases, but is preserved more markedly in the submandibular salivary gland.
12. EGFR is not found in the submandibular salivary glands but in parotid and buccal glands in the test side after ischemia and less found after revascularization. These diferences, probably, are connected with histomorphology of various salivary glands and various specificities of glandular blood circulation.

Reports delivered at conferences, theses and publications on the topic.

Reports at conferences:

2004. g. RSU Medicīnas nozares zinātniskā konference „Siekalu dziedzeru izmaiņas pēc miega artērijas ligatūras eksperimentā”

Latvijas ārstu kongress 2005 „Siekalu dziedzeru išēmija eksperimentā”

2006. g. RSU zinātniskā konference „Siekalu dziedzeru funkcionālās izmaiņas pēc eksperimentālas išēmijas”

XVIII Congress of the European Association for Cranio-Maxillofacial Surgery Barcelona, Spānija 2006 „Functional activity, growth factors and apoptosis in salivary glands after reduced circulation”

1st Baltic Scientific Conference of Dentistry, Pērnavā, Igaunija 2006 „Morphofunctional evaluation of salivary glands after reduction of arterial blood supply in experiment”

2nd Baltic Scientific Conference of Dentistry, Rīga 2007 „Evaluation of salivary gland functions after ischemia and revascularization in experimental model of rabbit”

2007. g. RSU zinātniskā konference „Augšanas faktori un apoptoze siekalu dziedzeros eksperimentāliem dzīvniekiem pēc *a.carotis communis* liģēšanas”

2008. g. RSU zinātniskā konference „Augšanas faktori un apoptoze siekalu dziedzeros eksperimentāliem dzīvniekiem pēc *a.carotis communis* liģēšanas un revaskularizācijas”

6th Congress of Baltic Association for Maxillofacial and Plastic Surgery Tallinn, Estonia 2008 „Functional activity of rabbits salivary glands in regional ischemia and revascularisation”

XIX Congress of the European Association for Cranio-Maxillofacial Surgery, Bologna, Italy 2008 “Functional activity of rabbit salivary glands in experiment”

2009. g. RSU zinātniskā konference „Siekalu dziedzeru patoloģija eksperimentā pēc *a.carotis communis* liģēšanas un revaskularizēšanas”

2010. g. RSU zinātniskā konference „Trušu siekalu dziedzeru morfometrija pēc *a.carotis communis* liģēšanas un revaskularizēšanas”

Scandinavian congress of oral and maxillofacial surgery, Norway, Oslo 2010 „Morphometry of rabbits salivary glands in regional ischemia and revascularization”

Theses:

„Siekalu dziedzeru izmaiņas pēc miega artērijas ligatūras eksperimentā” 2004. g. 5., 18. martā Tēzes RSU Medicīnas nozares zinātniskā konference (145)

„Siekalu dziedzeru išēmija eksperimentā” Latvijas ārstu kongresa tēzes 2005.g.16.-18.jūnijs (41)

„Siekalu dziedzeru funkcionālās izmaiņas pēc eksperimentālas išēmijas” Tēzes RSU zinātniskajai konferencei 2006. gada 3.marts (52)

„Morphofunctional evaluation of salivary glands after reduction of arterial blood supply in experiment” Stomatologija 2006 suppl 3 (17-18)

„Functional activity, growth factors and apoptosis in salivary glands after reduced circulation” Journal of Craniomaxillofacial Surgery 34(2006) suppl 1 (200)

„Augšanas faktori un apoptoze siekalu dziedzeros eksperimentāliem dzīvniekiem pēc *a.carotis communis* liģēšanas” Tēzes RSU zinātniskajai konferencei 2007. marts (220)

„Evaluation of salivary glands functions after ischemia and revascularization in experimental model of rabbit” Stomatologija 2007 Suppl 1/4 (37)

„Augšanas faktori un apoptoze siekalu dziedzeros eksperimentāliem dzīvniekiem pēc *a.carotis communis* liģēšanas un revaskularizācijas” Tēzes RSU zinātniskajai konferencei 2008. marts(183)

„Functional activity of rabbits salivary glands in regional ischemia and revascularisation”. Tēzes. 6th Congress of Baltic Association for Maxillofacial and Plastic Surgery, 15-17 May, 2008 Tallinn, Estonia

Functional activity of rabbit salivary glands in experiment. Journal of Craniomaxillofacial Surgery 36 2008 suppl 1 (257)

Vascular endothelial growth factor (VEGF) in salivary glands after ligation and revascularization of a.carotis communis in experiment. Tēzes Stomatologija, Baltic Dental and Maxillofacial Journal 2008 Suppl 5 (15-16)

„Siekalu dziedzeru patoloģija eksperimentā pēc a.carotis communis ligēšanas un revaskularizēšanas” Tēzes RSU zinātniskajai konferencei 2009. gada 2.-3.aprīlis (207)

„Trušu siekalu dziedzeru morfometrija pēc a.carotis communis ligēšanas un revaskularizēšanas” Tēzes RSU zinātniskajai konferencei 2010. gada 18.-19.marts (304)

„Morphometry of rabbits salivary glands in regional ischemia and revascularization” Scandinavian congress of oral and maxillofacial surgery, 2010. gada 6.-8.maijs Oslo, Norvēģija (45)

Publications:

„Trušu trigeminālo gangliju morfoloģija pēc vienpusējas ilgstošas *a.carotis communis* nosiešanas” 2004.g. RSU Zinātniskie raksti (166-168)

„An Immunohistochemical study of the presence of nerve growth factor p75 receptor in the human salivary gland vasculature in case of sialolithiasis” Eesti Arst, Lisa 6, 2005 (38-41)

„Scintigraphy of salivary glands after ligation of common carotid artery in experiment” Acta Chirurgica Latviensis 2006/6 (46-49)

„Apoptoze truša siekalu dziedzeros samazinātas reģionālās asinsapgādes apstākļos”, Rīgas Stradiņa Universitātes Zinātniskie Raksti 2007, (320-323)

„Histomorphology of salivary glands after ligation and reconstruction of common carotid artery in rabbits” Acta Chirurgica Latviensis 2009/9 (45-49)

„Functional activity of rabbit salivary glands in reduced and restored regional arterial blood supply conditions” Stomatologija, Baltic Dent and Maxillofacial Journal, 2010/12 (28-32)

Acknowledgements

I express my greatest appreciation to professor Mara Pilmane, research supervisor, for constructive advice, great patience and support.

I express my thanks to professor Andrejs Skaģers, research supervisor, for advice and support.

My greatest thanks to the staff of the Institute of Anatomy and Anthropology for support in realization of research work.

I want to thank Maija Ratniece for support in doing scintigraphic examinations.

I thank Kalvis Pastars and Nonna Tomiševa for invaluable support during microsurgical operations.

Great thanks to professor Laila Feldmane for advice in writing the promotion work and support in acquiring the morphometric data.

My thanks to Juris Priednieks, who helped in processing the microphotographs by means of graphical optic density isoline method.

I want to thank professor Uldis Teibe for advice in doing statistical data processing.

My special thanks to my family for patience and moral support.