

Dzintars Ozols

COMPLEX POSTOPERATIVE RESULT
EVALUATION OF CONGENITAL THUMB
HYPOPLASIA FOR THE NEW THUMB
RECONSTRUCTIVE METHOD'S
SUBSTANTIATION

Summary of the Doctoral Thesis
for obtaining the degree of a Doctor of Medicine

Specialty – Paediatric Surgery, Hand Surgery and
Plastic Surgery

Riga, 2019

The Doctoral Thesis was carried out at Riga Eastern University Hospital and Children's Clinical University Hospital in collaboration with Microsurgery Centre of Latvia.

Scientific supervisor:

Dr. habil. med., Professor **Aigars Pētersons**,
Rīga Stradiņš University, Latvia

Official reviewers:

Dr. med., Associate Professor **Pēteris Studers**,
Rīga Stradiņš University,
Joint Laboratory of Traumatology and Orthopaedics, Latvia

Dr. med., Professor **Konstantīns Kalnbērzs**,
Medical Faculty of University of Latvia

Dr. med., **Jarkko Jokihaara**,
Tampere University Hospital (TAUH), Department of Hand Surgery,
Finland

Defence of the Doctoral Thesis will take place at the public session of the Doctoral Council of Medicine on 10 December 2019 at 15.00 in Hippocrates Lecture Theatre, 16 Dzirciema Street, Rīga Stradiņš University.

The Doctoral Thesis is available in the RSU library and at RSU webpage:
www.rsu.lv.

Secretary of the Doctoral Council:

Dr. med., Associate Professor **Zane Ābola**

TABLE OF CONTENTS

ABBREVIATIONS	4
INTRODUCTION.....	5
STUDY OBJECTIVES	5
AIM OF THIS STUDY	7
RESEARCH TASKS.....	7
SCIENTIFIC HYPOTHESES	8
PLACE OF WORK.....	8
SCIENTIFIC NOVELTY	8
PRACTICAL VALUE OF THIS RESEARCH	9
RESEARCH DESIGN AND CAPACITY	9
PUBLICATIONS ABOUT THE THESIS TOPIC.....	9
PATENTS.....	9
MEDICAL TECHNOLOGY	9
CLINICAL GUIDELINES	10
1. NEW SURGICAL METHOD	11
1.1 <i>EIP</i> TRANSPOSITION METHOD.....	11
1.2 THE NEW TOE-TO-HAND TRANSPLANTATION METHOD	11
2. RESEARCH/STUDY SECTION.....	18
2.1 RETROSPECTIVE SECTION	18
2.2 PROSPECTIVE SECTION	19
2.3 RESEARCH METHODS	20
2.4 INCLUSION AND EXCLUSION CRITERIA	22
2.5 STATISTICAL METHODS USED	23
2.6 ETHICAL ASPECTS.....	24
3. RESULTS	25
3.1 PATIENTS TREATED WITH THE TRANSPOSITION METHOD (N=14).....	25
3.2 PATIENTS TREATED WITH THE <i>NEW</i> METHOD (N=2)	35
3.3 PATIENTS TREATED WITH POLLICIZATION METHOD (N=2).....	39
3.4 RETROSPECTIVE ANALYSIS RESULTS	41
3.5 PROSPECTIVE RESEARCH PART	42
3.6 QUESTIONNAIRE AESTHETIC RESULTS	47
DISCUSSION	49
CONCLUSIONS	55
PUBLICATIONS AND REPORTS ON THE RESEARCH TOPIC.....	56
REFERNCES	62
ACKNOWLEDGEMENTS	65

ABBREVIATIONS

AP – <i>abductor pollicis</i>	MC – Latvia’s plastic,
BKUS – Children’s Clinical	reconstructive, and microsurgery
University Hospital in Riga, Latvia	center
CMC – carpometacarpal joint	MCP – metacarpophalangeal joint
D – days	MTP – metatarsophalangeal joint
3D – three-dimensional	MIN – minutes
DASH – <i>disabilities of the arm,</i>	N – norm
<i>shoulder and hand</i>	KW – Kirschner wire
DEX – right-side	OMT – <i>Oberg, Manske, Tonkin</i>
DIP – distal interphalangeal joint	classification
DMTA – dorsal metatarsal artery	OP – operation/operated
EDC – <i>extensor digitorum comunis</i>	PEDI – paediatric evaluation of
EDB – <i>extensor digitorum brevis</i>	disability inventory
EDL – <i>extensor digitorum longus</i>	PIP – proximal interphalangeal
ECRL – <i>extensor carpi radialis</i>	joint
<i>longus</i>	PMTA – plantar metatarsal artery
EIP – <i>extensor indicis proprius</i>	PL – <i>palmaris longus</i>
FDMA – first dorsal metacarpal	RAKUS – Riga Eastern Clinical
arterial graft	University Hospital
FDS – <i>flexor digitorum</i>	RHD – right hand dominant
<i>superficialis</i>	ROM – range of motion
FGF – fibroblast growth factor	RSU – Rīga Stradiņš University
IP – interphalangeal joint	RTG – X-ray
ICF – informed consent form	SHH – <i>sonic hedgehog</i> gene
LHD – left hand dominant	SIN – left-side
M – months	SEX – gender
TMC – trapezometacarpal joint	VAS – visual analog scale

INTRODUCTION

Study objectives

Congenital hand anomalies have a relatively rare incidence. Stockholm's (Sweden) registry data base research states that the incidence is in about 21.5 children of 10,000 live births while Australia's registry claims 19.5 children in every 10,000, and Edinburg's (United Kingdom) registry reports 22.5 in every 10,000 [19,23]. Thumb hypoplasia is a rare congenital deformity that constitutes 3.5 % of all upper limb congenital deformities. In Latvia, the incidence of thumb congenital hypoplasia possibility is in 0.5–2 children per 10,000 newborns; however, precise data on birth defect incidence are not available [29].

Blauth's classification is used to characterise and differentiate the types of thumb hypoplasia. Thumb deformities are divided into five gradations: I – all the components of the digit are present, just small in size with a reduced webspace, II – thenar musculature hypoplasia, unstable *MCP* with extrinsic ligament pathology, III – severe II grade with possible structural deficiencies, IIIa – stable *CMC* joint, IIIb – unstable *CMC* joint, IV – rudimentary phalanx (*floating thumb*), V – total aplasia [37]. Surgical treatment is required for grade II – V deformities. Until 2007 in Latvia, thumb hypoplasia reconstructive operations included bone stabilisation methods such as arthrodesis and partial pollicization, which ensured stability of the finger but resulted in a severe reduction in finger functionality.

For the treatment of Grade II – IIIa thumb hypoplasia, it is recommended to salvage the first finger by stabilising the *MCP* joint and reconstructing the hypoplastic musculature. The basis for this surgical treatment is to extend the first web space and stabilize the *MCP* joint [36]. The preferred method is the third or fourth finger's superficial flexor tendon (*FDS*) transposition and transosseous fixation, which establishes stability but reduces grasp strength and

disarranges the fourth and fifth finger flexor system [37]. *Smith et al.* 2012. published a report that recommends considering the use of the pollicization method to treat Grade IIc, as stabilisation of the *MCP* joint is often unsuccessful. In 2007, MC launched a new reconstruction method – application of the second finger additional extensor tendon *EIP* transposition. Transposition of the *EIP* tendon is the main preferred method for reconstruction of a thumb's long extensor *EPL* in adults.

Pollicization is recommended to create a new finger by using the hand's second finger and rotating it to the thumb's location for grade IIIb-V thumb hypoplasia reconstruction [24]. The operation is characterised by well-functioning results, but a four-fingered hand is created. An alternative method can be to use the second toe transplantation technique; however, the method is very complicated and does not provide stable functionality [35]. In 2010, this second toe transplantation method was developed in the MC by using metatarsophalangeal joint arthrodesis in the transplant. *MTP* joint arthrodesis provides a stable and appropriate length of the metacarpal bone for the newly constructed thumb. As the child grows, the *CMC* joint is developed, and therefore, no additional ligament reconstruction is performed. The operation and postoperative periods as well as preliminary functional results are evaluated and allow justifying the effectiveness of this method and continuation of its application. The functional results of hand reconstructive methods are evaluated by the *DASH*, *ROM* and *VAS* international scales. *DASH* and/or *PEDI* scales are tailored to assess hand functionality results for children of all ages at various postoperative periods. These scales are adapted for interpretation in international literature [15,21].

Aim of this study

The aim of this study was to evaluate the complex postoperative results in children with congenital thumb hypoplasia for justification of new surgical techniques.

Research tasks

1. To retrospectively analyse operation and hospitalisation periods for patients treated with the new hand reconstruction method, as well as to analyse the complication statistics for the span 2007–2017.
2. To determine effectiveness of the modified reconstructive method for thumb hypoplasia grade II – IIIa by studying operation and hospitalisation periods, as well as to examine evaluation of the complex postoperative functionality.
3. To determine effectiveness of the new reconstructive method modification for thumb hypoplasia grade IIIB-V by studying operation and hospitalisation periods, as well as to examine evaluation of the complex postoperative functionality.
4. To compare postoperative functionality results of the new reconstructive method of the second toe transplantation with the results of the classic pollicization operation.
5. To compare the complex functionality evaluation results of thumb hypoplasia grade II – IIIa and IIIB-V with RSU's Anatomy and Anthropology Institute's anthropology laboratory research on the hand grasp strength indicators for children aged three to seven.
6. To define practical recommendations, based on the obtained data, for the implementation in paediatric hand surgery.

Scientific hypotheses

In the reconstruction of congenital hypoplasia grade II – IIIa deformity, the second finger's extensor (*EIP*) tendon transposition ensures functionality (function) of the thumb without reducing the grip (grasp strength) of the hand.

The second toe transplantation method with metatarsophalangeal (*MTP*) joint arthrodesis in the thumb hypoplasia grade IIIb-V reconstruction is surgically more complicated with a longer operative and hospitalisation duration, but it provides better functionality and aesthetic appearance than the classical pollicization method.

Place of work

This research is based at the Hand and Plastic Surgery Department at “Gaiļezers” of Riga Eastern Clinical University Hospital network, Latvia's Plastic, Reconstructive and Microsurgery Centre, and Children's Clinical University Hospital in Riga.

Scientific novelty

1. The second toe transplantation method with *MTP* joint arthrodesis is a new method which opens patients with thumb hypoplasia grade IIIb-V to the possibility of maintaining a five-fingered functional hand that is not functionally different from the results of the classic pollicization method. When evaluating the acquired postoperative results, it is recommended to change the surgical treatment principles for hypoplasia by using this second toe transplantation method with *MTP* joint arthrodesis for grade IIIb-V hypoplasia patients as an alternative, which retains a five-fingered hand.
2. The transosseous *EIP* tendon transposition method has been developed for surgical treatment of congenital thumb hypoplasia grade II – IIIa as the subperiosteally fixation ensures stability and functionality of the thumb.

Practical value of this research

Developed practical recommendations for the surgical treatment of congenital thumb hypoplasia include:

1. use of the *EIP* tendon transposition with subperiosteally fixation method for grade II and IIIa;
2. use of the second toe transplantation with *MTP* joint arthrodesis method for grade IIIb-V.

Research design and capacity

This Doctoral Dissertation is written in Latvian, summary is translated in English, and it consists of 10 chapters (sections). The study work has a total of 131 pages, which include seven drawings, 12 diagrams, 34 photographs, 24 tables and 24 attachments (appendices/supplements). Literature review includes 107 references.

Publications about the thesis topic

This thesis has resulted in four publications in peer-reviewed scientific journals. The publication list is added to the appendices/bibliography.

Patents

1. LV15420 (A) - Artificial Model Of Silicone And Polyurethane For Evaluation Of Thumb Joint Movement Activity
2. LV15388 (A) - Method Of External Determination Of Dynamic Of Effectiveness Of Function Of Metacarpophalangeal Joint In Children With Contraction Of Flexor Muscle After Extended Reconstruction Of Thumb

Medical technology

Mediacal technology – the Second Toe-To-Hand Transplantation with *MTP* Joint Arthrodesis Method for Full Length Thumb Reconstruction for Congenital Hand Hypoplasia IIIb-V Treatment has been submitted for approval in the National Health Service of the Republic of Latvia on 22.10.2018.

Mediacal technology – the Fourth Toe-To-Hand Transplantation for pediatric patients has been submitted for approval in the State Agency of Medicines of Latvia on 19.10.2019.

Clinical guidelines

Congenital Thumb Hypoplasia treatment guidelines was submitted for approval in the the Centre for Disease Prevention and Control of Latvia on 06.09.2019. (see attachment 24)

1. NEW SURGICAL METHOD

1.1. *EIP* transposition method

The method was developed in *MC* in 2007 to reconstruct patients with congenital thumb hypoplasia Grade II – IIIa. It is based on *EIP* transposition and subperiosteal fixation to stabilise *MTP* joint and *IP* joint simultaneously reconstructing adduction and extension for the thumb (see figure 1.1.).

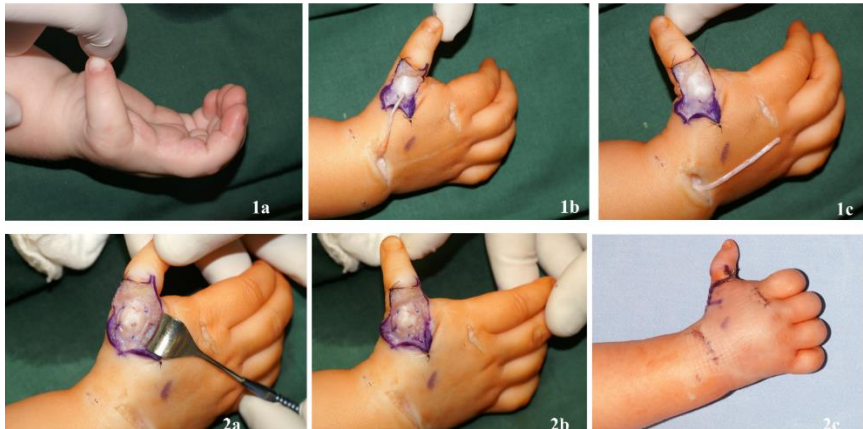


Figure 1.1. *EIP* transfer with subperiosteally fixation

1a Grade II hypoplasia patient with instability of MCP joint; 1b–1c *EIP* tendon transfer through three incisions; 2a–2b subperiosteally fixation of transferred tendon and stabilisation test; 2c – final fixation with k-wires

1.2. The new toe-to-hand transplantation method

Method was developed in 2010 and described by *Ozols et al.* 2019. The second toe-to-hand transplantation with *MTP* joint arthrodesis (see Figures 1.2.; 1.3. and 1.4.)

1.2.1. Preoperative preparation and anaesthesia

Operation field preparation for the second toe transplantation with the *MTP* joint arthrodesis was in adherence of sterilisation protocols. In addition to general anaesthesia, two peripheral nerve blockades were implemented: at the

ankle joint – *n.tibialis*, *n.suralis*, *n.peroneus superficialis et profundus*, and at the wrist joint – *n.medianus*, *n.radialis*, *n.ulnaris et ramus dorsalis n.ulnaris*. Prolonged anaesthetics such as 0.25 % *Levobupivacaini hydrochloridum* (Chirocaine®) or 0.25 % *Ropivacaine hydrochloride* (Naropin®) were used for these local nerve blockades. Local peripheral anaesthesia reduces postoperative pain as well as necessity for narcotics and myorelaxants during operation.

1.2.2. Hand phase

Arterial tourniquet is to be applied before the thumb's structure dissection. Liberate the digital nerves, flexor and extensor tendons, and if a patient does not have developed flexor and extensor tendons, then the *PL* and *EIP* tendons are to be used. Additionally, the second finger's intrinsic musculature is to be dissected as it will be utilised in providing abduction. For patients with congenital deformities, the hand's anatomy is peculiar and its variability can be incredible; therefore, it is challenging to forecast development and location of structures resulting in difficult reconstruction planning as each transplanted digit requires circulation, venous return, innervation and movement mechanisms.

All stages of embryogenesis are important for extremity development; however, the basic principles must be recognised that development of tendons and nerves requires bony structures, yet that does not indicate that if there is digital or hand aplasia, then there will not be musculature [10,22]. Nevertheless, it seems that these aplastic hands display functioning muscles as the flexor and extensor musculature are frequently connected and thus retain mobility; however, the muscles have reduced strength and the full range of motion may not be possible to reconstruct for hypoplasia patients. Generally, *a.radialis* is used as the basis for arterial anastomosis, but careful evaluation must be performed as the thumb's fourth and fifth degree of congenital hypoplasia may have a hypoplastic or undeveloped radial artery [41]. In these cases, the ulnar artery or the common digital artery should be used. It is possible to perform a

preoperative angiography to evaluate the arterial supply of the forearm and hand; however, digital subtraction angiography is an invasive method and its usage has no unequivocal effect on finger transplantation.

1.2.3. Foot phase

After application of the arterial tourniquet, incise the skin of the dorsal side of the foot's first interdigital space where the variant of the arterial supply of the second toe will be identified. Circulation of the second toe is supplied by either the first dorsal metatarsal artery (*DMTA*) or by the first plantar metatarsal artery (*PMTA*) [7,8]. To appropriately evaluate dominant blood circulation for the second toe, there are two variants – either the dorsal blood supply in which the largest artery is located on the dorsal side of the foot or the plantar dorsal supply which is located on the plantar side of the foot. The importance of dominant artery identification is to ensure maximum blood flow to the toe. Circulation variations and their percentage distribution differ for many authors, such as *Greenberg and May's* study published in 1988 stating that up to 90 % determine the dominant dorsal type of circulation, but *Kay and Wiberg* in 1996 published a statement in which only 60 % found the dominant dorsal circulation [13,18]. *Ozols et al.* 2019. published results of possibility to use forth toe for the thumb reconstruction.

After circulation system identification, one artery and one (rarely two) subcutaneous vein are dissected. The tendons of the extensor group such as *extensor digitorum longus et brevis* (*EDL* and *EDB*) are also dissected, and if possible for identification, the dorsal part of the digital nerve is included for dissection. On the plantar side, both digital nerves released, spared, and redistributed to the first and third toes. Dissection continues with tenolysis of the flexor tendons (*FDP* and *FDS*), by dividing them at the base of the metatarsal with the possibility that even more proximal location is needed. Post tenolysis, the first annular tendon is visualised and is to be divided. Once the tendons have

been dissected, advance to the musculature and split the small foot muscles surrounding the second toe (spaces between the first/second and second/third toe). This progress enables for osteotomy at the metatarsal bone level and, therefore, the transplant toe is isolated and only attached by pedicle.

The tourniquet is removed to verify preserved circulation of the toe. Once circulation has been confirmed, the *MTP* joint arthrodesis is performed while maintaining the growth zone of the proximal phalanx. Traumatism of this growth zone can visibly and significantly reduce further development of the transplant [7]. At this stage, usually an arthrotomy is carried out from the opposite side of where the vascular bundle is located while visualising the joint's cartilage and performing the resection sharply. The transplant is to be fixated longitudinally with one 0.8–0.9 mm *Kirschner* wire.

1.2.4. Microsurgery phase

To ensure blood supply for patients with thumb hypoplasia, *a.radialis* is more often selected as a recipient blood vessel than *a.ulnaris*. However, cases in which *a.radialis* is underdeveloped or even underdeveloped *radial club hand* are present, the subcutaneous veins of the dorsal side are a better choice for venous return [38,39]. Anastomoses are secured with nylon 8/0–10/0 interrupted sutures. The arterial seam can be either end-end or side-end as the type is individualised for each patient by considering the congenital deformity. There are usually no problems in providing sensory innervation as the connection is secured by attaching the toe's plantar digital nerves with the *ramus dorsalis n.radialis* or even the hypoplastic thumb's digital nerves [6,17].

1.2.5. Ballast and movement apparatus reconstruction

In order to restore thumb movements, at least three functioning muscles are needed to provide flexion, extension, and abduction [18,27]. Reconstruction of thumb abduction is the most complicated, but it is the most important function. The choices of possible musculature used for thumb reconstruction include: for

flexion – the tendon of *m.palmaris longus* or any tendon of *mm.flexor digitorum superficialis*, for extension – *m.extensor indicis proprius* of the index finger or any tendon from the *mm.extensor digitorum communis*, and for abduction – the second finger’s intrinsic musculature or *m.abductor digiti minimi* or any tendon of *mm.flexor digitorum superficialis* [42,44].

The transplanted finger is placed above the first *CMC* joint or at the site where the potential *CMC* joint will be created. Patients with grade IIIb-V hypoplasia do not develop the first *CMC* joint, and thus, the transplant fixation site will be either at the projection of *os trapezium* or *os scaphoideum*. The transplant should be placed in opposition to the fourth and fifth finger and its length should be until the middle or distal third of the second finger’s proximal phalanx. Two *Kirschner* 0.9–1.0 mm wires provide the transplant’s fixation to the base.

1.2.6. Donor site closure

After the removal of the toe, hemostasis was controlled and intermetatarsal ligaments were reconstructed to reduce the second interdigital space. The ligament reconstruction uses 2/0–3/0 absorbable or non-absorbable thread. The cutaneous and subcutaneous layers are to be closed in the classic method, using either continuous or interrupted sutures with absorbable or non-absorbable 4/0–3/0 thread. Sterile, aseptic, non-adhesive bandaging should be applied as well as it is imperative for immobilisation using a L-type splint. Immobilisation is necessary until the fourth postoperative week.

1.2.7. Postoperative period and early rehabilitation

Surgical sites (wounds) were closed with simple interrupted sutures using absorbable or rarely non-absorbable thread 4/0-5/0. In the hand, the subcutaneous layer was not sutured. Immobilisation and wound dressing was realised using sterile aseptic bandages and a splint, which wound around the first digit. Immobilisation should be intact until the fifth postoperative week and after

control x-ray evaluation of bone consolidation, the osteosynthesis structure are to be evacuated around the fourth–sixth postoperative week.

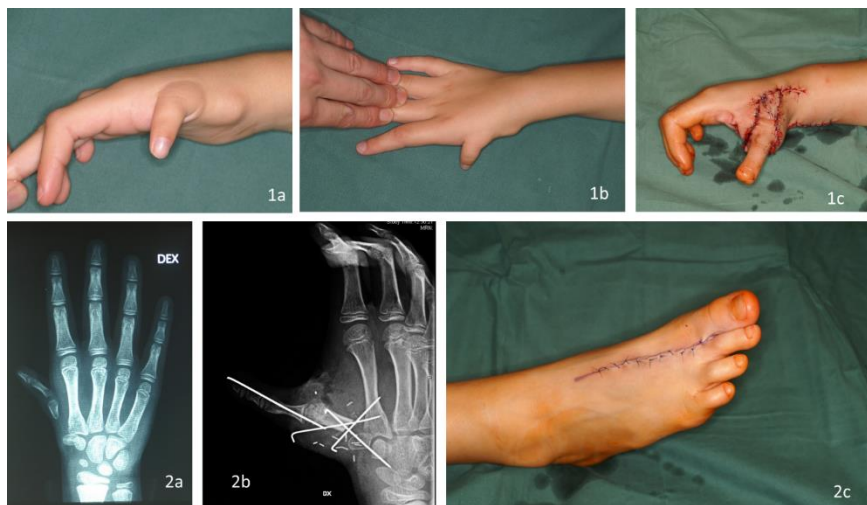


Figure 1.2. New surgical method

1a–1b thumb hypoplasia IIIb; 1c – toe-to hand transplantation (operation theater view); 2a – X-ray of thumb hypoplasia Grade IIIb; 2b – X-ray after toe-to hand transplantation with *MTP* joint arthrodesis method (fixation with k-wires); 2c – donorside

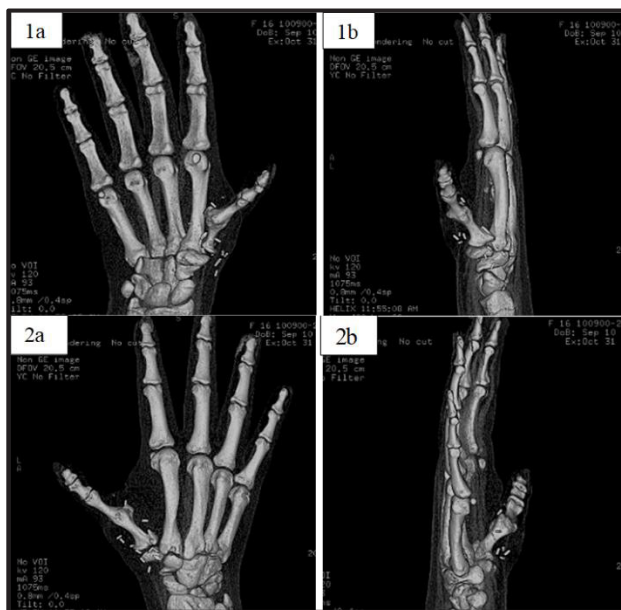

Figure 1.3. **New surgical method postoperative 3D computer tomography**
 1a – hand's volar surface; 1b – first digit's radial side view; 2a – hand's dorsal surface;
 2b – first digit's ulnar side view

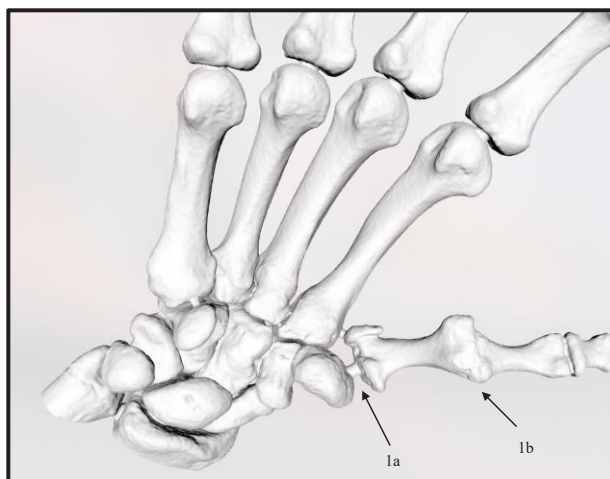


Figure 1.4. **New surgical method 3D modelled joints**
 1a – neoCMC joint; 1b – healed MTP joint

2. RESEARCH/STUDY SECTION

2.1. Retrospective section

Thumb hypoplasia grade II and IIIa reconstruction uses *EIP* tendon transposition with subperiosteal fixation operation method. Thumb hypoplasia grade IIIb-V reconstruction uses a new surgical method of the second toe transplantation with *MTP* joint arthrodesis and the classical pollicization operation method. In the time frame of 2007–2017, 21 patients were examined for congenital thumb hypoplasia including five bilateral cases (see charts 2.1. and 2.2.). 25 reconstructive operations were performed for this group of patients at the MC. These operations were divided in 11 for Grade II thumb hypoplasia treatment, four for grade IIIa, three for grade IIIb, one for grade IV, and two for grade V.

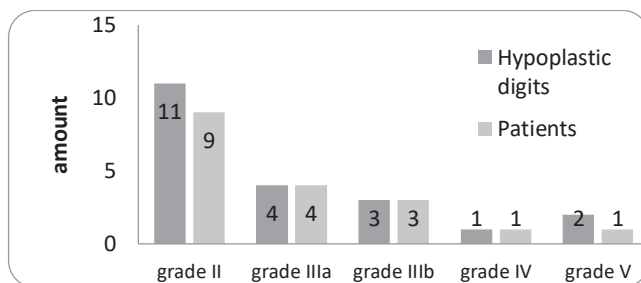


Chart 2.1. Thumb hypoplasia patients

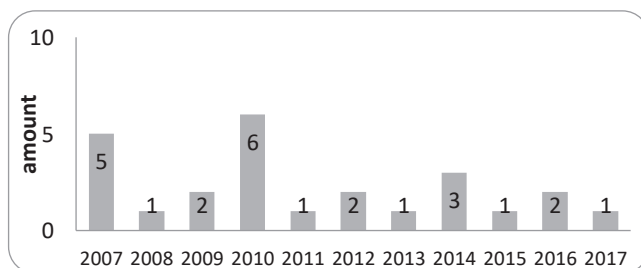


Chart 2.2. Thumb hypoplasia operations

2.2. Prospective section

2.2.1. Evaluation of complex postoperative functional results

There were 18 operated patients diagnosed with grade II – V thumb hypoplasia included in trial. The *EIP* tendon transposition method was used for 14 patients, pollicization for two patients, and the remaining two patients had the second toe transplantation with *MTP* joint arthrodesis performed (see chart 1). The complex postoperative functional results were compared with the study results on the hand grasp strength indicators for children from RSU's Anatomy and Anthropology Institute's anthropology laboratory. This study had included 970 children aged three to seven years.

2.2.2. Evaluation of aesthetic results

The evaluation study had 285 respondents, which included 193 women (67.4 %) and 92 men (32.6 %) (see chart 2.3.). The majority were 19–30 years of age (64.2 %), and 67 % of the respondents had received higher education. These surveyed respondents also consisted of 139 professionals (48.8 %) in medical and healthcare field, while the other 146 (51.2 %) work or study in other sectors.

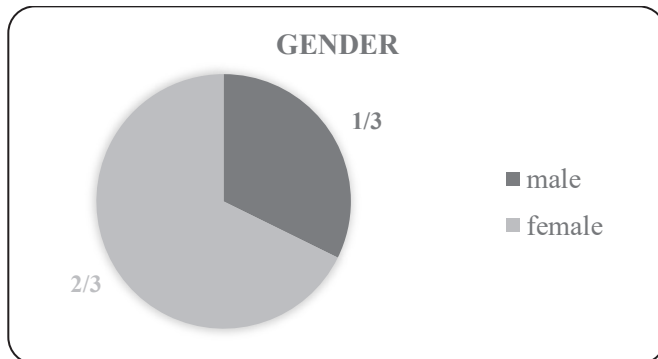


Chart 2.3. Respondents gender

2.3. Research methods

2.3.1. Retrospective section of the research

Analyses of the operation period, postoperative period and operation complications were performed for patients with Grade II – V thumb hypoplasia treated from 2007–2017 via hospitalisation and outpatient records at RAKUS, MC, and BKUS.

2.3.2. Prospective section of the research

Evaluation of complex postoperative functional results

The Disabilities of the Arm, Shoulder and Hand (DASH) score and the Paediatric Evaluation of Disability Inventory (PEDI) questionnaire as well as determining the scores on the visual analogue scale (VAS) and range of motion (ROM) were used to evaluate the subsequent functional results [3,4,15,26]. These scores and questionnaires for this study were assessed in every person during outpatient visits.

***DASH* questionnaire**

This questionnaire is intended for evaluation and comparison of upper limb postoperative functional results of patients, based on 30 questions about a patient's functionality with the maximum possible score of 100 points. DASH data interpretation requires a minimum of 27 questions to be answered. The formula used to calculate the data is: $\text{DASH number} = ([\text{sum of } n \text{ answers}] / n) - 1$ (25). The number of the answered questions is represented by “*n*.” A normal score is considered to range from 0–16 [1,14].

***PEDI* questionnaire**

The computerised version, *Paediatric Evaluation of Disability Inventory – Computer Adaptive Test (PEDI-CAT) – 2nd edition (2012)*, was used in this study. This questionnaire is intended for children from the age of six months to seven and a half years. The questionnaire is about evaluating functions such as

mobility (59 questions), self-care (73 questions), and social function (65 questions). The score can range from 0–100 points; therefore, if the maximum is tallied, the child does not have any functional impediments [3,4].

VAS scale

The visual analogue scale (VAS) was used to evaluate patients' aesthetic data in which the score can range from 1–10, the smallest number corresponds to a better evaluation. VAS was dividing into two components – *v* for visual, and *f* for functional. Patients and their parents had to answer questions for each component: “*Does the reconstructed first finger look like a thumb?*” “*Does the reconstructed first finger behave like a thumb?*”

ROM scale

A goniometer was used to measure the movement spectrum of the reconstructed finger joints. The acquired data were interpreted by using the first finger movement spectrum standards determined in *Barakat et al.* published study in 2013[2].

Comparison of the postoperative results complex

Evaluation of the hand's functionality consisted of strength/force measurements: crush grip and pinch grip. Grip strength is based on stability of the thumb and the other fingers' strength, even though the pinch grip is provided by mobility of the thumb and forefinger. Strength measurements were established for both hands by using a balloon (pneumatic) and a mechanical (janmar) dynamometer. To evaluate the postoperative results for each patient, a comparison was made between the operated hand and the healthy hand. These strength measurements were further compared to standard functional strength results of children of the corresponding age. These standards were determined by RSU's Anatomy and Anthropology Institute's anthropology laboratory's research on the grip strength of 970 patients aged three to seven years.

Evaluation of the questionnaires for interpretation of postoperative aesthetic results

This study used questionnaires for two types of thumb hypoplasia grade IIb-V surgical treatment methods (pollicization and the new surgical method) for evaluation of aesthetic results. The main task was to evaluate these results on a scale from 1–10. Considering that this new surgical method utilises the second toe, additional evaluation of the donor site was performed. Social media such as *Facebook* and *WhatsApp* were used to distribute these questionnaires.

2.4. Inclusion and exclusion criteria

2.4.1. Inclusion criteria

1. Children aged 0–18 years with congenital thumb hypoplasia Grade II – V, who were treated surgically at RAKUS MC from 2007–2017.
2. Thumb hypoplasia Grade II – IIIa reconstruction included the MC recommended *EIP* transposition operation method or the *FDS* transposition operation method.
3. Thumb hypoplasia Grade IIb-V reconstruction consisted of the MC recommended technique of the second toe transplantation with *MTP* joint arthrodesis or the classic pollicization method.
4. Operated patients who had quality preoperative and postoperative photographs available.

2.4.2. Exclusion criteria

1. Children aged 0–18 years with congenital thumb hypoplasia Grade I.
2. Children or parents of children who refused to participate in this study.
3. Patients whose complex postoperative functional evaluation data not obtained.

4. Children who do not have quality preoperative and postoperative photographs available.

Patient **No 21** – refused from the planned pollicization operation – was **excluded from the study**. Patient **No 19** – late postoperative data not available as the patient left the country and follow-up data cannot be obtained; the patient’s operation and hospitalisation data were used. Patient **No 20** – no surgical treatment – was **excluded from the study**. Children with congenital thumb hypoplasia Grade I typically do not seek a specialist as there are only minimal changes that generally do not affect the thumb’s function. Thumb hypoplasia Grade I does not require surgical treatment. Five patients from this research were diagnosed with Grade I in the “healthy” arm. This study included 18 patients (21 hands) with congenital thumb hypoplasia Grade II – V (see chart No 1).

2.5. Statistical methods used

Data acquired from the results of postoperative aesthetic questionnaires and the study group as well as data from the retrospective study were systematised in *Microsoft Excel* 2016 data processing programme. The acquired functional data was compared with the population standards respective to the age group (control group). The analysis was realised by using *IBM SPSS Statistics v.22 (Statistical Package for the Social Sciences) independent samples t-test (Student’s t-test)*. Aesthetic questionnaires acquired data results comparing the new transplantation method and the classic pollicization method were systematised in *Microsoft Excel* 2016. Data analyses were performed by using *IBM SPSS Statistics v.22 (Statistical Package for the Social Sciences) Paired samples t-tests (Student’s t-test) and Wilcoxon-Mann-Whitney test* [20]. Evaluation of statistical hypotheses assessment used the significance level ($p \leq 0.05$ for acceptance and $p > 0.05$ for rejection).

2.6. Ethical aspects

This study was evaluated by the Ethics Committee of Riga Eastern Clinical University Hospital's medical and biomedical research foundation and received authorisation No 16-A / 14.06.2014. Parents of the patients participating in this study signed the consent form (ICF).

3. RESULTS

3.1. Patients treated with the transposition method (n=14)

Patient 1. RHD. Congenital hypoplasia of the **second (II) stage** of the first fingers of **both hands**.

Right-hand reconstruction at the age of 11 months, left-hand operated at the age of 20 months. Treatment used – transposition of the *EIP* tendon. Surgery time for reconstruction of the left-hand thumb – 1 hour and 30 minutes, right hand thumb reconstruction – 0 hours for 50 minutes, hospitalisation time – two days. Assessment of post-operative results at the age of 84 months, questionnaire data: *DASH* 5.2 points, *PEDI* 66 points, *VAS(v)* 1 point, *VAS(f)* 2 points and functional data: *Grasp dex(op)* 6kg, *sin(op)* 12 kg, ratio operative vs. healthy – n/a, *Pinch dex(op)* 2 kg, *sin(op)* 2 kg, ratio operative vs. healthy – n/a. *ROM: IP(dex)* 10/0/0, *IP(sin)* 30/0/0, *MCP(dex)* 20/0/0, *MCP(sin)* 5/0/0, *CMC(dex)* 15/0/10, *CMC(sin)* 20/0/10. Post-operative inspection at 7 years old (see Figure 3.1).

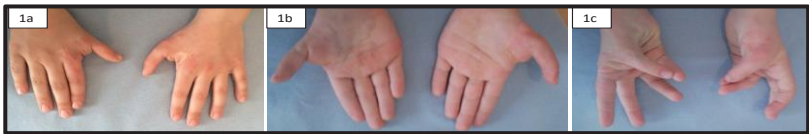

Figure 3.1. **Patient 1 Post-operative images** (photographs of the author)
1a – view on the dorsal side; 1b – view on the volar side; 1c – first and fifth finger grip

Patient 2. LHD. Congenital hypoplasia of the **second (II) grade** of the first finger of the **right hand**.

Right-hand reconstruction at the age of 11 months. Treatment applied – transposition of the *EIP* tendon. Surgery time for right-hand thumb reconstruction – 1 hour and 55 minutes, inpatient spent 2 days. Evaluation of post-operative results at the age of 57 months, questionnaire data: *DASH* 0.9 points, *PEDI* 70 points, *VAS(v)* 1 point, *VAS(f)* 1 point and functional data *Grasp*

dex(op) 8 kg, *sin* 8 kg, ratio operative vs. healthy – 1. *Pinch dex(op)* 3 kg, *sin* 3 kg, ratio operative vs. healthy – 1. ROM: *IP(dex)* 45/0/0, *IP(sin)* 85/0/0, *MCP(dex)* 50/0/10, *MCP(sin)* 60/0/10, *CMC(dex)* 45/0/15, *CMC(sin)* 45/0/10. Assessment of post-operative results at the age of 5 (see Figure 3.2).

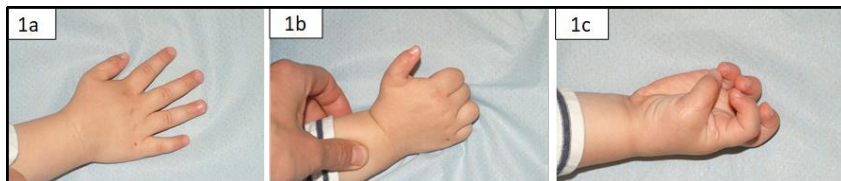

Figure 3.2. **Patient 2 post-operative images** (photographs of the author)
 1a – view on the dorsal side; 1b – view on the volar side; 1c – first and fifth finger grip

Patient 3. LHD. Congenital hypoplasia of the **second (II) grade** of the first finger of the **right hand**.

Right hand reconstruction at the age of 128 months. Treatment applied – transposition of the *EIP* tendon. Surgery time for right-hand thumb reconstruction – 1 hour and 5 minutes, inpatient spent 2 days. Assessment of post-operative results at the age of 136 months, questionnaire data: *DASH* 3.6 points, *PEDI* 65 points, *VAS(v)* 1 point, *VAS(f)* 1 and functional data: *Grasp dex(op)* 10 kg, *sin* 10 kg, ratio operative vs. healthy – 1. *Pinch dex(op)* 3.5 kg and *sin* 3.5 kg, ratio operative vs. healthy – 1. ROM: *IP(dex)* 30/0/0, *IP(sin)* 60/0/0, *MCP(dex)* 60/0/10, *MCP(sin)* 60/0/10, *CMC(dex)* 40/0/10, *CMC(sin)* 40/0/10. Evaluation of post-operative results at the age of 11 (see Figure 3.3).

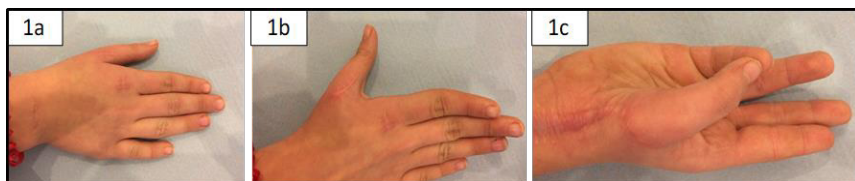

Figure 3.3. **Patient 3 post-operative images** (photographs of the author)
 1a – view on the dorsal side; 1b – view on the volar side; 1c – first and fifth finger grip

Patient 4. RHD. Congenital hypoplasia of the **second (II) grade** of the first finger of the **left hand**.

Left-hand reconstruction at the age of 11 months. Treatment applied – implementing the *EIP* tendon. Surgery time for left hand thumb reconstruction – 0 hours for 45 minutes, inpatient spent 2 days. Assessment of post-operative results at the age of 34 months, questionnaire data: *DASH* 17.9 points, *PEDI* 60 points, *VAS(v)* 1 point, *VAS(f)* 1 and functional data: *Grasp dex* 3.5 kg, *sin(op)* 3 kg, ratio operative vs. healthy – 0.85. *Pinch dex* 2.5 kg un *sin(op)* 2 kg, ratio operative vs. healthy – 0.8. *ROM*: *IP(dex)* 50/0/0, *IP(sin)* 80/0/0, *MCP(dex)* 60/0/10, *MCP(sin)* 80/0/10, *CMC(dex)* 25/0/10, *CMC(sin)* 45/0/10. Assessment of post-operative results at the age of 3 (see Figure 3.4).

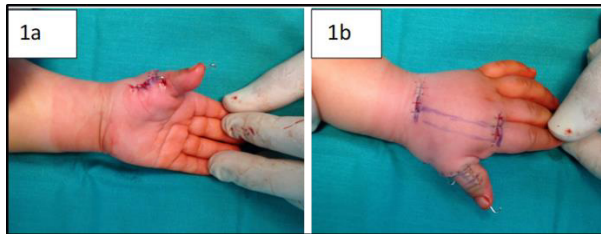


Figure 3.4. **Patient 4 operative images. Classical incisions for the *EIP* transposition** (author photographs)

1a – view on the dorsal side; 1b – view on the volar side

Patient 5. RHD. Congenital hypoplasia of the **second (II) grade** of the first finger of the **right hand**.

Right-hand reconstruction at the age of 20 months. Treatment applied – transposition of the *EIP* tendon. Surgery time for right-hand thumb reconstruction – 0 hours 55 minutes, inpatient spent 2 days. Assessment of post-operative results at the age of 72 months, questionnaire data: *DASH* 6.5 points, *PEDI* 63 points, *VAS(v)* 2 points, *VAS(f)* 2 points. Questionnaire notes say they do not like an unaesthetic short thumb. Functional outcome: *Grasp dex(op)* 12 kg, *sin* 12 kg, ratio operative vs. healthy – 1. *Pinch dex(op)* 3.5 kg, *sin* 4.5 kg,

ratio operative vs. healthy – 0.78. ROM: *IP(dex)* 60/0/0, *IP(sin)* 80/0/0, *MCP(dex)* 60/0/0, *MCP(sin)* 90/0/0, *CMC(dex)* 70/0/10, *CMC(sin)* 45/0/20. Assessment of post-operative results at 6 years of age (see Figure 3.5.).

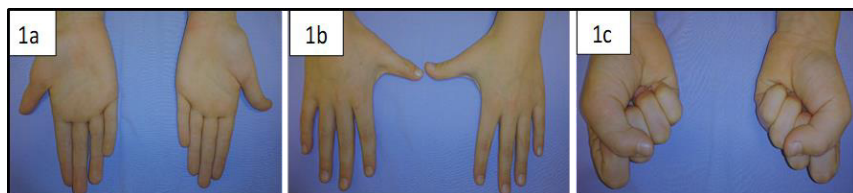

Figure 3.5. **Post-operative images of patient 5** (author photographs)

1a – volar surfaces of both hands; 1b – dorsal surfaces of both hands; 1c – flexion of the thumb

Patient 6. RHD. Congenital hypoplasia of **grade three a (IIIa)** of the first finger of the **right hand**.

Right-hand reconstruction at 18 months old. Treatment applied – transposition of the *EIP* tendon. Time of surgery for right-hand thumb reconstruction – 0 hours for 30 minutes, inpatient spent 2 days. Evaluation of post-operative results at 5 years old, questionnaire data: *DASH* 56.3 points, *PEDI* 53 points, *VAS(v)* 4 points, *VAS(f)* 6 points. The questionnaire indicates that large items cannot be grasped. Functional outcome: *Grasp dex(op)* 2 kg, *sin* 2.5 kg, ratio operative vs. healthy – 0.5. *Pinch dex(op)* 0.5 kg, *sin* 1.5 kg, ratio operative vs. healthy – 0.33. ROM: *IP(dex)* 5/0/0, *IP(sin)* 50/0/0, *MCP(dex)* 5/0/0, *MCP(sin)* 40/0/10, *CMC(dex)* 15/0/10, *CMC(sin)* 10/0/10. Assessment of post-operative results at 5 years of age (see Figure 3.6).

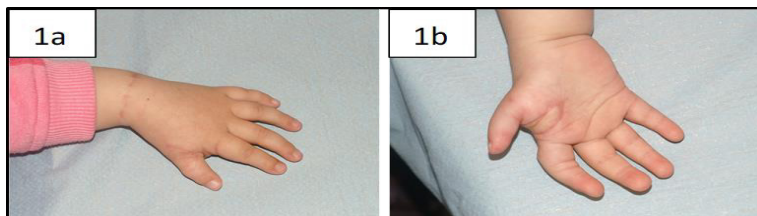


Figure 3.6. **Post-operative images of patient 6** (author photographs)

1a – hand dorsal surface; 1b – palm volar surface

Patient 7. LHD. Congenital **right hand third b (IIIb) grade** hypoplasia of the **first finger**.

Right-hand reconstruction at the age of 17 months. Treatment applied – implant of the *EIP* tendon in combination with unrounded phalange transplantation for metacarpal bone stabilisation. Time of surgery for right-hand thumb reconstruction – 1 hour and ten minutes, inpatient spent 2 days. Assessment of post-operative results at 6 years old, questionnaire data: *DASH* 51.7 points, *PEDI* 52 points, *VAS(v)* 3 points, *VAS(f)* 7 points. The questionnaire indicates that large items cannot be grasped. Functional outcome: *Grasp dex(op)* 2 kg, *sin* 6 kg, ratio operative vs. healthy – 0.33. *Pinch dex(op)* 0.5 kg, *sin* 3 kg, ratio operative vs. healthy – 0.17. *ROM: IP(dex)* 5/0/0, *IP(sin)* 70/0/0, *MCP(dex)* 20/0/0, *MCP(sin)* 50/0/20, *CMC(dex)* 25/0/0, *CMC(sin)* 50/0/10. Assessment of post-operative results at the age of 6 years (see Figure 3.7).

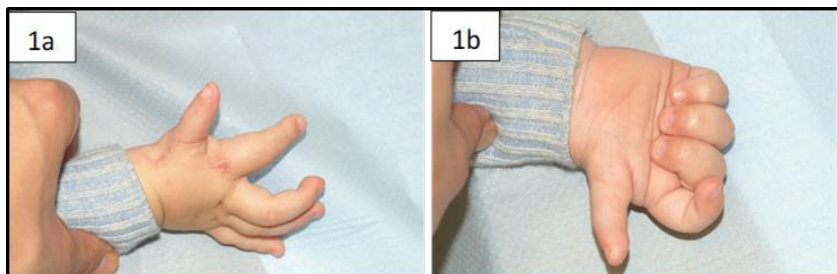


Figure 3.7. **Post-operative images of patient 7** (author photographs)
1a – Max abduction of the thumb, 1b – maximum extension of the thumb

Patient 8. RHD. Congenital hypoplasia of the **second (II) grade** of the first finger of the **left hand**.

Left-hand reconstruction at the age of 42 months. Treatment applied – transposition of the *EIP* tendon. Surgery time for left hand thumb reconstruction – 0 hours 55 minutes, inpatient spent 2 days. Assessment of post-operative results at the age of 96 months, questionnaire data: *DASH* 0.9 points, *PEDI* 68 points,

VAS(v) 2 points, *VAS(f)* 1. Functional results: *Grasp dex* 1.6 kg, *sin(op)* 10 kg, ratio operative vs. healthy – 6.25. *Pinch dex* 4 kg, *sin(op)* 2 kg, ratio operative vs. healthy – 0.5. ROM: *IP(dex)* 45/0/0, *IP(sin)* 85/0/0, *MCP(dex)* 50/0/20, *MCP(sin)* 60/0/15, *CMC(dex)* 20/0/15, *CMC(sin)* 20/0/15. Assessment of post-operative results at the age of 8 (see Figure 3.8).

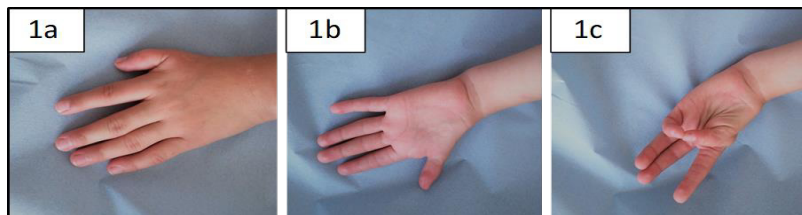


Figure 3.8. **Post-operative images of patient 8** (author photographs)
1a – hand dorsal surface; 1b – palm volar surface; 1c – grip of first and fifth fingers

Patient 9. RHD. Congenital hypoplasia of the **second (II) grade** of the first fingers of **both hands**.

Right-hand reconstruction at 11 months old, left-hand operated at 17 months old. Treatment applied – transposition of the *EIP* tendon. Surgery time for right-hand thumb reconstruction – 0 hours 50 minutes, left hands – 0 hours for 45 minutes, hospitalization time – 2 days each time. Assessment of post-operative results at the age of 96 months, questionnaire data: *DASH* 4.3 points, *PEDI* 67 points, *VAS(v)* 1 point, *VAS(f)* 1. Functional results: *Grasp dex(op)* 20 kg, *sin(op)* 20 kg, ratio operative vs. healthy – n/a, *Pinch dex(op)* 5 kg, *sin(op)* 5 kg, ratio operative vs. healthy – n/a. ROM: *IP(dex)* 70/0/0, *IP(sin)* 80/20/20, *MCP(dex)* 60/0/40, *MCP(sin)* 50/0/10, *CMC(dex)* 15/0/10, *CMC(sin)* 15/0/10. Assessment of post-operative results at the age of 8 years (see Figure 3.9).

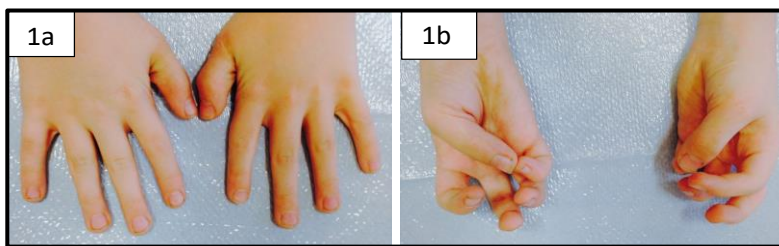


Figure 3.9. **Post-operative images of patient** (author photographs)
1a – dorsal surfaces of both hands; 1b – grip of first and fifth finger on both hands

Patient 10. RHD. Congenital hypoplasia of **grade three a (IIIa)** of the first finger of the **left hand**.

Left-hand reconstruction at the age of 12 months. Treatment applied – transposition of the *EIP* tendon. Surgery time for left hand thumb reconstruction – 0 hours for 50 minutes, inpatient spent 2 days. Assessment of post-operative results at the age of 125 months, questionnaire data: *DASH* 30.2 points, *PEDI* 60 points, *VAS(v)* 5 points, *VAS(f)* 5 points. Functional results: *Grasp dex* 5 kg and *sin(op)* 16.6 kg, ratio operative vs. healthy – 3.32. *Pinch dex* 1.5 kg, *sin(op)* 2 kg, ratio operative vs. healthy – 1.33. *ROM: IP(dex)* 10/0/0, *IP(sin)* 60/0/0, *MCP(dex)* 30/0/20, *MCP(sin)* 90/0/30, *CMC(dex)* 20/0/20, *CMC(sin)* 20/0/20. Assessment of late post-operative results at the age of 10 (see Figure 3.10).

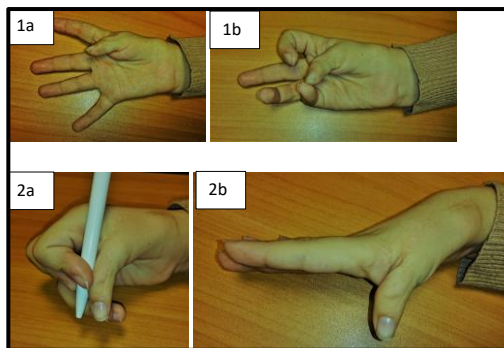


Figure 3.10. **Post-operative images of patient 10** (author photographs)
1a – Max flexion of the thumb; 1b – first and fifth fingers grip; 2a – first finger functional assessment; 2b – maximum abduction of the thumb

Patient 11. RHD. Congenital hypoplasia of **grade three a (IIIa)** of the first finger of the **left hand**.

Left-hand reconstruction at the age of 102 months. Treatment applied – transposition of the *EIP* tendon. Surgery time for left hand thumb reconstruction – 0 hours 55 minutes, inpatient spent 2 days. Evaluation of post-operative results at the age of 136 months, questionnaire data: *DASH* 12.1, *PEDI* 61, *VAS(v)* 5 points, *VAS(f)* 5 points. The questionnaire shows that it is difficult to grasp large items. Functional results: *Grasp dex* 14.9 kg, *sin(op)* 4.5 kg, ratio operative vs. healthy – 0.3. *Pinch dex* 2.6 kg and *sin(op)* 1.3 kg, ratio operative vs. healthy – 0.58. *ROM: IP(dex)* 90/0/0, *IP(sin)* 10/0/0, *MCP(dex)* 50/0/25, *MCP(sin)* 30/0/30, *CMC(dex)* 20/0/30, *CMC(sin)* 10/0/30. Evaluation of post-operative results at the age of 11 years (see Figure 3.11).

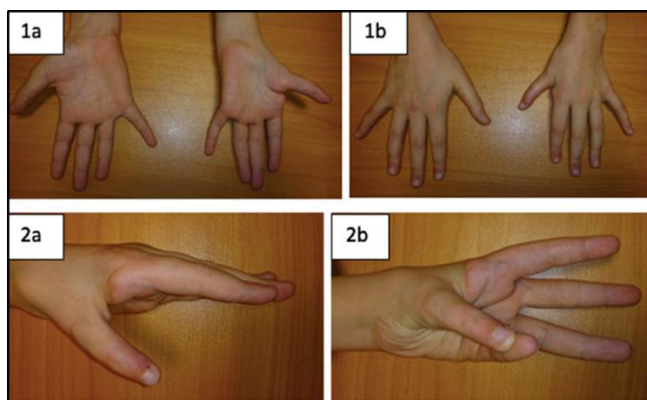


Figure 3.11. **Post-operative images of patient 11** (author photographs)
1a – volar surfaces of both hands; 1b – dorsal surfaces of both hands; 2a – maximum abduction of the thumb; 2b – first and fifth finger grip

Patient 12. LRD. Congenital hypoplasia of the **second (II)** grade of the first finger of the **left hand**.

Left-hand reconstruction at the age of 68 months. Treatment applied – transposition of the *EIP* tendon. Surgery time for left hand thumb reconstruction

– 0 hours 55 minutes, inpatient spent 2 days. Assessment of post-operative results at the age of 71 months, questionnaire data: *DASH* 4.5 points, *PEDI* 61 points, *VAS(v)* 2 points, *VAS(f)* 2 points. Functional results: *Grasp dex* 8 kg, *sin(op)* 7 kg, ratio operative vs. healthy – 0.88. *Pinch dex* 3 kg, *sin(op)* 2 kg, ratio operative vs. healthy – 0.67. *ROM: IP(dex)* 100/0/0, *IP(sin)* 60/0/0, *MCP(dex)* 90/0/0, *MCP(sin)* 70/0/20, *CMC(dex)* 15/0/10, *CMC(sin)* 15/0/10. Assessment of post-operative results at age of 6 years (see Figure 3.12).

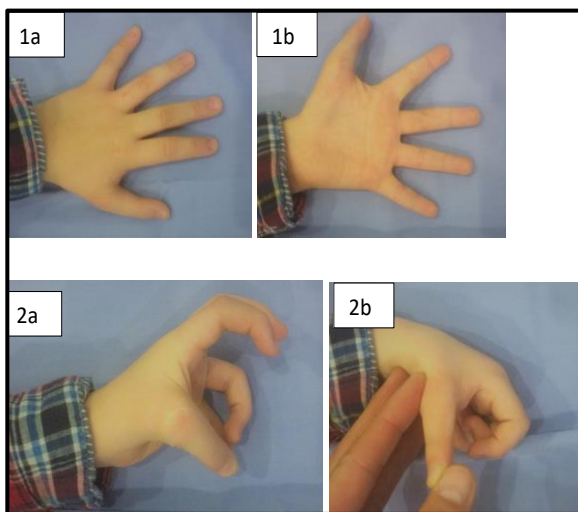


Figure 3.12. **Patient 12 post-operative images** (author photographs)
 1a – wrist dorsal surface; 1b – wrist volar surface; 2a – first and fifth fingers grip; 2b – assessment of the stability of the first finger *MCP* joint

Patient 13. LHD. Congenital hypoplasia of the thumbs of **both hands**. Hypoplasia of **third (IIIa) grade** of the first finger of the **right hand** and hypoplasia of the **first (I) grade** of the **left hand**.

Right-hand reconstruction at the age of 110 months. Treatment applied – transposition of the *EIP* tendon. Surgery time for right-hand thumb reconstruction – 1 hour 50 minutes, inpatient spent 2 days. Assessment of post-operative results at the age of 197 months, questionnaire data: *DASH* 1.7 points,

PEDI 65 points, *VAS(v)* 5 points, *VAS(f)* 5 points. Functional results: *Grasp dex(op)* 10 kg, *sin* 25 kg, ratio operative vs. healthy – 0.39. *Pinch dex(op)* 4 kg, *sin* 3 kg, ratio operative vs. healthy – 1.33. *ROM: IP(dex)* 10/0/0, *IP(sin)* 30/0/0, *MCP(dex)* 40/0/5, *MCP(sin)* 40/0/10, *CMC(dex)* 20/0/0, *CMC(sin)* 20/0/10. Assessment of post-operative results at age of 16 years (see Figure 3.13).

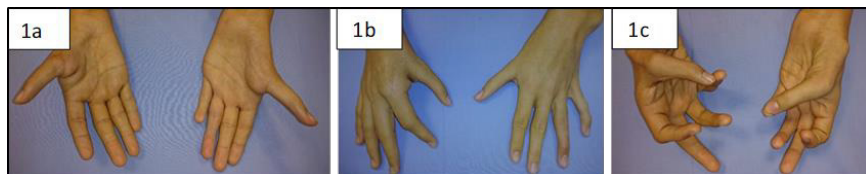


Figure 3.13. **Patient 13 post-operative images** (author photographs)
1a – volar surface of both hands; 1b – dorsal surfaces of both hands; 1c – grip of the first and fifth fingers of both hands

Patient 14. LHD. Congenital hypoplasia of the thumbs of **both hands**. Hypoplasia of the **second (II) grade** of the **left hand** of the first finger and hypoplasia of the **third (IIIb) grade** of the **right hand's** first finger.

Left-hand reconstruction at 11 months old, right-hand is planned to be transplanted in 2018. Treatment applied – transposition of the *EIP* tendon. Surgery time for left hand thumb reconstruction – 0 hours for 45 minutes, inpatient spent 2 days. Assessment of post-operative results at the age of 85 months, questionnaire data: *DASH* 8.8 points, *PEDI* 67 points, *VAS(v)* 3 points, *VAS(f)* 2 points. Functional results: *Grasp dex* 0 kg, *sin(op)* 8 kg, ratio operative vs. healthy – n/a. *Pinch dex* 0 kg, *sin(op)* 2 kg, ratio operative vs. healthy – n/a. *ROM: IP(dex)* n/a, *IP(sin)* 20/0/0, *MCP(dex)* n/a, *MCP(sin)* 30/0/10, *CMC(dex)* n/a, *CMC(sin)* 10/0/5. Assessment of post-operative results at the age of 7 (see Figure 3.14).

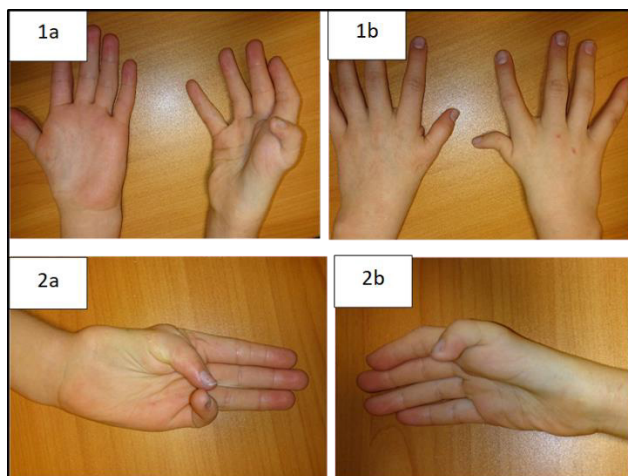


Figure 3.14. **Patient 14 post-operative images (left hand)** (author photographs)

1a – volar surface of both hands; 1b – dorsal surface of both hands; 2a – grip of the first and fifth fingers of the left hand; 2b – maximum flexion of the first finger of the right hand

3.2. Patients treated with the *NEW* method (n=2)

Patient 15. RHD. Congenital hypoplasia of **grade three (IIIb)** of the **right hand's** first finger.

Reconstruction performed at the age of 119 months. Treatment applied – transplantation of the second toe of the leg with metatarsophalangeal joint arthrosis. The surgery time – 4 hours 0 minutes, inpatient spent 5 days. Assessment of post-operative results at the age of 180 months, questionnaire data: *DASH* 8 points, *PEDI* 65 points, *VAS(v)* 1 point, *VAS(f)* 1. Functional results: *Grasp dex(op)* 30 kg, *sin* 28 kg, ratio operative vs. healthy – 1.07. *Pinch dex(op)* 1 kg, *sin* 5 kg, ratio operative vs. healthy – 0.2. *ROM: IP(dex)* 10/0/0, *IP(sin)* 50/0/0, *MCP(dex)* 90/0/5, *MCP(sin)* 80/0/10, *CMC(dex)* 10/0/0, *CMC(sin)* 20/0/10. Pre-surgical test photographs show hypoplasia of the right-hand thumb IIIb with unstable metacarpal bone and undeveloped *TMC* (trapecometacarpal) joint (1a–1b) (see Figure 3.15). Post-operative inspection at

the age of 15 years, functional and aesthetical results are good, possibly first finger flexion, extension (1a–2c and 2a). The first finger X-ray photograph shows the closed growth areas (2b), the total length of the first metacarpal bone – 48 mm. Stable *CMC* joint (see Figure 3.16).

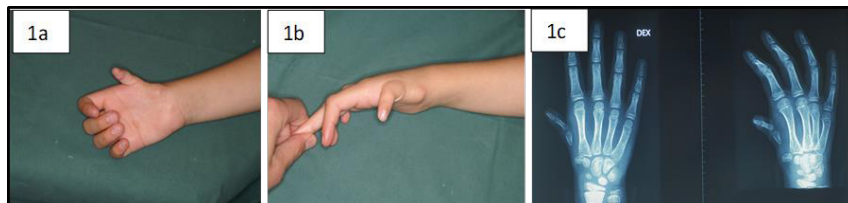

Figure 3.16. **Patient 15 pre-operative images** (author photographs)

1a – palm volar surface; 1b – lateral surface; 1c – hand X-ray

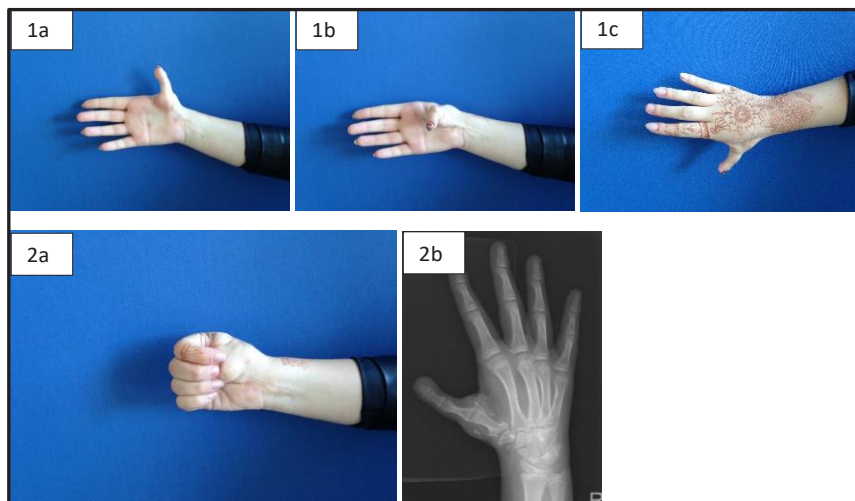


Figure 3.17. **Patient 15 post-operative images** (author photographs)

1a – Palm volar surface; 1b – newly created first finger maximum flexion in the *MCP* joint; 1c – wrist dorsal surface; 2a – palm maximum flexion; 2b – wrist X-ray

Patient 16. LHD. Congenital hypoplasia of the **third (IIIb) grade** of the **right hand** in combination with the **fourth (IV) grade radial lucidity (RDL)**.

Right hand reconstruction in two steps:

First phase. Wrist stabilisation with a rounded metatarsophalangeal joint of the second leg has been performed at the age of 37 months (*Ozols et al.* 2014, *Vilkkki* 1998.).

Second phase. A second toe transplant with metatarsophalangeal joint arthrosis reconstruction of the thumb has been performed at the age of 54 months (*Ozols et al.* 2018.).

Assessment of post-operative results at the age of 84 months. Time of surgery for right-hand thumb reconstruction – 4 hours 5 minutes, inpatient spent 6 days. Assessment of post-operative results at the age of 84 months, questionnaire data: *DASH* 10.7 points, *PEDI* 64 points, *VAS(v)* 1 point, *VAS(f)* 5 points. Functional results: *Grasp dex(op)* 2 kg, *sin* 9 kg, ratio operative vs. healthy – 0.22. *Pinch dex(op)* 0.5 kg, *sin* 3 kg, ratio operative vs. healthy – 0.16. *ROM: IP(dex)* 10/0/0, *IP(sin)* 60/0/10, *MCP(dex)* 90/0/0, *MCP(sin)* 60/0/0, *CMC(dex)* 15/0/0, *CMC(sin)* 20/0/10. Pre-operative inspection photographs (see Figure 3.18). (1a) shows hypoplasia of Grade 3b of the right-hand thumb and radial lucidity with an unstable wrist. Right wrist thumb hypoplasia grade 3b hypoplasia after wrist reconstruction phase (2a–2b). Post-operative inspection at 7 years old, functional and aesthetic results are good, possibly first finger flexion. The child managed to make a stable wrist (2a–2b) and a functional thumb (1a–1c). Donor place (2c) without functional interference, but aesthetically visible 4 fingers which form symmetry of the feet after narrowing the finger (see Figure 3.19). Bone structure of congenital hand deformation (see Figure 3.20). Pre-operative radiograph (1a), a forearm consists of one bone, after forearm reconstruction with *MTP* joint rounded transplant (1b) and post-operative result at the age of 7 (1c).

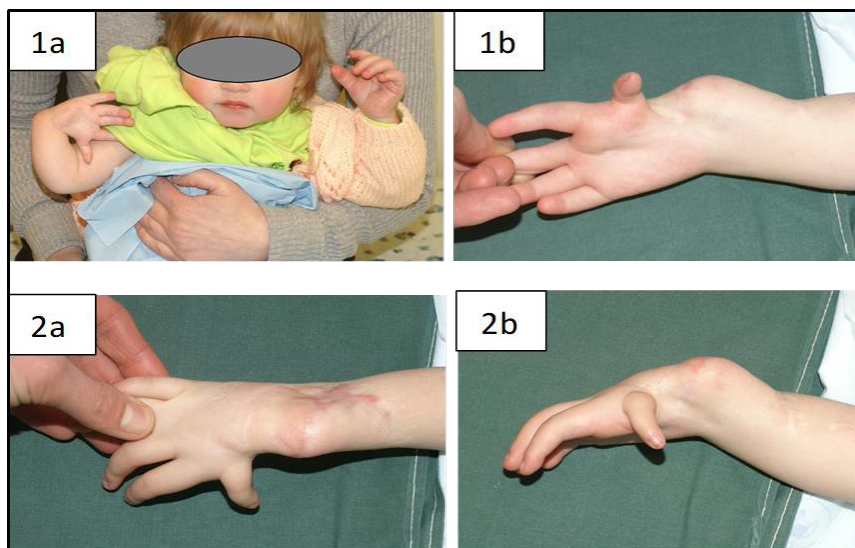


Figure 3.18. **Patient 16 pre-operative images** (author photographs)
 1a – wrist (right hand) volar surface; 1b – wrist volar surface after wrist reconstruction phase; 2a – wrist dorsal surface after joint reconstruction phase; 2b – wrist lateral surface after joint reconstruction phase

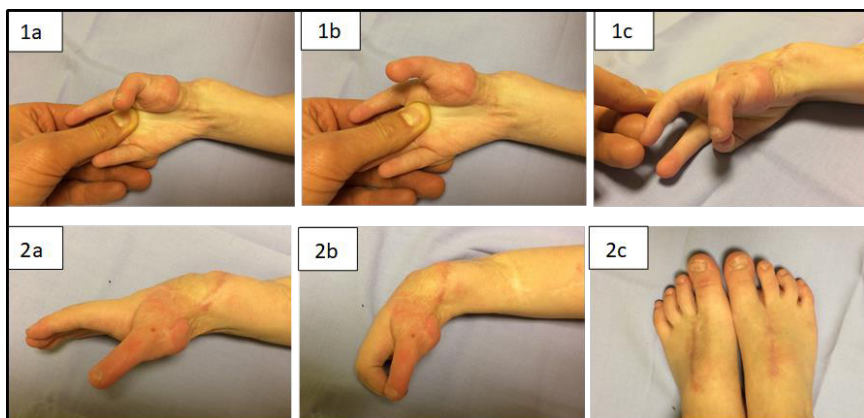


Figure 3.19. **Patient 16 post-operative images** (photographs of the author)
 1a – the maximum flexion of the newly formed first finger in the *MCP* joint; 1b – maximum extension of the newly formed first finger in the *MCP* joint; 2a – maximum flexion of the reconstructed wrist; 2b – maximum extension of the reconstructed wrist; 2c – finger donor place

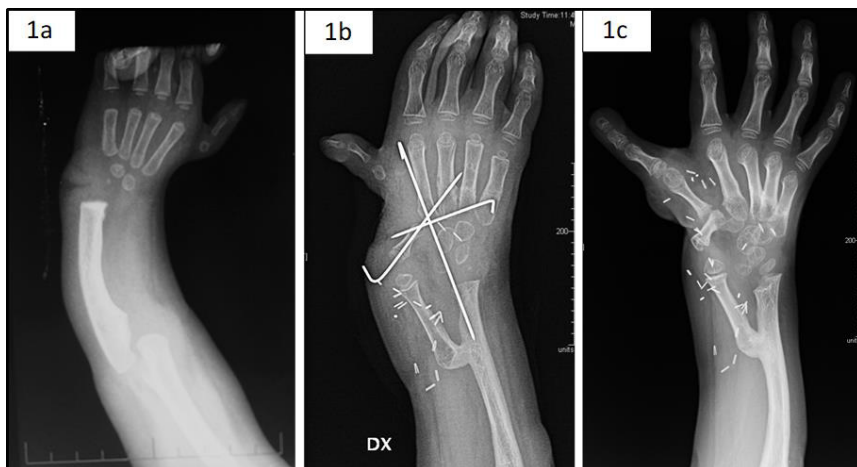


Figure 3.20. **Patient 16 radiographs**

1a – pre-operative radiograph; 1b – roentgenogram after palm reconstruction stage with a foot second finger *MTP* joint transplant (Vilkkil and Paavilainen 2018. method); 1c – roentgenogram of hand after thumb reconstruction with the new transplant method

3.3. Patients treated with pollicization method (n=2)

Patient 17. RHD. Congenital hypoplasia of the **fifth degree (V)** of the first fingers of **both hands**.

Left-hand reconstruction at 11 months old, right-hand operated at 17 months old. Treatment applied – pollicization, additional transposition of the second finger. Time of surgery for the reconstruction of the left-hand thumb – 1 hour 10 minutes, right hand – 0 hours 50 minutes, inpatient spent 2 days in both cases. Assessment of post-operative results at the age of 33 months, questionnaire data: *DASH* 26.7 points, *PEDI* 56 points, *VAS(v)* 5 points, *VAS(f)* 5 points. The questionnaire points out the patient does not like the left thumb in an opposition state. Functional results: *Grasp dex(op)* 2 kg, *sin(op)* 1 kg, ratio operative vs. healthy – n/a. *Pinch dex(op)* 5 kg and *sin(op)* 5 kg, ratio operative vs. healthy – n/a. *ROM: IP(dex)* 10/0/0, *IP(sin)* 60/0/0, *MCP(dex)* 30/0/20,

MCP(sin) 90/0/30, *CMC(dex)* 20/0/20, *CMC(sin)* 20/0/20. Assessment of post-operative results at the age of 3 years (see Figure 3.21).

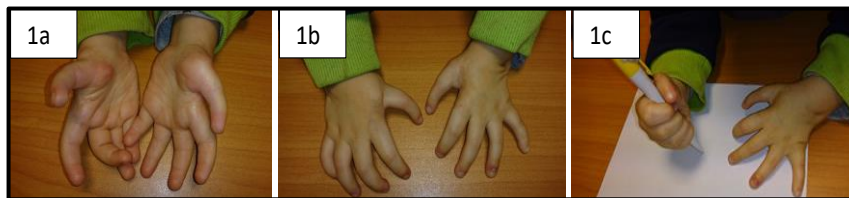

Figure 3.21. **Patient 17 post-operative images** (author photographs)
1a – Volar surfaces of both hands; 1b – dorsal surfaces of both hands; 1c – functional assessment of the first finger of the right hand

Patient 18. LHD. Congenital hypoplasia of the **fourth (IV) grade** of first finger of the **right hand**.

Right-hand reconstruction at 11 months old. Treatment applied – *pollicization*. Surgery time for right-hand thumb reconstruction – 0 hours 55 minutes, inpatient spent 2 days. Assessment of post-operative results at the age of 101 months, questionnaire data: *DASH* 6 points, *PEDI* 64 points, *VAS(v)* 3 points, *VAS(f)* 2 points. The questionnaire says the patient does not like a four-finger palm. Functional results: *Grasp dex(op)* 14 kg, *sin* 12 kg, ratio operative vs, healthy – 1.17. *Pinch dex(op)* 3 kg and *sin* 6 kg, ratio operative vs. healthy – 0.5. *ROM: IP(dex)* 85/0/0, *IP(sin)* 90/0/0, *MCP(dex)* 90/0/0, *MCP(sin)* 80/0/30, *CMC(dex)* 15/0/20, *CMC(sin)* 15/0/20. Evaluation of post-operative results at the age of 9 (see Figure 3.22).

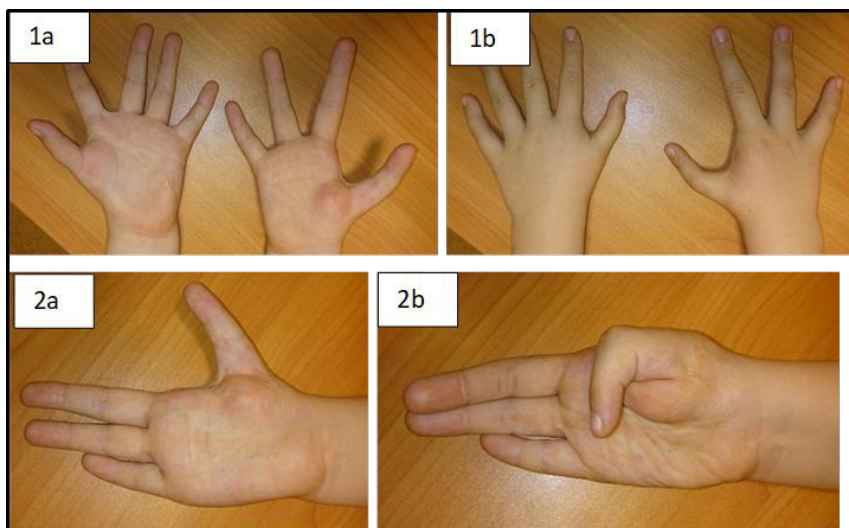


Figure 3.22. **Patient 18 post-operative images** (author photographs)
 1a – volar surfaces of both hands; 1b – dorsal surface of both hands; 2a – maximum abduction of the first finger; 2b – maximum flexion of the first finger

3.4. Retrospective analysis results

Retrospective analysis of patient data concludes that nine children underwent reconstructive surgery during the first year of life (three pollicization and six *EIP* tendon transposition). Finger transplants have been performed in children at an average of 86.5 months of age. The average child age during pollicization operations is 13 (9–17) months, *EIP* tendon transposition – 38 (11–128) months. Children have an average age of 86.5 (54–119) months when undergoing a second-toe transplant. In operational time analysis, it was concluded that the duration of the *EIP* tendon transposition operation is the shortest, on average it takes 60.71 (30–115) minutes, the duration of pollicization operation average lasting for 92 (50–160) minutes. The second toe with *MTP* joint arthrodesis transplantation takes an average of 242.5 (240–245) minutes (see Chart 3.1).

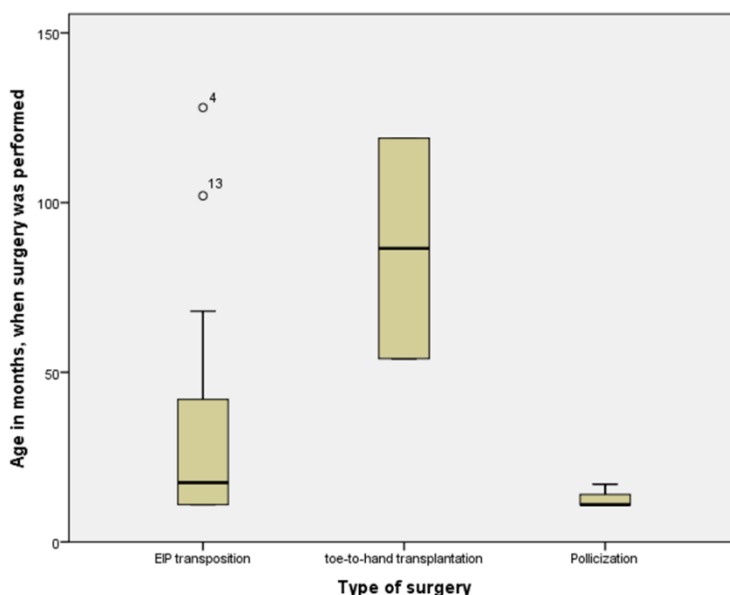


Chart 3.1. Operation types and timing

3.5. Prospective research part

3.5.1. Assessment of the complex post-operative functional results

Evaluating the results of the functional (*DASH*) and (*PEDI*) questionnaires

Average *DASH* 14.54 (0.9–56.3) for the *EIP* tendon transposition. For two patients undergoing *EIP* tendon transposition, the *DASH* score is above 50 points and 30.2 for one patient indicating poor functional outcome. Two patients have detected a thumb hypoplasia IIIa grade, a reduced metacarpal bone and a stable *CMC* joint; however, one patient has a IIIb – unstable *CMC* joint. Patients', who were undergoing a second toe-to hand with *MTP* joint arthrodesis transplantation, *DASH* is average 9.35 (8–10.7). In the pollicization group, *DASH* has an average of 19.8 (6–26.7) (see Chart 3.2).

PEDI questionnaires show better results for patients with the second-toe transplant method – 64 points (64–66), *EIP* tendon transposition patients – 62

points (52-70), while pollicization patients' functional performance following the questionnaire assessment was 60 points (56–64). Statistical processing of the results of *DASH* and *PEDI* questionnaires resulted in no statistically significant difference ($p > 0.05$) because the number of patients in the comparable groups is too small. It is possible to interpret these results according to the standards approved by the questionnaires *DASH* and *PEDI*.

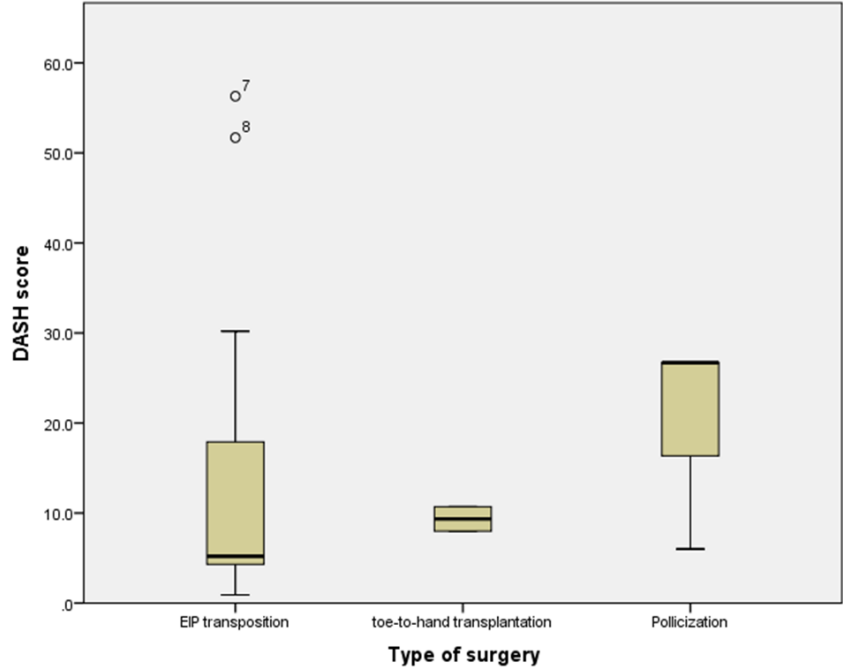


Chart 3.2. Operation types and functional evaluation

Analysis of visual analogue scales aesthetic *VAS(v)* and performance *VAS(f)*

The *VAS(v)* scale rating is measured at points 1 to 10 where fewer points correspond to a better score. The *VAS(v)* data collection shows that weaker results are in the pollicization group of patients. This assessment is related to

setting up a four-finger hand in patients following pollicization surgery. An average visual assessment of the thumb of the *EIP* transposition group is 2.85 (1–9) shows that II and IIIa grade hypoplasia thumbs are only slightly smaller than the normal arm’s thumb, and a good-looking thumb is obtained during finger stabilisation. Assessment of the toe-to hand transplant group is considered to be very good, although the second toe of the leg is significantly different from the thumb (see chart 3.3). Perhaps the high assessment is given directly by the creation of a five-finger hand, which seems essential in the eyes of patients and their parents.

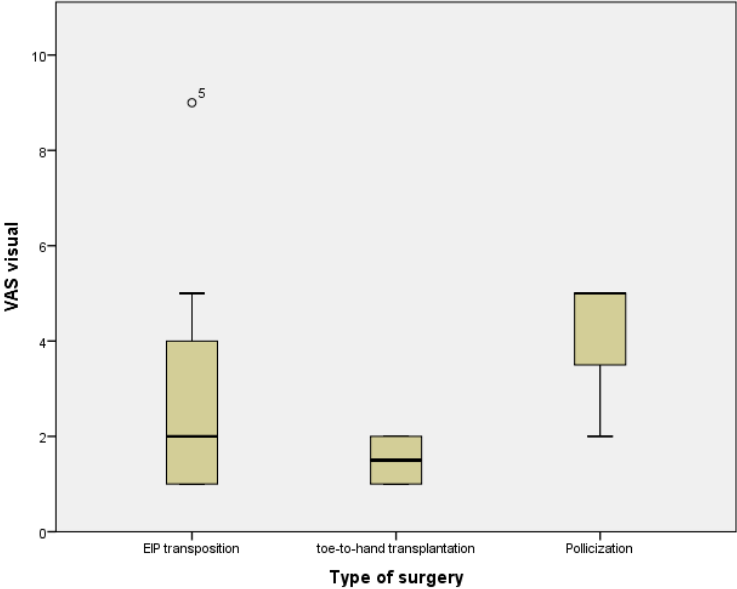


Chart 3.4. Aesthetical evaluation by patients and parents (Does reconstructed thumb looks like a thumb?)

The score of the $VAS(f)$ is measured at points 1 to 10, where fewer points correspond to a better score. The $VAS(f)$ data collection shows that the results are very similar across all patient groups. The weakest results were observed in

patients with grade IIIa hypoplasia (see Chart 3.4). The results of the visual analogue scale (*VAS (v)* and *VAS (ff)*) have not produced a statistically credible difference ($p > 0.05$) between the comparable types of surgery because the number of patients in the groups is too small.

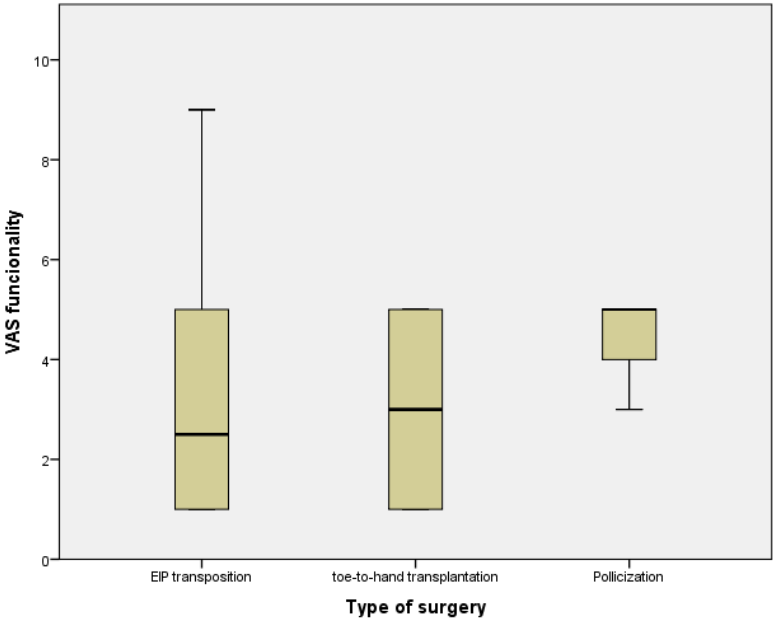


Chart 3.4. Aesthetical evaluation by patients and parents (Does reconstructed thumb works as a thumb?)

Analysis of functional data

Analysis of the functional data was performed with 9 patients aged 3 to 7 years and the results compared to the average age rate norm (see Chart 3.5). There was a statistically probable difference between the results of patient grip force and normal variant ($p = 0.018$) using *independent samples T-test*. The results suggest that surgery patients get finger and hand functionality after thumb reconstruction, which differs significantly from patients without congenital deformation. Congenital hypoplasia of the thumb is not just an isolated

deformation of the first finger, but the functionality of the other hand, specifically the radial side muscle, as well as the second and third fingers, plays an essential role in securing the grip of the hand. Comparing grasp force measurement data for the healthy and sick arm, 7 out of 18 patients were found to have better results directly for the healthy arm, the results of the operated arm were better for only two patients, respectively, following the patients with a second toe-to hand with *MTP* joint arthrodesis transplant method operation and one patient after pollicization. On the other hand, the four patients in our group had identical measurements of force grip on both hands.

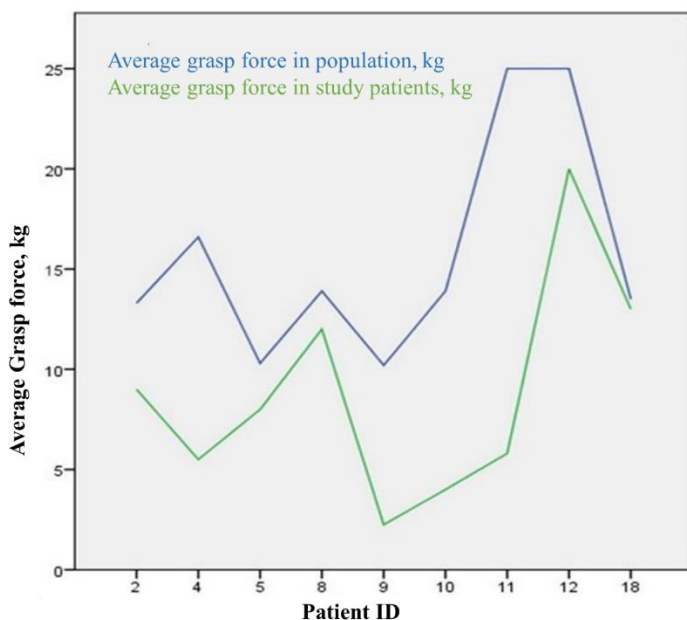


Chart 3.5. **Functional outcome**

The results of pinch force measurements for the healthy arm were better for 8 patients out of 18, only in one case force of the pinch grip was seen higher than in the healthy arm. Identical measurements of the strength of pinch in both hands were observed in four patients. Five patients could not perform a functional performance assessment, due to a thumb's hypoplasia reconstruction

in both hands. When comparing the dominant and non-dominant hand, no significant differences in pinch and grasp force results were identified. The healthy hand is superior to the sick hand, despite which one children use as the primary. The grasp and pinch is provided by multiple combinations of muscles and fingers, while hypoplasia patients are damaged not only by the thumbs structures.

3.6. Questionnaire aesthetic results

In order to assess whether *visual assessments affect the number of fingers in the hand*, a questionnaire was compiled in three languages (Latvian, Russian and English). The questionnaire is based on photographs of four (pollicization) and five (transplant) fingers palm photographs. Respondents should evaluate photographs of the foot of the hand and transplant method donor site from 1 to 10, where 10 means an outstanding result. A total of 285 questionnaire results and average assessments have been obtained: for the toe-to hand with *MTP* arthrodesis transplantation method, an average mark is 7.04 points, the pollicization method is 5.79 points and the foot of the donor site is 7.38 points (see Chart 3.6). For the toe-to hand transplant method, the lowest assessment was 3 points, while the pollicization method had only 1 point. 210 respondents (73.68 %) believe that the better aesthetic result is post-transplant, 34 (11.93 %) post-pollicization. 41 surveyed (14.39 %) think aesthetics is equally good after both surgery types (see Chart 3.7). Analysis of the data was carried out by all respondents, as well as a comparison of the assessments by the second toe-to hand with *MTP* joint arthrodesis transplantation method against assessments of the pollicization method obtained. *Paired Samples test* was used for statistical data analysis. Statistically reliable results have been obtained ($p < 0.001$) that respondents with a higher point score (7.04 points for the new method and 5.79 points for the classical method) assess the transplantation method.

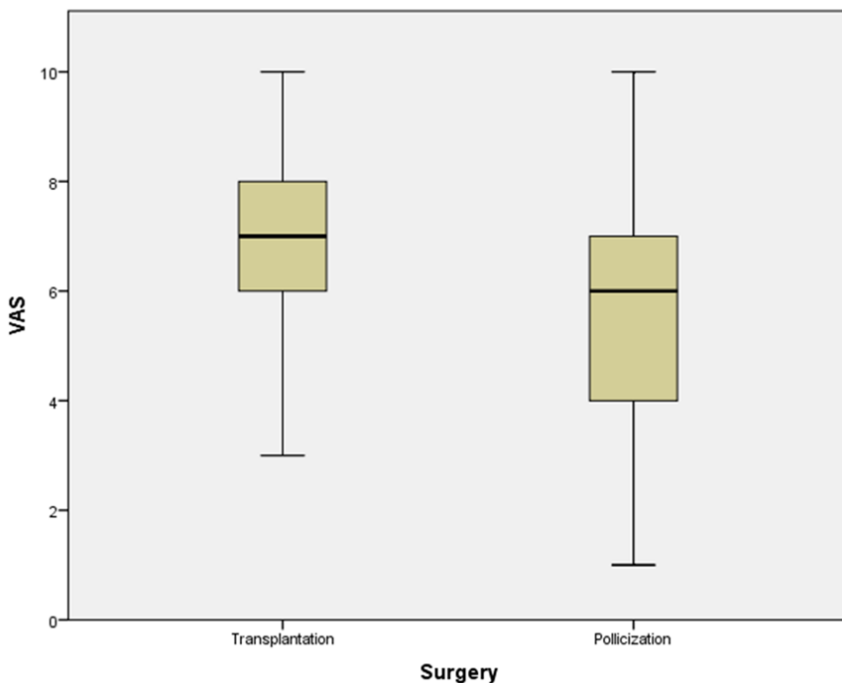


Chart 3.6. Aesthetical outcome survey results

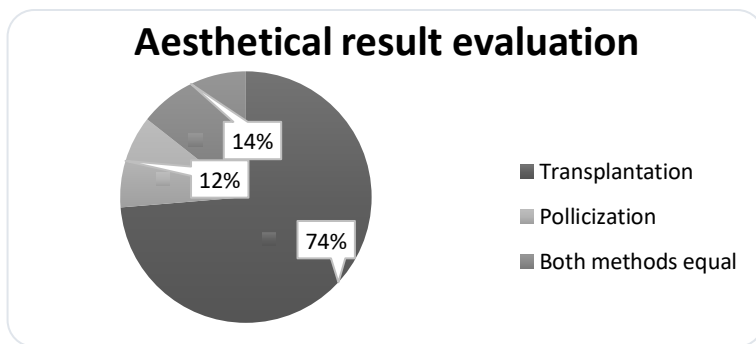


Chart 3.7. Aesthetical result evaluation after reconstructive surgeries

DISCUSSION

Congenital thumb hypoplasia is a rare disease in incidences in 2:10000 life-born newborns a year. In the Republic of Latvia, it is difficult to obtain accurate data on the deformation of the thumb because there is no unified system for the register of congenital malformations. While performing a collection of outpatient and hospital data from Riga Eastern Clinical University Hospital, Children's Clinical University Hospital and the Latvian Plastic, Reconstructive and Microsurgical Centre, it was found that the number of congenital thumb hypoplasia patients was on average 2 to 3 patients per year. In addition, combined deformations such as radial longitudinal deficiency (RLD) (1:50 000) and other complex congenital deformations are diagnosed. Second toe-metatarsal bone transplantation for congenital thumb hypoplasia surgical treatment described in 2004, when a group of Taiwanese surgeons published a series of cases in 11 treated patients undergoing a second-toe metatarsal bone transplant to reconstruct thumb [38]. Surgical method is based on the creation of a three-joint thumb, as the MTP joint is maintained by the intrinsic musculoskeletal tension, which provides stability. The functional results of the study are considered good, although the average time for toe transplantation is 8 h (6.5–12). The application time of the method developed in the microsurgery center is on average 4 h (4 – 4.05), which is more than twice as fast, as well as performing the operation on the same doctor's team. Asian people, due to cultural and religious differences, chose to preserve a five-finger hand by reconstructing a thumb with a partial unrounded or truncated fragment of metatarsal bone, because loss of a toe to these patients is unacceptable. *Chow et al.* 2012. developed method is based on non-vascularised fourth hemi-metatarsal bone transplant. The study published results for 5 patients with 6 surgical thumbs. The operation is carried out in two steps: the first phase has undergone an unrounded bone transplant and, in the second phase, a musculoskeletal reconstruction. The published results are judged

as good, although the amount of the thumb movements can only be achieved on the first *CMC* joint, growth in length is reduced. This method is also characterised by a number of complications such as graft instability, fracture. *Chow et al.* 2012. results for patients operated – strength grip on the operated arm of 6.5 kg, a margin of 10.5 kg, a difference of 4.12 or 61.9 % of the healthy arm. Their results for pinch on the operated arm was 1.25 kg and for the healthy arm was 3.25 kg, demonstrating a difference of 2.00 or 38.4 %. The results obtained are compared to the second-toe to hand transplantation with the *MTP* joint arthrodesis method developed by the MC – grip force on the operated arm – 16 kg, healthy arm 18.5 kg, vs. difference of 2.5 or 86.4 % of the healthy arm, but pinch force on the operated hand – 0.75 kg, healthy arm 4 kg, vs. difference of 3.25 kg or 18.9 % of the healthy hand. The results of both methods are comparable, but supposedly a hemi metatarsal transplant is more suitable for Asian people, because there is no loss of toes relevant to Asian cultural and religious representatives. Functionality is provided by healthy, second to fifth fingers, but in radial longitudinal deficiency (RLD) patients, the second, third and even fourth fingers are often with contractions and movement limitations. Consequently, a second toe transplant with an *MTP* joint arthrodesis method can offer better functional results. Partial fourth metatarsal bone transplant method for the reconstruction of the thumb hypoplasia IIIb has been described in separate cases [33], but the results have not been evaluated. It is stressed that one of the functions of the finger is possible – growth in length, which is significantly smaller than the other hand, and has not been evaluated in the foot of the donor. A partial metacarpal bone transplantation method is applicable for the correction of grade IIIb and IV hypoplasia, but not applicable for the adjustment of grade V (thumb aplasia patients). The method using the second *MTP* joint transplant for reconstruction of thumb hypoplasia IIIb was described by *Foucher et al.* 2001., when an overview of cases in 3 patients was published. The results of the method

are described as good, a stable thumb obtained that provides a pinch and grasp. However, functional results compared to the second-toe to hand transplantation with the *MTP* joint arthrodesis method and the method of non-vascularised second metacarpal bone transplantation are to be assessed below – a grasp of 40 % of the healthy hand and the grip of pinch of 10 % of the healthy hand. For the method developed in the microsurgical center, a grasp of 86.4 % of the whole hand and a pinch of 18.9 % of the whole hand.

Classical method of surgery in the reconstruction IIb-V of the thumb hypoplasia is pollicization or placing the second finger of the hand in the position of the first finger. Good functional results of the method and the relatively short times of the operation clearly show the choice of pollicization as the first method of reconstruction in most parts of the world. Cultural and religious aspects of keeping all fingers, whatever they may be, have contributed to the development of methods of reconstructing metatarsal bones (vascularised or non-vascularised), although the functional result for the newly formed thumb is weak, all fingers of hand and leg are maintained [5]. In a study *Tan and Tu* 2013., comparing the method of second-toe metatarsal bone transplantation with the classical pollicization method, significant differences in the time of surgery were identified – the average duration of surgery in the transplant group – 8 h (6–12), but in the pollicization group – 2.6 h (2–3.5). 80 % of the patients judged the result after finger pollicization to be very good, while in the transplant group only 60 % of the results were assessed as good. Functional results for the volume of movement were better in pollicization patients at 74° (60 to 90°) and 61° (35 to 85°) in transplant patients. Although the study does not accentuate the joint for which measurements have been performed, it can be concluded, when assessing the description of the operation and the images included in the article, the volume of movements is provided by the stabilized *MTP* joint [34, 38]. Duration of the operations of patients operating using the second toe with *MTP* joint arthrodesis

transplantation method, the surgery time – 4 h (4–4.05) but, using the pollicization method, the duration of the operation was 1.5 h (50 min–3.5 h). Aesthetic result assessment shows that the appearance of pollicization is lower. Functional results, including range of motion, transplant methods in patients were IP joint 27.5° (10 to 45 °), MCP joint 70° (50 to 90°) and CMC joint 17.5° (15 to 20°), while pollicization group – IP 51.6 ° (10 to 85 °), MCP 70 ° (30 to 90°) and CMC joint 18.3° (15 to 20°).

Use of second toe-to-hand with *MTP* joint arthrodesis makes it possible to maintain a functional five-digit hand. The aim of the study was to collect functional and aesthetic results about the treatment methods applied and to perform a comparative analysis of the data. The analysis of study data is complicated by the relatively small number of patients (18 patients over 10 years), as well as the various surgical techniques applied that break up the groups of patients. When compiling functional and aesthetic results for patients in the IIb-V hypoplasia group, it was concluded, that functional results did not differ significantly between pollicization and second toe with *MTP* joint arthrodesis transplantation groups, but patients and their parents significantly better evaluate aesthetic results in the transplant group, despite, losing a toe. Assessment of *VAS(v)* and *VAS(f)* concluded that transposition of the *EIP* tendon for reconstruction of grades IIIa and IIIb of hypoplasia do not produce good results. Possibly, in patients with IIIa, IIIb and perhaps also grade IIc deformation, one of the methods of replacement of the first finger should be selected: second-toe to hand transplantation with a metatarsophalangeal joint arthrodesis or pollicization. In evaluating the results of *VAS(v)*, it was concluded that patients in the transposition and transplantation groups had better assessment than patients in the pollicization group. The biggest difference in the groups of these patients is that pollicization patients have four-digit, and five-digit hands in transplant and transposition groups. A hypothesis was raised – the second-toe to

hand transplantation with *MTP* joint arthrodesis method for the reconstruction of grade IIIb-V hypoplasia is surgically more complex and with longer surgery and hospitalization time but provides equivalent functionality and enhances aesthetic appearance as a classical pollicization method. A questionnaire was distributed among patients in Latvia, with 285 members participating [32]. The results of the questionnaire, with a statistically trustworthy result, showed that the survey participants better assess the aesthetic results of the transplantation method. Until now, only Asian people, due to cultural and religious differences, chose to preserve a five-digit hand by reconstructing a thumb with a partially rounded fragment of metatarsal bone, because loss of a toe to these patients is also unacceptable [11]. *Goldfarb et al.* 2007. study compared the aesthetic results of pollicization with a normal thumb, putting assessment on the child's parents, a surgeon and a hand therapist. The results obtained showed that none of the created thumbs were assessed as normal. The VAS scale applied, and the results obtained were 6.6 (4.7 to 9.7) (maximum marking 10) are very similar to the results of pollicization operations carried out in the MC. The main shortcomings observed in the reconstructed thumbs: too small, too short or long the newly created first finger. However, it should be assumed that not only the newly formed thumb [12], but also the total appearance of the whole hand, namely the creation of a hand of four or five fingers, will play an important role in ensuring visual appearance. For hand functionality, the function of both the thumb and other fingers is essential, leading to the ability of a person to grasp large and small objects. Historically, the most important function has been to reconstruct the thumb to improve a patient's work capabilities, as the first finger provides up to 50 % of the hand's functionality. At least a stable, minimally functional, preferred, sensitive thumb is required to ensure hand functionality. The motility of the other fingers of the hand, third, fourth and fifth, while interacting with the thumb, gives both the grip of grasp and pinch [25]. This historical postulate was

long considered the basis for a thumb reconstruction, but the question arises whether modern people need a stable, minimally functional thumb that gives the hand the ability to grasp and hold heavy objects, creating an opportunity to work with a shovel, axe or hammer; whether there is a less agile thumb more important to modern man, but with possible movements – both flexion and extension, abduction and adduction. Perhaps, this less powerful thumb, using touch-sensing devices, mobile platforms [16] for modern day human is much more useful than a stable minimally functional thumb.

CONCLUSIONS

1. Use of the new method for second leg transplant with *MTP* joint arthrodesis provides patients with congenital hand IIIb-V hypoplasia with stable and functional thumb formation, which provides good functional results and is comparable to clinical results of the pollicization method, while ensuring the creation of a five-digit hand.
2. Surgery time of the second toe-to hand transplant with *MTP* joint arthrodesis (new) method is longer than the surgery time of the pollicization method, and the patient location time at the hospital is higher than the pollicization methods operated for patients.
3. Second toe-to hand transplant surgery with *MTP* joint arthrosis (new) method provides creation of a five-digit functional hand, providing a better aesthetic outcome than the pollicization method.
4. Achieved aesthetic look of the five-digit hand, when reconstructions are performed with the new surgical method, is better than the acquired aesthetic look of the four-digit hand, when reconstructions are performed with the classical pollicization method.
5. Reconstruction of hypoplasia at grade II and IIIa of the congenital hand deformities, using the *EIP* tendon transposition method, shall ensure the establishment of a functional thumb.
6. Post-operative functional parameters of congenital hand hypoplasia patients, regardless of the surgical method, are worse than the functional results of the hand of healthy patients.

PUBLICATIONS AND REPORTS ON THE RESEARCH TOPIC

Publications in internationally cited journals

1. Ozols D., Zarins J., Petersons A. Bilateral Second Toe Transfers To Reconstruct Radial Longitudinal Deficiency: A Case Report. *Journal of Hand Surgery (European Volume)*, 2018 Dec;43(10):1114-1116.
2. Ozols D, Zarins J, Petersons A. Novel Technique for Toe-to-Hand Transplantation: The Fourth-toe as an Alternative Option for Toe-to-Hand Transplantation for Pediatric Patients. *Techniques in hand & upper extremity surgery*. 2019 Jun 1;23(2):74-80.
3. Ozols D., Zarins J., Petersons A. Long-Term Evaluation Of The Functional And Esthetical Outcomes For The New Method Of The Toe-To-Hand Transfer For Full-Length Thumb Reconstruction In Congenital Thumb's Hypoplasia In Children. *Proceedings Of The Latvian Academy Of Sciences. Section B*. Vol. 73 2019, No.2 (719): 171-176.
4. Ozols D, Butnere MM, Petersons A. The Second Toe-to-Hand Transfer for Full-length Thumb Reconstruction in Congenital Thumb's Grade IIIb to V Hypoplasia: MTPJ Arthrodesis Instead of Tendon Rebalancing. *Techniques in hand & upper extremity surgery*. 2019 Sep.
5. Ozols D, Butnere MM, Petersons A. Methods for Congenital Thumb Hypoplasia Reconstruction. A Review of the Outcomes for Ten Years of Surgical Treatment. *Medicina*. 2019; 55(10):610.

Publications in the cited journals

1. Ozols Dz., Zarins J., Bergmanis U., Mamaja B., Petersons A. An Overview of Treatments for Congenital Longitudinal Deficiencies. *Acta Chirurgica Latviensis*. 2014; (14/2): 24-30.

Patents

1. Artificial Model Of Silicone And Polyurethane For Evaluation Of Thumb Joint Movement Activity. Number: LV15420 (A) approved on the 20.07.2019.
2. Method Of External Determination Of Dynamic Of Effectiveness Of Function Of Metacarpophalangeal Joint In Children With Contraction Of Flexor Muscle After Extended Reconstruction Of Thumb. Number: LV15388 (A) approved on the 30.03.2019.

Medical technology

1. Mediacal tehnology – The Second Toe-To Hand Transplantation With *MTP* Joint Arthrodesis Method For Full Lenght Thumb Reconstruction For Congenital Hand Hypoplasia IIIb-V Treatment has been submitted for approual in The National Health Service of the Republic of Latvia on 22.10.2018.
2. Mediacal tehnology – the Fourth Toe-To-Hand Transplantation for pediatric patients has been submitted for approval in the State Agency of Medicines of Latvia on 19.10.2019.

Clinical guidelines

Congenital Thumb Hypoplasia treatment guidelines was submitted for approval in the the Centre for Disease Prevention and Control of Latvia on 06.09.2019.

Oral presentations in international congresses

1. Ozols Dz., Pastars K., Mamaja B., Petersone S. Toe Transfer For Pediatric Patients Less Than Four Years (48 Month) Of Age. The 1st Baltic hand surgery meeting. 24. – 25. may 2010. Riga, Latvia, abstract book page 27
2. Ozols Dz., Pastars K., Mamaja B., Petersone S. Toe Transfer For Pediatric Patients Less Than Four Years (48 Month) Of Age. The 11th Conference of

- the Baltic Association of Pediatric surgeons. 12. – 14. May 2010. Tallinn, Estonia, abstract book page 16
3. Ozols Dz. Reconstruction Of Thumb Hypoplasia. World symposium on congenital malformation of the hand and upper limb. 22. – 24. March 2012. Dallas, USA, abstract book page 51
 4. Ozols Dz. Reconstruction Of Thumb Hypoplasia. 3rd Baltic Hand Surgery Meeting. 26. – 27. September 2014. Vilnius, Lithuania, abstract book page 15
 5. Ozols Dz. Reconstruction Of Thumb Hypoplasia. 10th Congress of Asian Pacific Federation of Societies for Surgery of the Hand. 2. – 4. October 2014. Kuala Lumpur, Malaysia, abstract book page 34
 6. Ozols Dz. Reconstruction Of Thumb Hypoplasia. 8th Congress of World Society for Reconstructive Microsurgery. 19. – 22. March 2015. Mumbai, India, abstract book page 21
 7. Ozols Dz., Zarins J., Petersons A. The New Operation Technique For Five Digit Hand Reconstruction For Congenital Thumb Hypoplasia's. XIV Conference Of The Baltic Association Of Paediatric Surgeons. 5. – 8. May 2016. Tartu, Estonia, abstract book page 23
 8. Ozols Dz., Zarins J., Petersons A.. The Toe To Hand Transfer For Full Length Thumb Reconstruction In Congenital Thumb Hypoplasias. 4th European Symposium on Pediatric Hand Surgery and Rehabilitation. 15. – 16. May 2017. Paris, France, abstract book page 45
 9. Ozols Dz., Rozentalberga A., Nefjodovs V., Petersons A. Toe To Hand Transfer With Metakarpophalangeal Joint Arthrodesis For Full-Length Thumb Reconstruction In Congenital Thumb Hypoplasias'S. 11th Asian Pacific Federation of Societies for Surgery of the Hand (APFSSH). 7. – 10. November 2017. Cebu, Filipinas, abstract book page 21

10. Ozols Dz. Toe To Hand Transfer For Full-Length Thumb Reconstruction In Congenital Thumb Hypoplasias. Pollicization Vs Transplantation. World Symposium of Congenital Malformations of Hand and Upper Limb. 7. – 10. March 2018. Hong Kong, China, abstract book page 49
11. Ozols Dz., Zarins J., Petersons A. The Forth-Toe As An Alternative Option For Toe-To Hand Transplantation For Pediatric Patients. The 37 Congress of the Scandinavian Association of Plastic Surgeons. 13. – 16. June 2018. Copenhagen, Denmark, abstract book page 125
12. Ozols Dz., Petersons A. Toe to hand transfer for five digit hand reconstruction in congenital thumb's hypoplasia. 14th IFSSH & 11th IFSHT Triennial Congress with combined FESSH Congress. 17. – 21. June 2019. Berlin, Germany, abstract book page 76

Poster presentation in international congresses

1. Ozols Dz., Zarins J., Mamaja B., Bergmanis U., Petersons. A. Reconstruction of Forearm Longitudinal Deficiencies. The 10th World Symposium of Congenital Malformations of the hand and Upper Limb. 7. – 9. May 2015. Rotterdam, Netherlands, abstract book page 47
2. Ozols Dz., Zarins J., Petersons A. Toe To Hand Transfer With Metatarsophalangeal Joint Arthrodesis For Full Length Thumb Reconstruction In Congenital Thumb Hypoplasia'S. Scandinavian Society for Surgery of the Hand. 31. March – 3. April 2016. Levi, Finland, abstract book page 48
3. Ozols Dz., Zarins J., Petersons A. The New Concept For The Toe To Hand Transfer For Full Length Thumb Reconstruction In Congenital Thumb Hypoplasia'S. 13th Congress of the European Federation of Societies for Microsurgery. 21.– 24.april 2016. Antalya, Turkey, abstract book page 206
4. Ozols Dz., Rozentalberga A., Petersons. A. The IV Toe As An Alternative Option For Toe To Hand Transplantation For Pediatric Patients. World

Symposium of Congenital Malformations of Hand and Upper Limb. 7. – 10. March 2018. Hong Kong, China, abstract book page 68

Oral presentations in Latvian scientific congresses

1. Ozols Dz. Reconstruction of thumb hypoplasia. Riga Stradins University 13. Scientific conference, 10. - 11. April 2014. Riga, Latvia, abstract book page 219
2. Ozols Dz. Īkšķa hipoplāzijas rekonstrukcija bērniem. 7. ikgadējā Latvijas traumatologu un ortopēdu konference, 10. May 2014. Riga, Latvia, abstract book page 24
3. Zariņš J., Tihonovs A., Ozols Dz., Krustiņš J., Kapickis M. Kājas pirkstu transplantācijas pielietojums rokas rekonstrukcijas gadījumā. 7. ikgadējā Latvijas traumatologu un ortopēdu konference, 10. May 2014. Riga, Latvia, abstract book page 20
4. Ozols Dz., Zarins J., Mamaja B., Petersons A. Treatment of Longitudinal forearm deficiencies for pediatric patients. Riga Stradins University 14th Scientific conference, 26. – 27. March 2015. Riga, Latvia, abstract book page 220
5. Ozols Dz., Zariņš J. Kājas pirksta transplantācija bērniem ar iedzimtu I pirksta hipoplāziju – jauna ķirurģijas metode pilna garuma īkšķa rekonstrukcijai. 8. ikgadējā Latvijas Traumatologu ortopēdu konference, 14. May 2016. Riga, Latvia, abstract book page 16
6. Ozols Dz., Nefjodovs V., Rozentalberga A., Petersons A. Functional and aesthetic outcome evaluation for the toe to hand transplantation, non vascular phalangeal transfer and pollicization for the congenital thumb hypoplasia. Riga Stradins University Scientific 15th conference, 6. – 7. April 2017. Riga, Latvia, abstract book page 278
7. Ozols Dz., Petersons A. Long term evaluation of the functional and esthetical outcomes for the new method of the toe-to hand transfer for full-

length thumb reconstruction in congenital thumb's hypoplasia. Riga Stradins University Scientific conference, 1. – 3. April 2019. Riga, Latvia, abstract book page 511.

Summary of scientific activities Summary of scientific activities

Activity	Qty.
Publications in internationally cited journals	5
Publications in the cited journals	1
Patents	2
Medical technology	2
Oral presentations in international congresses	12
Poster presentation in international congresses	4
Oral presentations in Latvian scientific congresses	7
Clinical guidelines	1

REFERENCES

1. Atroshi I, Gummesson C, Andersson B, Dahlgren E, Johansson A. The disabilities of the arm, shoulder and hand (DASH) outcome questionnaire: reliability and validity of the Swedish version evaluated in 176 patients. *Acta Orthopædica Scandinavica*. 2000, 71: 613-618.
2. Barakat MJ, Field J, Taylor J. The range of movement of the thumb. *Hand (N Y)*. 2013, 8: 179-182.
3. Bengard MJ, Calfee RP, Steffen JA, Goldfarb CA. Intermediate-term to long-term outcome of surgically and nonsurgically treated congenital, isolated radial head dislocation. *Journal of Hand Surgery (American Volume)*. 2012, 37: 2495-2501.
4. Bourke-Taylor H. Melbourne Assessment of Unilateral Upper Limb Function: construct validity and correlation with the Pediatric Evaluation of Disability Inventory. *Developmental Medicine & Child Neurology*. 2003, 45: 92-96.
5. Chow C, Ho P, Tse W, Hung L. Reconstruction of hypoplastic thumb using hemi-longitudinal metatarsal transfer. *Journal of Hand Surgery (European Volume)*. 2012, 37: 738-744.
6. Chung KC, Wei F-C. An outcome study of thumb reconstruction using microvascular toe transfer. *Journal of Hand Surgery (American Volume)*. 2000, 25: 651-658.
7. de Jong JP, Moran SL, Vilkkki SK. Changing paradigms in the treatment of radial club hand: microvascular joint transfer for correction of radial deviation and preservation of long-term growth. *Clinics in orthopedic surgery*. 2012, 4: 36-44.
8. Edwards EA. Anatomy of the small arteries of the foot and toes. *Acta Anatomica (Basel)*. 1960, 41: 81-96.
9. Foucher G, Medina J, Navarro R. Microsurgical reconstruction of the hypoplastic thumb, type IIIB. *Journal of reconstructive microsurgery*. 2001, 17: 9-15.
10. Gilbert A. Toe transfers for congenital hand defects. *Journal of Hand Surgery (American Volume)*. 1982, 7: 118-124.
11. Göbel SM, Shaki S, Fischer MH. The cultural number line: a review of cultural and linguistic influences on the development of number processing. *Journal of Cross-Cultural Psychology*. 2011, 42: 543-565.
12. Goldfarb CA, Deardorff V, Chia B, Meander A, Manske PR. Objective features and aesthetic outcome of pollicized digits compared with normal thumbs. *Journal of Hand Surgery (American Volume)*. 2007, 32: 1031-1036.
13. Greenberg BM, May JW, Jr. Great toe-to-hand transfer: role of the preoperative lateral arteriogram of foot. *Journal of Hand Surgery (American Volume)*. 1988, 13: 411-414.
14. Gummesson C, Atroshi I, Ekdahl C. The disabilities of the arm, shoulder and hand (DASH) outcome questionnaire: longitudinal construct validity and measuring self-rated health change after surgery. *BMC musculoskeletal disorders*. 2003, 4: 11.
15. Haley SM, Coster WJ, Kao Y-C et al. Lessons from use of the Pediatric Evaluation of Disability Inventory (PEDI): Where do we go from here? *Pediatric physical therapy*:

- the official publication of the Section on Pediatrics of the American Physical Therapy Association.* 2010, 22: 69.
- 16.Hirotaka N. Reassessing current cell phone designs: using thumb input effectively. *CHI'03 Extended Abstracts on Human Factors in Computing Systems*, ACM, 2003: 938-939.
 - 17.Jones NF, Hansen SL, Bates SJ. Toe-to-hand transfers for congenital anomalies of the hand. *Hand clinics.* 2007, 23: 129-136.
 - 18.Kay SP, Wiberg M. Toe to hand transfer in children. Part 1: technical aspects. *Journal of Hand Surgery (European Volume).* 1996, 21: 723-734.
 - 19.Katarincic J. Congenital disorders: hypoplastic thumb. *Hand surgery. Philadelphia: Lippincott Williams & Williams.* 2004: 1445-1451.
 - 20.Kim S, Fay MP, Proshan MA. Valid and Approximately Valid Confidence Intervals for Current Status Data. *arXiv preprint arXiv:1805.06488.* 2018.
 - 21.Knox V, Usen Y. Clinical review of the pediatric evaluation of disability Inventory. *British Journal of Occupational Therapy.* 2000, 63: 29-32.
 - 22.Kozin SH. Upper-extremity congenital anomalies. *Journal of Bone and Joint Surgery.* 2003, 85: 1564-1576.
 - 23.Laub Jr DR. *Congenital Anomalies of the Upper Extremity: Etiology and Management*, Springer, 2014.
 - 24.Light TR, Gaffey JL. Reconstruction of the hypoplastic thumb. *Journal of Hand Surgery (American Volume).* 2010, 35: 474-479.
 - 25.Lin HT, Kuo LC, Liu HY, Wu WL, Su FC. The three-dimensional analysis of three thumb joints coordination in activities of daily living. *Clinical Biomechanics.* 2011, 26: 371-376.
 - 26.Luc D. The DASH questionnaire and score in the evaluation of hand and wrist disorders. *Acta Orthopaedica Belgica.* 2008, 74: 81-85.
 - 27.Lutz BS, Wei F-C. Basic principles on toe-to-hand transplantation. *Chang Gung medical journal.* 2002, 25: 568-576.
 - 28.Ozols D, Butnere MM, Petersons A. The Second Toe-to-Hand Transfer for Full-length Thumb Reconstruction in Congenital Thumb's Grade IIIb to V Hypoplasia: MTPJ Arthrodesis Instead of Tendon Rebalancing. *Techniques in hand & upper extremity surgery.* 2019.
 - 29.Ozols D, Zarins J, Bergmanis U, Mamaja B, Petersons A. An Overview of Treatments for Congenital Forearm Longitudinal Deficiencies. *Acta Chirurgica Latviensis.* 2014, 14: 24-30.
 - 30.Ozols D, Zarins J, Petersons A. Bilateral second toe transfers to reconstruct radial longitudinal deficiency: a case report. *Journal of Hand Surgery (European Volume).* 2018, 43: 1114-1116.

31. Ozols D, Zarins J, Petersons A. Novel Technique for Toe-to-Hand Transplantation: The Fourth-toe as an Alternative Option for Toe-to-Hand Transplantation for Pediatric Patients. *Techniques in hand & upper extremity surgery*. 2019, 23: 74-80.
32. Ozols D, Zariņš J, Pētersons A. Long-Term Evaluation of The Functional and Esthetical Outcomes for The New Method of The Toe-To-Hand Transfer for Full-Length Thumb Reconstruction in Congenital Thumb's Hypoplasia in Children. *Proceedings of the Latvian Academy of Sciences. Section B. Natural, Exact, and Applied Sciences.*, Sciendo, 2019, Vol. 73: 171-176.
33. Schneider W, Reichert B, Pallua N, Meyer H. Correction of hypoplastic thumb by free transfer of metatarsal bone: a case report. *Microsurgery*. 1993, 14: 468-471.
34. Smith P, Sivakumar B, Hall R, Fleming A. Blauth II thumb hypoplasia: a management algorithm for the unstable metacarpophalangeal joint. *Journal of Hand Surgery (European Volume)*. 2012, 37: 745-750.
35. Tan J, Tu Y-K. Comparative study of outcomes between pollicization and microsurgical second toe-metatarsal bone transfer for congenital radial deficiency with hypoplastic thumb. *Journal of reconstructive microsurgery*. 2013, 29: 587-592.
36. Tonkin M. Surgical reconstruction of congenital thumb hypoplasia. *Indian Journal of Plastic Surgery: Official Publication of the Association of Plastic Surgeons of India*. 2011, 44: 253-265.
37. Tonkin MA, Tolerton SK, Quick TJ et al. Classification of congenital anomalies of the hand and upper limb: development and assessment of a new system. *Journal of Hand Surgery (American Volume)*. 2013, 38: 1845-1853.
38. Tu YK, Yeh WL, Sananpanich K et al. Microsurgical second toe-metatarsal bone transfer for reconstructing congenital radial deficiency with hypoplastic thumb. *Journal of reconstructive microsurgery*. 2004, 20: 215-225.
39. Vilkki SK. Distraction and microvascular epiphysis transfer for radial club hand. *Journal of Hand Surgery (European Volume)*. 1998, 23: 445-452.
40. Vilkki SK. Vascularized joint transfer for radial club hand. *Techniques in hand & upper extremity surgery*. 1998, 2: 126-137.
41. Vilkki SK. Vascularized metatarsophalangeal joint transfer for radial hypoplasia. *Seminars in plastic surgery*, © Thieme Medical Publishers, 2008, Vol. 22: 195-212.
42. Vilkki SK, Kotkansalo T. Present technique and long-term results of toe-to-antebrachial stump transplantation. *Journal of Plastic, Reconstructive & Aesthetic Surgery*. 2007, 60: 835-848.
43. Vilkki SK, Paavilainen P. Vascularized second metatarsophalangeal joint transfer for radial deficiency - an update. *Journal of Hand Surgery (European Volume)*. 2018, 43: 907-918.
44. Waljee JF, Chung KC. Toe-to-hand transfer: evolving indications and relevant outcomes. *The Journal of hand surgery*. 2013, 38: 1431-1434.

ACKNOWLEDGEMENTS

I want to thank my supervisor Professors Aigars Pētersons for interest and support in my research. He relentlessly, but kindly, helped me to push ahead with this work and his experience and assistance in practical matters have been most helpful.

I am deeply grateful to my colleagues especially to doctor Martins Kapickis who allowed to develop congenital hand deformity treatment in Microsurgery center and to doctor Kalvis Pastars who was assisting surgeon in first pediatric toe-to hand transplantation operation in Latvia. Special thanks to doctor Janis Zariņš for great scientific drawings and unselfish help in operation theater.

I express my warmest gratitude to anesthesiology team especially to Professor Biruta Mamaja and Jurijs Vjugins for letting to achieve good surgical outcome for pediatric patients. I am also grateful to the nurses and nurse assistants in microsurgery center, they have diligently carried out all requests regardless of the hectic workload of their own.

I would express the deepest gratitude to my parents and brothers for understanding and Special thanks to an oldest brother Girts Ozols who encouraged me to become a medical doctor.

The biggest thanks to my beloved family for patience and understanding.

Thank you very much to all others who were not mentioned but whose help were important to bring this work to the end.