



Ģirts Šalms

INTEGRATION OF BONE
SUBSTITUTING BIOMATERIALS
IN ATROPHIC
POSTERIOR MAXILLA

Summary of the Doctoral Thesis

Speciality – Oral and Maxillofacial Surgery

Scientific supervisors:

Dr. habil. med., Professor **Māra Pilmane**

Dr. habil. med., Professor **Andrejs Skaģers**

Riga, 2013

Doctoral dissertation developed in Rīga Stradiņš University

Scientific supervisors:

Dr. habil. med., Professor **Māra Pilmane**,
Rīga Stradiņš University (Latvia)

Dr. habil. med., Professor **Andrejs Skaģers**,
Rīga Stradiņš University (Latvia)

Official reviewers:

Dr. med., Professor **Ilze Akota**,
Rīga Stradiņš University (Latvia)

Dr. sc. ing., Assistant Professor **Dagnija Loča**,
Rīga Technical University (Latvia)

Dr. habil. med., Professor **Ričardas Kubilius**,
Lithuanian University of Health Sciences (Lithuania)

Doctoral dissertation defence will occur on 21st of October 2013 15.30 in the Lecture theatre Hippocrates of Rīga Stradiņš University at the Medicine Promotion Council in Riga, 16 Dzirciema Street.

Scientific thesis is available in RSU library and RSU home page: www.rsu.lv

Secretary of the Promotion Council:

Dr. habil. med., Professor **Ingrīda Čēma**

ABSTRACT

In order to assess the integration of porous bioceramic bone substitutes into the posterior edentulous atrophic maxilla after maxillary sinus floor augmentation surgical procedures, a dental cone beam computed tomographic scanning of implantation area was performed, before and after integration of the biomaterial, in order to determine the radiodensity; as well as a morphological and immunohistochemical examination of residual alveolar ridge and bone/biomaterial hybrid. A database of patient examinations, treatments and post-operative observations was developed for registration purposes and for computerized analysis of the patients' survey. The questionnaire study included 148 *sinus lift* patients with 294 dental implants. CB computed scans of 24 patients were analyzed before the implantation of the bone substitute biomaterials and 6-8 months after the surgeries. A histological and immunohistochemical examination of bone trepan biopsy was performed on 17 patients before biomaterial grafting and on 14 patients after *sinus lift* surgical procedure.

When analysing the questionnaire results of 148 patients, an insignificant number of post-operative complications (1%) was observed, as well as the loss of dental implants (4%).

Cone beam radiographic densitometry of grafting site showed radiodensitometrically denser *sinus lift* site when compared to residual alveolar bone area, where radiodensitometric density has increased during this period, however this increase was not statistically significant.

Biomaterial/tissue hybrid grafts in majority of cases six to eight months after grafts show biomaterial osseointegration without inflammation and connective tissue proliferation. The amount of bone morphogenetic protein, transforming growth factor beta, bone extracellular matrix proteins osteopontin

and osteocalcin, degrading enzyme metalloproteinase 9, heat shock protein 70, antimicrobial protein defensin containing structures in trepan-biopsy samples before grafting and after *sinus lift* show no statistically significant differences. The amount of osteoprotegerin-containing structures in grafts after biomaterial placement was statistically significantly higher than in atrophic alveolar ridge before the surgical procedure. The relative frequency of apoptotic cells in grafts shows large individual variations without any statistical significance before and after grafting.

CONTENT

List of abbreviations	6
1. Introduction	7
1.1. Aim of the study	8
1.2. Objectives.....	8
1.3. Hypothesis.....	10
1.4. Scientific novelty	10
1.5. Structure and volume of the paper.....	11
2. Materials and Methods	12
2.1. Bone substituting biomaterials employed in the study	12
2.2. Morphological study	14
2.3. Radiologic examination using cone beam computed tomographic scanning	16
2.4. Patients' survey	18
2.5. Statistical methods for processing of data.....	20
3. Results	21
3.1. Results of morphological examination	21
3.2. Results of radiologic examination	32
3.3. Patients' survey results	35
4. Discussion	38
4.1. Morphological changes	38
4.2. CT data analysis.....	46
4.3. Patients' survey data analysis	48
5. Conclusions	53
6. Research publications and reports	55
6.1 Scientific research papers.....	55
6.2 Research abstracts.....	56
6.3 Congress and conference reports.....	59
7. Acknowledgments	62
8. Annexes	63

LIST OF ABBREVIATIONS

Abbreviation	Explanation in English
BMP	bone morphogenetic protein
BMP2/4	bone morphogenetic protein 2/4
CBCT	cone beam computer tomography
DF	defensin
HSP	heat shock protein
HAp	hydroxyapatite
ECM	extracellular matrix
GF	growth factor
MDCT	medical device computer tomography
MMP	matrix metalloproteinase
MMP9	matrix metalloproteinase 9
OC	osteocalcin
OP	osteopontin
OPG	osteoprotegerin
p	statistical significance
TGFβ	transforming growth factor β
TUNEL	terminal deoxynucleotidyl transferase – mediated dntp nick – end labeling
Voxel	volumetric picture element
3D CT	three dimensional computer tomography
CT	computer tomography
DPBB	deproteinated particulated bovine bone

1. INTRODUCTION

From the beginnings of modern dental implantology to the present day, residual alveolar ridge having sufficient size and quality is a crucial condition for successful osseointegration of dental implants and for long-lasting results. Usually it is sufficient in mandible, in its anterior part, while significant challenges arise in maxilla, especially in its posterior part where the size and the quality of alveolar bone is unsuitable for dental implants due to bone atrophy from the intraoral side of alveolar ridge and expansion of maxillary sinus from the top in cases of prolonged edentulousness. Improvement of these bone parameters is a topical prerequisite for successful dental implantation in posterior atrophic maxilla. There are several proposals for stable implant-based prosthetic rehabilitation of posterior atrophic maxilla. These proposals include the use of short implants osseointegrated in residual bone (Bruggenkate, 1998; Renouard, 2005; Romeo, 2006; Anitua, 2008), the support of the implant inserted in anterior maxilla for support of prosthesis covering side and posterior part of maxilla (Krekmanov, 2000; Aparicio, 2000), implants osseointegrated in zygoma (Hirsch, 2004; Kahnberg, 2007) and the elevation of maxillary sinus floor using autobone grafting, the use of allografts, xenografts and bone substituting biomaterials, as well as the combination of the above materials. (Boyne, 1986). Numerous proposals regarding selection of patients, treatment protocols, surgical technology and bone substitute materials indicate the lack of the ideal method and material. One of the most topical issues related to this multi-factor problem is the selection of optimal bone substituting materials and clinical approbation thereof which is the key focus of the present thesis. Various commercially manufactured allogenic and xenogenic bone substituting materials of different origins are available nowadays. The priority material of our study was hydroxyapatite – synthetically created key mineral component of

bone whose (including the material developed by Rudolfs Cimdins Riga Biomaterials Innovation and Development Centre of Riga Technical University) biocompatibility, osteoconduction and osteoinduction have been experimentally proved *in vitro* (Pelšs, 2007) and *in vivo* (Šalms, 2007), as well as in clinical trials. Data on maxillary sinus floor elevation, late clinical data of dental implantation, i.e. at least after three years long post-surgical and implant-loading period, as well as diagnostic imaging, routine morphology and immunohistochemistry data within six to eight months after maxillary sinus floor elevation have been collected and analyzed in the present study.

1.1. Aim of the study

The aim of the study is to evaluate and to analyze integration of commercially available natural and synthetic HAp materials, as well as the synthetic porous HAp bioceramic material developed by Rudolfs Cimdins Riga Biomaterial Innovation and Development Centre of RTU into atrophic edentulous posterior maxilla, by collecting data on late survival of dental implants, as well as data of morphological and radiological examinations.

1.2. Objectives

In order to achieve the aim defined the following objectives were proposed:

1. To develop a database of patients after posterior maxillary sinus lift surgeries for assessment of treatment methods applied and materials used.

2. To carry out patients' survey using the database and to assess treatment outcomes of minimum three year period after biomaterial grafting by processing patients' responses to 10 questions of the questionnaire.

3. To investigate density of residual bone and maxillary sinus bone/biomaterial hybrid before and after biomaterial grafting in maxillary sinus floor though radiodensitometric analysis of data of cone beam computed tomography.

4. To perform morphological and immunohistochemical examination of residual alveolar ridge and bone/biomaterial hybrid before and after insertion of the biomaterial into maxillary sinus floor:

4.1. When using the immunohistochemical method, to identify the amount of growth factors TGF β and BMP2/4 containing structures in posterior maxilla before and after biomaterial grafting;

4.2. When using the TUNEL method, to determine the frequency of apoptosis in posterior maxilla before and after biomaterial grafting;

4.3. When using the immunohistochemical method, to identify the amount of tissue-developed protein OPG, OC, OP and HSP containing osteocytes in posterior maxilla of patients before and after biomaterial grafting.

4.4. When using the immunohistochemical method, to identify the amount of antimicrobial peptide (DF) and cell-based enzyme MMP9 containing osteocytes in posterior maxilla of patients before and after biomaterial grafting.

1.3. Hypothesis

1. Elevation of maxillary sinus cavity using calcium phosphate bioceramic materials leads to activation of regeneration of atrophic residual alveolar bone.

2. Implantation of calcium phosphate bioceramic granules into maxillary sinus floor leads not only to the increasing of alveolar ridge, but also to the remineralisation of atrophic alveolar bone with decreased mineral density.

3. Computerized registration of patients and data analysis after maxillary sinus floor lift using different bone substituting biomaterials and subsequent dental implant implantation can multidimensionally reflect outcomes of the treatment.

1.4. Scientific novelty

1. The developed computerized database and its application for registration purposes of survey data of patients who have undergone sinus lifts and dental implants, showed high (96%) osseointegration of dental implants in atrophic posterior maxilla and low incidence of complications (1%) without statistically significant differences between biomaterials used for maxillary sinus floor elevation.

2. The cone beam computed tomography method-based examination of sizes and radiodensity of atrophic posterior maxilla before and after sinus lift with calcium phosphate biomaterial grafting helps to achieve more accurate planning of surgical procedure and the use of a biomaterial, dynamic assessment of the osseointegration of the dental implants and the grafted site where the increase of radiodensity in atrophic alveolar bone was observed.

3. The assessment of immunohistochemical regeneration and cell degradation factors, as well as apoptosis in atrophic maxillary alveolar bone and in biomaterial/living tissue hybrid before and after implantation of calcium phosphate biomaterials in maxillary sinus floor has similar activity of the defined factor, which confirms similarity of the cell functional morphology, but as for osteoprotegerin, a statistically significant increase of its expression in atrophic alveolar bone, which suggests inhibition of osteoclastic activities.

1.5. Structure and volume of the thesis

This thesis has been written in Latvian. It consists of 14 chapters: introduction, literature review, materials and methods, results, discussions, summary, conclusions, bibliography, list of publications and annexes. Total volume of the study covers 169 pages including 16 tables and 39 figures, 47 microphotographs and 5 annexes. The bibliography consists of 294 publications.

2. MATERIALS AND METHODS

In order to assess integration of bone substituting biomaterials in atrophic posterior maxilla, several different and complementary methods have been applied: morphological examination of bone biopsy, patient's jaw bone radiological investigation using cone beam computed tomography method and patients' survey. In all three sections of the study, there were used patients who wanted dental implants in atrophic maxillary sinus cavity to be performed at Oral and Maxillofacial Surgery Clinic of Institute of Dentistry of Riga Stradins University. The morphological and radiologic research comprised of patients who have undergone surgical treatment performed by Ģirts Šalms from 2008 through 2010, while the survey group was comprised of patients surgically treated by all surgeons of the clinic from 2001 though 2006. Morphological and radiologic data of the study were not compared mutually as maxillary sinus lift surgeries were not performed to the same patients. Patients were entered into the study without any evaluation of their underlying conditions or harmful habits such as smoking.


2.1. Bone substitutes biomaterials employed in the study

During the study, various bone substituting biomaterials were implanted in patients. Bio-Oss® is bovine inorganic bone matrix manufactured by Geistlich (Switzerland). In the process of manufacturing of the above material, the organic part of bone is completely eliminated, leaving micropores and nanopores between hydroxyapatite crystals. Bio-Oss® morphologically, chemically and ultrastructurally is very similar to human bone. The material is

available in 0.5–1.0 mm and 1.0–2.0 mm granules. The porosity of the above material is 80 m²/g. Algipore (FRIOS, Germany) is hydroxyapatite manufactured from naturally available calcined seaweed. It is produced from seaweed-containing calcium carbonate in the presence of ammonium phosphate at 700°C to ensure retention of algae porous structure. Algipore is manufactured as 0.3 – 2.0 mm granules having 5–10 µm pores. Tutodent (Tutogen, Germany) is slowly absorbing animal-origin natural material derived from bovine. In the specific manufacturing process, non-cellular bone matrix is created consisting of bio calcium hydroxyapatite and collagen of the first type. Tutodent[®] is available in 0.25–1 mm or 1–2 mm granules. Bone Ceramic (Straumann, Switzerland) is biphasic material consisting of 60% HAP and 40% TCP. It is manufactured in 0.4–1.0 mm granules. Total porosity of Bone Ceramic is 90%, sizes of pores are 100-500 µm and they are interconnected. Cerasorb (Curasan, Germany) is synthetic β TCP bone substituting biomaterial having interconnected 5 µm – 500 µm pores; its total porosity is 65%. The above granules have irregular polygonal shape. Cerasorb granules are manufactured in the following sizes: 150 – 500 µm, 500 – 1000 µm, 1000 – 2000 µm.

a)

b)



**Figure 2.1. SEM microphotographs of HAP granules:
a) a granule, x100; b) surface of a granule, x1000**

HAp ceramic granules (0,5 – 1,0 mm) is synthesized by Rudolfs Cimdinis Riga Biomaterial Innovation and Development Centre of RTU. There are few open channels on the surface of this material. Its bulk density is high therefore the porosity is relatively low 40–50%.

Typical properties of Hap granules are differently shaped edges and faces that have been formed in the result of deviation (Figure 2.1.).

2.2. Morphological study

The morphological study group comprised of patients whose surgery was planned in two stages: the first stage consisted of implantation of a bone substituting material and obtaining of trepan-biopsy material from residual bone; the second stage involved obtaining of trepan-biopsy material from residual bone and bone hybrid site and dental implant placement after 6–8 months. Bone histological preparations of 17 patients were analyzed before biomaterial grafting, while after grafting we analyzed bone histological preparations of 14 patients. Due to insufficient bone volume after biomaterial grafting we were able to harvest biopsies from only 14 patients of the study.

The average age of the patients was 51.1 years ($SD\pm 9,09$). This group consisted of nine females and eight males.

The average age of patients of the post-implantation group was 51.5 years ($SD\pm 7.5$). This group consisted of five males and nine females.

In the morphological study, types of the implanted biomaterials divided as follows: Bio-Oss – in 10 patients, RTU HAp – in 1 patient, Tutodent – in 3 patients.

Surgical technique: mucoperiosteal flap was created enabling access to the lateral wall of the maxillary sinus cavity. Then, using a diamond drill, we created a 5 mm x 10 mm opening in the bone, removed the anterior wall of the

bone hole, raised the Schneider membrane using sinus curets both buccally and palatally, approximately 15 mm from the edge of the maxilla margin. The biomaterial was mixed with the patient's blood in ratio 2:1 in order to achieve granular agglutination. The mixture was inserted into the maxillary sinus cavity, avoiding contact with saliva. Maxillary sinus cavity was densely filled with the material, without pressing it. The anterior sinus wall was closed with collagen membrane and 4 titanium nails. The wound was closed with Vicryl 4-0 suture.

Approximately 6-8 months after biomaterial grafting, the patient came in for insertion of dental implants in his/her maxilla.

The access to alveolar ridge bone was created by lifting muco-periosteal flap. The bone/biomaterial hybrid biopsy material was harvested using 2 mm diameter trepan drill. The preparation was immediately fixed in Stefanini solution.

Then 3-4 μm sections were prepared from jaw tissue samples, staining them with haematoxylin and eosin for light microscopy, and the biotin-streptavidin method was used for immunohistochemical detection of TGF β , BMP2 / 4, defensin, HSP, OC, OP, OPG and MMP2. Cell apoptosis was assessed using the TUNEL method.

Semi-quantitative counting method – which is widely described in the literature (Pilmane, 1998; Knabe, 2005) – was used for quantification of relative frequency of immunohistochemically detected tissue degrading enzyme, antimicrobial protein, heat shock protein, growth factors, bone extracellular matrix protein and apoptosis. Relative frequency of the defined factors was analyzed in three visual fields of a single section. The diameter of the visual field was 1.8 mm when the enlargement was 100x, or the diameter the visual field was 0.9 mm when the enlargement was 200x. Symbols used are listed in Table 2.1.

Table 2.1.

Semi-quantitative assessment of immunohistochemically detected growth factors, bone extracellular matrix proteins and degeneration enzymes

Symbol	Description
-	No positive structures found in the visual field
0/+	Rare positive structures in the visual field
+	Few positive structures in the visual field
++	Moderate number of positive structures in the visual field
+++	Numerous positive structures in the visual field
++++	A lot of positive structures in the visual field

In order to process the data statistically, the cell quantity observed in the visual field of microscope was coded:

- (0) – no positive structures seen in the visual field,
- (1) – rare positive structures in the visual field,
- (2) – few positive structures in the visual field,
- (3) – moderate number of positive structures in the visual field,
- (4) – numerous positive structures in the visual field,
- (5) – a lot of positive structures in the visual field.

2.3. Radiologic examination using cone beam computed tomographic scanning (CBCT)

Only one of the biomaterials – Bio-Oss – was placed in maxillary sinus floor of patients of this group. We analyzed cone beam CT scans of 24 patients before implantation of bone substituting biomaterials and six to eight months after the surgical procedure. The height of alveolar ridge bone in

patients before biomaterial grafting did not exceed 5 mm vertically. After insertion of the biomaterial, the height of alveolar ridge lifted by an average of 7-10 mm, on the expense of maxillary sinus cavity, achieving 12-17 mm newly formed bone/biomaterial hybrid for insertion of dental implants. The average age of the patients was 48.42 years ($SD \pm 7,47$). The oldest patient was 64, the youngest one was 34. The study included 16 females and 8 males.

Cone beam CT equipment of the Institute Dentistry of RSU – ICAT® Immaging Sciences Next Generation, USA – was used for this research. Scans were obtained using 0.3 voxel (3D image volume element) size, using CBCT reconstruction algorithm (ExamVision Program (I-CAT Next Generation, USA)). The field of the measured bone density was 0.5 mm², and measurements were all performed in coronal view, however, in order to obtain reproducible measurements, each implant, before and after biomaterial grafting, was aligned into perpendicular position to the sagittal plane, which was perpendicular from central incisor to the midpoint of biomaterial insertion site. Buccal and palatal measurements of residual bone were made before insertion of the biomaterial, while repeated measurements six to eight months after the insertion of the biomaterial were made in coronal view in the same buccal and palatal site of residual bone as well as in buccal and palatal bone hybrid (Fig. 2.2.). The obtained measurements were registered in Hounsfield unites (HU) and grouped in MS Excel table, then they were statistically processed.

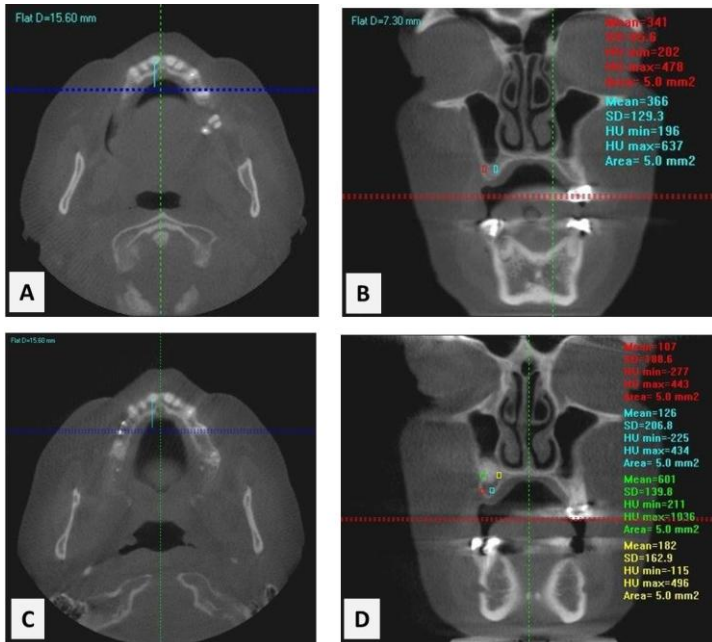


Fig. 2.2. CBCT images of *sinus lift* site measurements in horizontal and coronal incisions before and after *sinus lift* surgery

- a) determination of the measurement site in the sagittal plane before implantation of the biomaterial; b) residual alveolar bone in coronal plane before implantation of the biomaterial; c) determination of the measurement site in the sagittal plane after implantation of the biomaterial; d) residual alveolar bone and bone hybrid 8 months after implantation of the biomaterial in the coronal plane

2.4. Patients' survey

Our questionnaires comprising of 10 questions (see in Annex) were forwarded to 250 patients of Oral and Maxillofacial Clinic of Institute of Dentistry of RSU who, during the period from 2001 to 2006, had undergone maxillary sinus floor lift surgical procedures involving the use of a biomaterial

followed by dental implantation. Information on the type of a biomaterial placed, the surgically treated site and the length, diameter and system of the inserted dental implants was obtained from outpatient records and operation journals. The obtained information was entered into a specially created data base program. The study included all patients who have had maxillary sinus lift surgeries, including those patients with underlying conditions, periodontal pathologies and smokers. In the view of evidence available in literature on the effect of smoking on implant survival, all patients were warned about the risks if they continue smoking.

In the questionnaire, patients were asked about their satisfaction with the treatment, complications, implant loses, prostheses and stability of implant, as well as frequencies of their dental hygiene visits.

Answers to the questions of the questionnaire were received from 148 patients – from 91 (61.5%) females and 57 (38.5%) males. The average age of the respondents was 52.7 years (SD \pm 10.17). The youngest patient was 31 and the oldest one was 74. Total of 294 dental implants were implanted in 148 patients.

Algipore granules as a bone substitute were used in 71 patient (48%), HAp granules synthesized by RTU were used in 45 patients (30%), Bone Ceramic granules – in 16 patients (11%), Bio-Oss – in 12 patients (8%) and Cerasorb granules – in 4 patients (3%) (Fig. 2.3.)

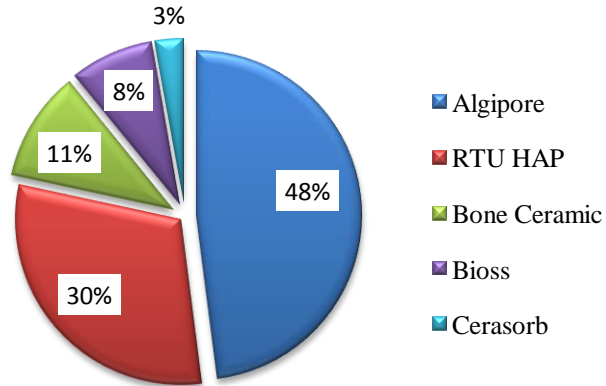


Fig. 2.3. Implanted bone substituting materials

2.5. Statistical methods for processing of data

MS Excel data analysis program was used to process survey data collected from patients' questionnaires, morphology and radiology. The minimum and the maximum measurements, as well as the standard deviation were measured by the above program.

Materiality (significance) level $p \leq 0.1$ for morphology and $p \leq 0.05$ for radiology and patients' survey was used to reject the null hypothesis and to accept alternative hypothesis. Ranks were used for semi-quantitative assessment of parameters.

Correlation analysis – Spearman's rank correlation coefficient r_s – was used for inter-comparison of two or more variables. Correlation was negative when $r_s = -1-0$, it was weak when $r_s = 0.2-0.5$, medium close correlation was when $r_s = 0.5-0.8$, and close correlation between factors was when $r_s > 0.8$ (Teibe, 2001).

3. RESULTS

3.1. Results of morphological examination

Pre-grafting analysis of samples of patients' alveolar ridge and sinus lift area biopsies in routine histological staining with haematoxylin and eosin showed age-appropriate histology findings with no explicit changes in bone structures.

In most patients' histological sample, we found integration of a biomaterial in patient's maxillary sinus floor without infiltration of inflammatory cells within six and eight months after biomaterial grafting. In some cases, uneven bone mineralization, as well as obliteration of osteon channels and proliferation of connective tissue was found around biomaterial in patient's bone after biomaterial grafting in the bone structure. Irregular ingrowths of connective tissue and sclerotisation of blood vessels were observed in osteon channels. After implantation of the biomaterial Tutodent, we found an explicit ingrowths of connective tissue between the biomaterial and bone.

BMP2/4-containing cells in alveolar bone were observed both before and after implantation of different bone substituting biomaterials (Fig. 3.1.)

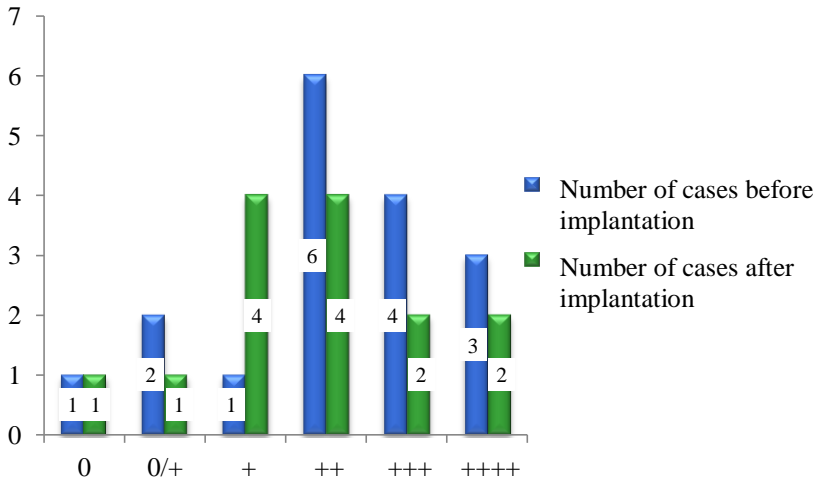


Fig. 3.1. Relative frequency of BMP2/4-containing cells in *sinus lift* area before and after biomaterial grafting

0 - no positive structures found in the visual field; 0/+ rare positive structures in the visual field; + few positive structures in the visual field; ++ moderate number of positive structures in the visual field; +++ numerous positive structures in the visual field; ++++ a lot of positive structures in the visual field

The mean number of BMP2/4-containing cells was 2.20 ± 1.19 before biomaterial grafting and 1.89 ± 1.24 after biomaterial grafting. Changes in the number of BMP2/4-factor containing cells was statistically insignificant ($p=0.452$). After assessment of the number of BMP2/4-containing cells in patients of different sex, no statistically significant differences in the number of factor-containing cells before and after biomaterial grafting was found either in males ($p=0.724$) or females ($p=0.161$).

We found a great variety of numerous TGF β -containing cells in biotates before implantation of bone substituting biomaterials. (Fig. 3.2.)

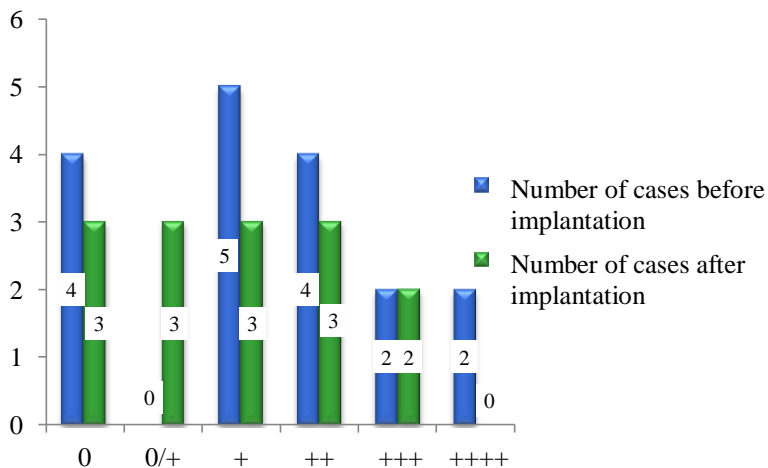


Fig. 3.2. Relative frequency of TGFβ-containing cells in *sinus lift* area bioptates before and after biomaterial grafting

0 - no positive structures found in the visual field; 0/+ rare positive structures in the visual field; + few positive structures in the visual field; ++ moderate number of positive structures in the visual field; +++ numerous positive structures in the visual field; ++++ a lot of positive structures in the visual field

The number of TGFβ-containing cells in bone was 1.56 ± 1.32 before and 1.11 ± 0.92 after biomaterial grafting. No statistically significant difference ($p=0.39$) was found in outcomes before and after biomaterial grafting.

A lot (+++) of osteopontin-containing cells were found in most bone tissues before implantation of bone substituting biomaterials (Fig. 3.3.).

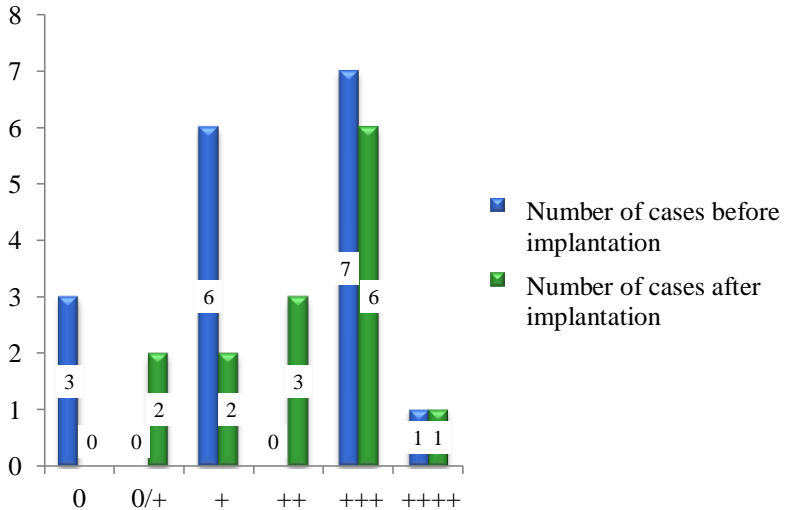


Fig. 3.3. Relative frequency of OP-containing cells in *sinus lift* area before and after biomaterial grafting

0 - no positive structures found in the visual field; 0/+ rare positive structures in the visual field; + few positive structures in the visual field; ++ moderate number of positive structures in the visual field; +++ numerous positive structures in the visual field; ++++ a lot of positive structures in the visual field

The mean number of OP-containing cells before grafting was 1.82 ± 1.33 , while after biomaterial grafting it was 2.14 ± 1.06 , which was statistically insignificant difference ($p=0.66$). No statistically significant differences were found in the number of factor-containing cells before and after biomaterial grafting either in males ($p=0.622$), or in females ($p=0.387$).

After examination of OC-containing cells in bone preparations before implantation of bone substituting biomaterials, a lot of OC-containing structures were found in samples from nine patients (Fig. 3.4.).

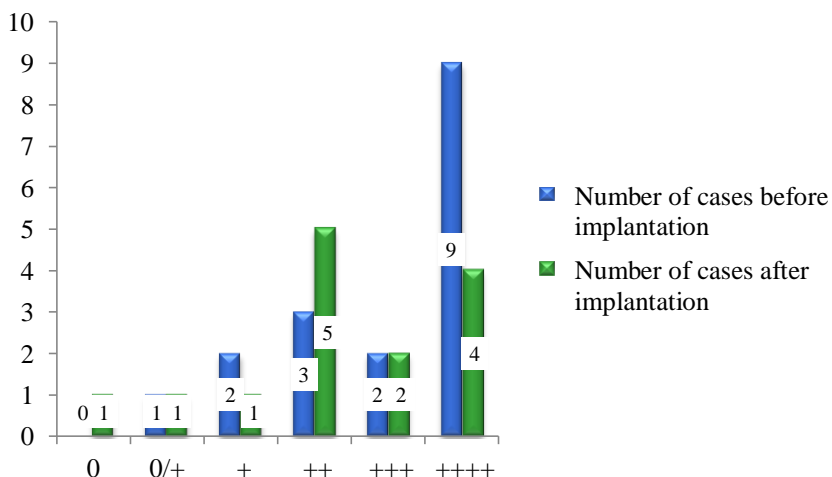


Fig. 3.4. Relative frequency of OC-containing cells in *sinus lift* area before and after biomaterial grafting

0 - no positive structures found in the visual field; 0/+ rare positive structures in the visual field; + few positive structures in the visual field; ++ moderate number of positive structures in the visual field; +++ numerous positive structures in the visual field; +++++ a lot of positive structures in the visual field

The mean quantity of OC-containing cells in bone tissue before biomaterial grafting was 2.97 ± 1.28 , while after biomaterial grafting it was 2.39 ± 1.33 . Changes in the number of OC-containing cells before and after biomaterial grafting was statistically insignificant ($p=0.21$).

We registered the quantity of apoptotic cells in bone preparations and obtained a variety of data – from highly positive to negative TUNEL reactions (Fig. 3.5.).

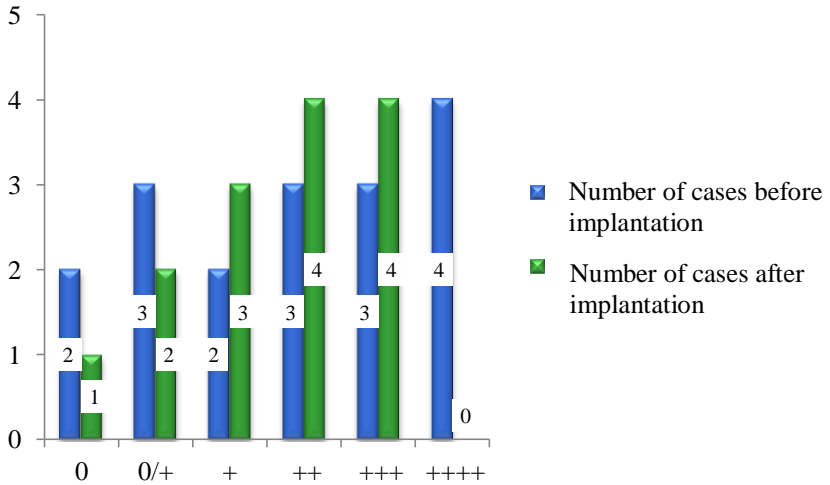


Fig. 3.5 Relative frequency of apoptotic cells in *sinus lift* area before and after biomaterial grafting

0 - no positive structures found in the visual field; 0/+ rare positive structures in the visual field; + few positive structures in the visual field; ++ moderate number of positive structures in the visual field; +++ numerous positive structures in the visual field; ++++ a lot of positive structures in the visual field

The mean quantity of apoptotic cells in bone was 2.05 ± 1.49 before biomaterial grafting and 1.67 ± 1.04 after implantation of a material in maxillary sinus cavity. Comparing changes in the number of apoptotic cells before and after implantation of biomaterial, no statistically significant differences were found ($p=0.52$).

We performed the same test in order to compare gender-specific frequency of apoptosis in patients' bone before and after biomaterial grafting. No statistically significant differences were found either in males ($p=0.22$) or in females ($p=0.49$).

Analysing frequency of osteoprotegerin – an indicator of bone remodelling activity, we found statistically significant differences: the mean

number of OPG-containing cells in bone tissue before biomaterial grafting was 1.47 ± 0.9 , while after biomaterial grafting in maxillary sinus cavity the quantity of OPG-containing cells statistically significantly increased, reaching 2.14 ± 1.06 ($p=0.08$). Median values of OPG-containing cell levels are shown in Figure 3.6.

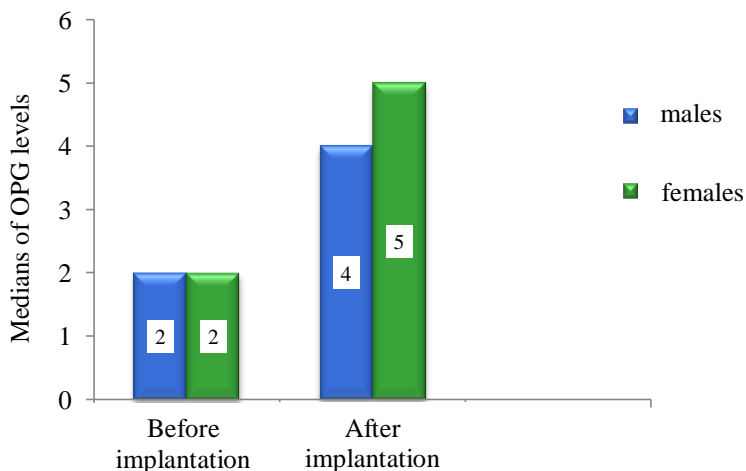


Fig. 3.6. Values of OPG-containing cell level medians before and after biomaterial grafting

Analysing the gender-specific data before and after biomaterial grafting, we obtained the following results: there were no statistically significant differences in the of males ($p=0.94$), while the group females showed statistically significant differences ($p = 0.031$). The above results lead to the conclusion that the number of OPG-containing cells in the total group of patients was statistically significant at the expense of female's group.

The mean quantity of MMP9-containing cells in bone tissue before biomaterial grafting was 1.03 ± 1.05 , while after biomaterial grafting it was

1.39±1.06. Changes in the quantity of MMP9-containing cells before and after biomaterial grafting were statistically significant (p=0.34).

Performing gender-specific analysis of data with the Mann–Whitney test before and after biomaterial grafting, we obtained the following results: MMP changes were statistically insignificant either in males (p=0.622), or in females (p=0.605) before and after biomaterial grafting.

Before insertion of bone tissue substituting biomaterials into maxillary sinus floor, as well as after sinus lift surgical procedure, in most cases, Hsp70 positive cells were detected rarely or were not found at all (Fig. 3.7.).

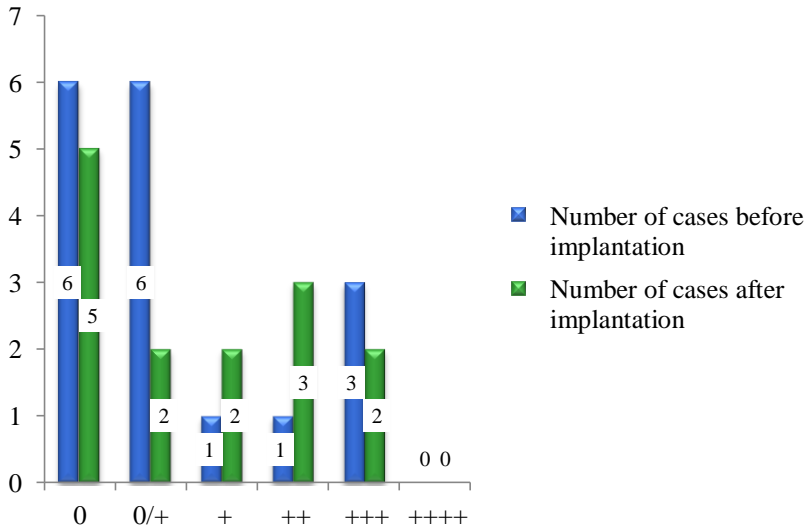


Fig. 3.7. Relative frequency of Hsp70-containing cells in *sinus lift* area before and after biomaterial grafting

0 - no positive structures found in the visual field; 0/+ rare positive structures in the visual field; + few positive structures in the visual field; ++ moderate number of positive structures in the visual field; +++ numerous positive structures in the visual field; ++++ a lot of positive structures in the visual field

The mean quantity of cells in bone tissue containing Hsp70 before biomaterial grafting was 0.82 ± 1.04 , while after biomaterial grafting it was 1.03 ± 1.06 . Changes in the number of Hsp70-containing cells before and after biomaterial grafting was statistically insignificant ($p = 0.63$).

The mean number of defensin-containing cells in bone tissue before biomaterial grafting was 1.5 ± 0.81 , while after biomaterial grafting it was 1.32 ± 0.95 . Changes in the quantity of defensin-containing cells before and after biomaterial grafting was statistically insignificant ($p=0.59$).

Using Spearman's test, we analysed correlation of the defined factors in maxilla of 17 patients before biomaterial grafting (Table 3.1). Moderately close correlation is marked with an asterisk *, close correlation is marked in red and with an asterisk *.

Table 3.1.

Coefficients of intercorrelation (r_s) of the factors analyzed in bioplates before biomaterial grafting

Factor	OC	BMP	OP	TUNEL	OPG	MMP	Hsp 70	Defensin	TGF β
OC	1.000								
BMP	0.513*	1.000							
OP	0.692*	0.404	1.000						
TUNEL	0.692*	0.286	0.560*	1.000					
OPG	0.739*	0.346	0.540*	0.585*	1.000				
MMP	0.309	0.733*	0.035	0.276	0.173	1.000			
Hsp70	0.202	0.405	-0.057	0.318	0.025	0.591*	1.000		
defensin	0.484*	0.307	0.154	0.456*	0.212	0.379	0.320	1.000	
TGF β	0.359	0.385	0.267	0.369	0.121	0.299	0.807*	0.145	1.000

The analysis of the Spearman's rank correlation coefficients between immunohistochemical values before biomaterial grafting in maxillary sinus cavity provided us with the following coherency:

1. an increase of TGF β distribution in bone tissue increased Hsp70 distribution, showing a close correlation ($r_s=0.806$);

2. an increase of the amount of osteocalcin-containing cells increased the quantity of osteopontin-containing cells, showing a medium close ($r_s=0.692$) correlation;

3. an increase of the quantity of osteocalcin-containing cells increased the number of apoptotic cells ($r_s=0.692$), osteoprotegerin ($r_s=0.74$), BMP ($r_s=0.513$) and defensin ($r_s=0.484$) containing cells, showing a medium close correlation;

4. an increase of distribution of BMP2/4 in cells increased the relative quantity of MMP-containing osteocytes, showing a medium close correlation ($r_s=0.733$);

5. an increase of distribution of OP increased the number of apoptotic cells; both of these values have showed a medium close intercorrelation ($r_s=0.560$);

6. relative quantity of OP- and OPG-containing cells also are showed a medium close intercorrelation ($r_s=0.540$);

7. an increase of the number of apoptotic cells increased also the number of the bone activity indicator – osteoprotegerin-containing cells, showing a medium close ($r_s=0.585$) correlation, as well as the distribution of defensin, showing a weak ($r_s=0.456$) correlation;

8. an increase of the number of Hsp70-containing cells increased the MMP distribution in cells, showing a medium close correlation ($r_s=0.591$).

The defined intercorrelations of other factors were weakly explicit.

We used the Spearman's test to analyze correlations of the defined factors in maxillary bones of 14 patients after biomaterial grafting (Table 3.2.).

Table 3.2.

Coefficients of intercorrelation (r_s) of factors analyzed in bioplates after biomaterial grafting

Factor	OC	BMP	OP	TUNEL	OPG	MMP	Hsp 70	Defensin	TGF β
OC	1.000								
BMP	0.111	1.000							
OP	0.214	0.752*	1.000						
TUNEL	0.294	0.059	0.429	1.000					
OPG	0.214	0.752*	1.000*	0.429	1.000				
MMP	0.108	0.365	0.159	-0.134	0.159	1.000			
Hsp70	-0.297	0.370	0.063	0.475*	0.063	0.631*	1.000		
Defensin	-0.129	0.019	-0.028	-0.341	-0.028	0.658*	0.640*	1.000	
TGF β	-0.086	0.673*	0.425	-0.203	0.425	0.032	0.448	0.069	1.000

The analysis the above factors after insertion of a biomaterial into maxillary sinus cavity provided us with the following results:

1. an increase of OP quantity in bone cells increased the content of osteoprotegerin in osteocytes, showing a close intercorrelation ($r_s=1.000$);
2. an increase of the quantity of osteopontin-containing cells increased the content of BMP2/4 in cells, showing a medium close ($r_s=0.752$) correlation;
3. the quantity of osteoprotegerin and BMP in cells also showed a medium close intercorrelation ($r_s=0.752$);
4. the amount of growth factors TGF β and BMP2/4 in cells showed a medium close ($r_s=0.673$) intercorrelation; an increase of the quantity of BMP2/4-containing cells increased the number of TGF β -containing cells;
5. an increase of tissue degrading enzyme MMP in bone cells increased the relative quantity of cell stress protein Hsp70 ($r_s=0.631$), and the

number of antimicrobial protein DF-containing cells ($r_s=0.658$) also increased, showing a medium close correlation;

6. an increase of DF-containing cells increased the content of Hsp70 in the bone cells, showing a medium close correlation ($r_s=0.640$);

7. an increase of apoptotic cells increased also the number of HSP70-containing cells, showing a weak ($r_s=0.475$) correlation.

The defined intercorrelations of other factors were weakly explicit.

3.2. Results of radiologic examination

The analysis of CBCT data before surgery showed that the mean measurement of alveolar bone radiodensitometry buccally is 224.83 HU (SD±164.62) while palatally it is 248.96 HU (SD±155.27). Large standard deviation was observed in all measurements: the maximum buccal radiodensitometric measurement was 533 HU and the minimum measurement was 15 HU, while the maximum palatal bone density was 624 HU and the minimum bone density was 35 HU.

The analysis of CBCT data after biomaterial grafting showed that the mean measurement of alveolar bone radiodensitometry buccally is 257.96 HU (SD±183.65), while palatally it is 303.75 HU (SD±200.57). These measurements also show a large range of measurements among patients: the maximum buccal measurement was 950 HU and the minimum measurement was 55, while the maximum palatal measurement was 788 HU and the minimum measurement was 64 HU.

The mean post-surgical measurements of 18 patients were higher than their pre-surgical measurements. Interestingly, that radiometric bone density measurements of six patients after biomaterial grafting showed lower results than before the surgical procedure.

The analysis of post-surgical CBCT data of bone/biomaterial hybrid showed that the average radiodensitometric measurement in hybrid buccally was 816.92 HU (SD±234.91) while palatinally it was 776.88 HU (SD±205.19). These measurements showed also large range of measurements among patients: the maximum buccal measurement in hybrid was 1.186 HU and the minimum measurement was 326 HU, while the maximum palatinal measurement in hybrid was 993 HU and the minimum measurement was 393 HU.

Radiodensitometric measurements of all patients and their standard deviations have been summed up in the Figure 3.8.

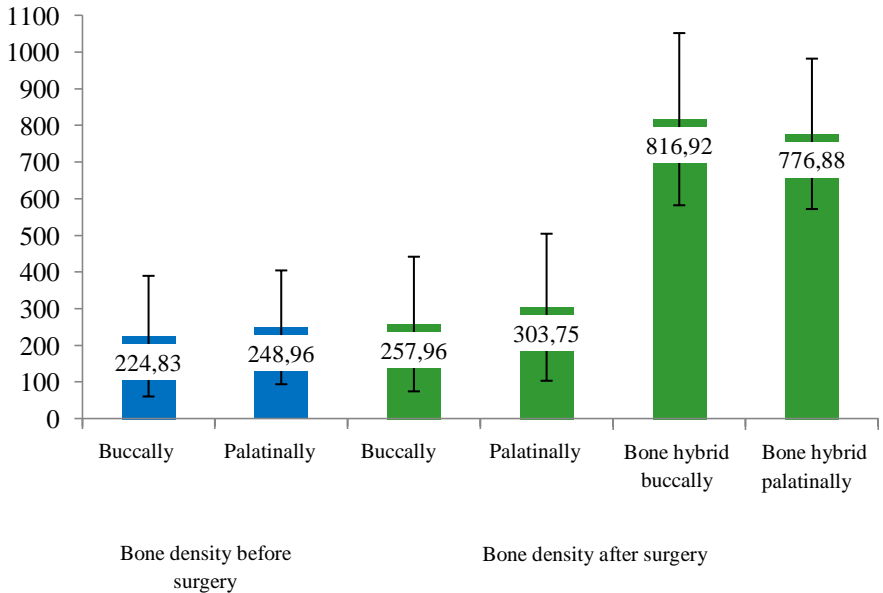


Fig. 3.8. Patients' CBCT examination results

Using the paired t test we compared the radiodensitometric measurements of alveolar bone (HU) before and after insertion of biomaterial into the maxillary sinus cavity (Table 3.3.). No statistically significant differences were obtained either buccally ($p=0.47$) or palatinally ($p=0.23$).

Table 3.3.

Average radiodensitometric measurements of the alveolar bone and standard deviation before and after biomaterial grafting

Localization	Total number of patients	Before <i>sinus lift</i> ±SD, HU	After <i>sinus lift</i> ±SD, HU	p value (p≤0.05)
Buccally	24	224.8±164.6	257.9±183.6	0.47
Palatinally	24	248.9±155.3	303.7±200.6	0.23

Radiodensitometric density of the buccal bone hybrid site compared to the maxilla before sinus lift, showed statistically significant ($p<0.0001$) difference (Table 3.4.).

Table 3.4.

Average radiodensitometric buccal measurements of alveolar bone density and standard deviation before and measurements of biomaterial hybrid site after biomaterial grafting

Total number of patients	Buccal bone site before <i>sinus lift</i> ±SD, HU	Buccal hybrid site after <i>sinus lift</i> ±SD, HU	p value (p≤0.05)
24	224.8±164.6	816.9±234.9	p<0.0001

Radiodensitometric density of the palatinal bone hybrid site compared to the maxillary alveolar ridge before sinus lift, also showed statistically significant ($p<0.0001$) difference (Table 3.5.).

Table 3.5.

Average radiodensitometric palatinal measurements of alveolar bone density and standard deviation before and measurements of biomaterial hybrid site after biomaterial grafting

Total number of patients	Palatinal bone site before <i>sinus lift</i> ±SD, HU	Palatinal hybrid site after <i>sinus lift</i> ±SD, HU	p value (p≤0.05)
24	248.9±155.3	776.9±205.2	p<0.0001

The study showed statistically significant differences comparing the bone hybrid site and the residual bone site.

The measurement of residual alveolar bone after biomaterial grafting into maxillary sinus cavity increased buccally by an average of 30 (HU), and palatally – by 50 (HU). Unfortunately, these data were not statistically significant.

3.3. Patients' survey results

250 questionnaires were sent to the patients, 148 of these questionnaires were filled out and returned. None of the respondents gave affirmative answers to the question regarding grafting site disorders, as well as disorders in maxillary sinus cavity (pain, bleeding, increased sensitivity).

Only two patients reported occasional nasal secretion. These patients came in to repeated clinical and radiological investigations. CT scans of these patients showed no inflammations.

Total of 294 dental implants were implanted in 148 patients. Eleven implants of six patients were lost. The number of lost implants totalled 4% of all implants inserted.

Before implantation, these patients underwent sinus lift surgeries involving the use of different bone substituting materials. Three patients underwent grafting with Altipore and the rest three patients underwent biomaterial grafting with TUTOGEN, Bone ceramic and HAp developed by RTU. No statistically significant differences between the used bone substituting materials were found ($p=0.261$).

We detected statistically significant correlation between the number of implants and the loss of implants. An increase of the number of implants increased the risk of implant loss by 1.8 ($p=0.037$).

Nine out of 148 patients responded affirmatively on the question regarding the loosening of implant suprastructure, totalling 6% of all respondents.

The following question provided explanations on loosening of the marked implants. None of the patients had experienced loosening of his/her dental implants; however other manifestations of instabilities of dental suprastructures – such as decemented prosthesis or unscrewed fixation screw – were regarded as loosening.

Patients' satisfaction with prosthetic aesthetics also played a role in their answers regarding satisfactions with treatment outcomes and intents to continue treatment at Institute of Dentistry of RSU. 139 patients in this study indicated that they were fully satisfied with aesthetics of their prosthesis, while 9 patients were unsatisfied with aesthetics of their prosthesis, totalling 6% of all patients. Comparing gender-related satisfaction with prosthetic aesthetics, no statistically significant differences were found ($p = 0.742$).

32 patients, totalling 22% of all respondents, responded negatively to the question regarding their satisfaction with functionality of their implant. In fact, answering to this question most patients assessed the treatment process in general, as they have listed all kinds of complaints and reasons for dissatisfaction – starting from aesthetics of their prosthesis and time-consuming treatment process and up to poor communication with doctors and medical support staff, as well as high costs of dental implants.

Regardless some complaints and critics from patients, almost all of the surveyed patients (148) were willing to repeatedly receive treatment at Institute of Dentistry of RSU. Only four patients gave negative answers, while five patients had no certain opinion.

A proper oral hygiene is essential for all patients, especially with dental implants. After insertion of implants, doctors recommend visiting a dental hygienist at least twice a year. Unfortunately, patients' answers to this question were unsatisfactory, as nearly half of all respondents visit a dental

hygienist only once a year, but ten patients fail to attend a dental hygienist at all. Various factors are behind this situation, for example, they claim living far-off or that the costs are too high for them.

Overall, patients' survey data confirm the long-term performance efficiency and low incidence of complications of the enhancement of atrophic maxilla with biomaterials and osteointegrated dental implants.

4. DISCUSSION

4.1. Morphological changes

Bone biopsies were harvested from 17 patients of the morphologically analyzed group before insertion of a biomaterial and from 14 patients – after biomaterial grafting into maxillary sinus floor. Unfortunately, during the period of planning of the design of the study, it was impossible to predict which patient will come-in for dental implants after six to eight months. In the beginning we wanted to compare twenty patients before and after biomaterial grafting, however we were forced to reduce the study group as not in all cases patient's residual alveolar ridge before biomaterial grafting was 3-5 mm, which was pre-requirement for preparation of 10 morphological samples for one patient. Harvesting biopsy after biomaterial grafting was greatly troubled by the closeness of dental implants and adjacent teeth which impedes harvesting enough material from a bone, and the fact that 2 mm trepanning drill is a very aggressive tool able to weaken bone margin that is the determinant for the primary stability of a dental implant. In such situations, it was impossible to harvest biopsies due to ethical reasons. Some patients did not continue their dental treatment at the clinic. In the result of the above, we have analyzed all patients before and after biomaterial grafting to avoid losing the valuable material. Undoubtedly, results of a homogenous group of twenty patients would have been more reliable. Only few studies on immunohistochemical analysis of samples can be found in literature. This is attributable to the high costs of the method, as well as to the need for involvement of morphology specialists to provide a high-quality study. Morphological researches conducted by other authors who have analyzed enhancement of maxilla, show the number of patients ranging from eight to twenty-six. Karabuda (2001) has histologically

and clinically analyzed integration of three different biomaterials in posterior part of maxilla in eight patients 12 to 24 months after biomaterial grafting; Barone (2005) harvested biopsies from 18 patients to compare autograft bone and porcine bone/bone autograft mixture (1:1), bilaterally lifting the maxillary sinuses. Analysing morphologies of bone biopsies after five months, the scientists found no differences in the new bone formations between the two study groups. The number of immunohistochemical studies found in literature is small and the number of patients examined varies from one to ten clinical case. Usually those studies that compare two different biomaterials in maxillary sinus cavity provide immunohistochemical analysis of one or maximum three immunohistochemical markers. In our study, we have examined nine different functional measurements of bone tissue; and no study of this magnitude is present in literature.

The majority of patients' statement histological preparations of our researches showed good osseointegration of a biomaterial in patient's maxillary sinus floor without the presence of inflammatory cells six to eight months after biomaterial grafting. Some preparations showed also ingrowths of connective tissue around grafted materials – in two out of three cases of Tutodent grafts and in one case of Bio-Oss graft. Morphological analysis was performed using a semi-quantitative light microscopy, which nowadays is controversially assessed in literature. Regardless fact that immunohistochemical examinations are widely used in everyday medicine and science, methods of standardization are incomplete. Interpretation of immunohistochemical cell staining should be based on microanatomic distribution and staining intensity, which should be repeatable. Precise quantitative immunohistochemistry requires the use of control materials with a certain amount of antigen parallelly tested with computer assisted microspectrophotometry. This method could improve the standardization of immunohistochemical analysis of preparations.

Several morphological studies compare results of bone autograft transplantation with implantation of other bone substituting materials in cases of sinus lift. If five or more years ago a bone autograft was considered a “gold standard” with better morphological outcomes compared outcomes with other materials, the most recent reports provide no evidence of statistical significant bone autograft advantages. The analysis of different measurements of bone functional morphology of our studies show no statistically significant differences depending on type of the biomaterial grafted.

Hallman et al (2002) came to similar conclusions. They performed 36 *sinus lifts* on 21 patient, using bone autograft, bovine bone or a combination of both materials (80/20). None of the groups showed statistically significant differences. The authors concluded that a bone autograft which has been regarded as a “gold standard” for many years, can be substituted by bovine bone apatite. The addition of bone autograft could only slightly reduce the healing time.

Browaeys et al (2007), in turn, analysing 26 scientific publications, have concluded that regardless 40% resorption of a bone autograft, it is still the most predictable material thanks to its osteoconductivness. The authors believe that bovine bone apatite added to a bone autograft resorbes slower and can maintain the required volume.

The presence of osteoclasts and macrophages in calcium phosphate bone-substituting materials shows biodegradation of biomaterials which, in findings of our study, indicates the ability of these materials to participate in living bone remodelling process.

The significant number of morphological researches on histological changes after implantation of different bone substituting biomaterials in maxillary sinus floor shows no statistically significant advantages of one material over others.

Overall, our data of routine histological examination are consistent with studies of other authors, indicating no significant morphological differences in the way how bone substituting biomaterials, tested under established procedure and permitted for clinical use, used for sinus lifts, integrate in augmented maxillary sinus floor showing only a few, mostly quantitative, peculiarities of the newly formed biomaterial/live tissue hybrid. Examinations of functional morphology can provide deeper explanations on causes of these peculiarities.

The results of our study show that the biomaterial/tissue hybrid newly formed during sinus lift surgery has functional morphology similar to the one of a natural bone.

In our study, we detected no statistically significant differences between quantities of growth factor BMP2/4 and TGF β -containing structures before and after biomaterial graftings. The mean amount of BMP2/4-containing cells was 2.20 ± 1.19 before biomaterial grafting and 1.89 ± 1.24 after biomaterial grafting ($p=0.45$). Number of TGF β -containing cells in bone tissues was 1.56 ± 1.32 before grafting and 1.11 ± 0.92 after biomaterial grafting ($p=0.39$). This means that bone has maintained its growth potential, even regardless the surgery-induced trauma.

Harris et al (1994) have conducted in vitro studies and they have found that bone resorption leads to distribution of active form of TGF β , which is a stimulator of a potential bone growth. Zhao et al (2011) have shown that the beginning of bone healing process during osseointegration of dental implants slowly increases the amount of growth factor BMP2, as well as the matrix protein OC- and OP-containing structures, while the amount of TGF β 1 increases around tenth day after surgery, but later it reduces. Salma et al (2009), by performing an experimental implantation of HAp ceramic materials in animals, found that HAp materials three months after implantation initiate a statistically significant increase of TGF β 1 structures in bone tissue.

Data found in literature and our results show that the amount of growth factor-containing structures differs at different periods after biomaterial grafting. An important factor is also the composition of the analyzed grafts, namely, whether it contains an atrophic patient's bone, newly formed bone and biomaterial hybrid, or a combination of these two components. In our patient grafts, using trepan drill, we basically always could manage to harvest alveolar bone together with the newly formed hybrid.

Our results after sinus lifts showed increased amount of OP-containing cells, which could indicate integration of the implanted biomaterial into maxilla during the process of remineralisation. The mean number of OP-containing cells before grafting was 1.82 ± 1.33 while after grafting it reached 2.14 ± 1.06 ($p=0.66$). However this result is not statistically significant.

Mangano et al (2003) have conducted a clinical study in which a great amount of osteopontin-containing structures were found in patients' bone biopsies after implantation of HAp granules. They have concluded that osteopontin may promote regeneration of bone tissue. Jankovska et al (2009) have found that the amount of osteopontin-containing cells in maxilla of patients with mandibular prognathia surpassed the number of osteocalcin-containing cells. McKee (2011) in his studies showed that OP has mineral-binding properties. It can bind surgically created bone defect surface fragments during differentiation of osteoblast, formation of bone tissue extracellular matrix and mineralization (McKee and Nanci, 1996). The researchers believe that OP is responsible for cell adhesion, cell inter-communication and matrix mineralization, which is necessary for effective formation of a new bone in the place of surgical defect.

Analysing the amount of OC-containing structures obtained during the research, we found no statistically significant changes in the amount of OC-containing structures. The average amount of OC-containing cells in bone

tissue was 2.97 ± 1.28 before biomaterial grafting and 2.39 ± 1.33 after biomaterial grafting ($p=0.21$).

Hoang et al (2003) believe that the function of OC is structure-based. OC participates in bone mineralization processes and in insuring of calcium ion homeostasis as OC, due to its negatively charged surface, provides calcium ion spatial distribution, similar to the one in HAp crystalline structure. Ivaska (2005) in her research has found that OC is not only a marker of newly formation of a bone but also an indicator of bone metabolic activity as osteoclasts also release OC during the bone resorption.

In our case, it is also believable that the difference of OC and OP expression depends on the time of its assessment; greater OP expression happens on early stages of osteogenesis adhesion of osteogenesis takes place on the surface of a biomaterial which is necessary process for further successful osteogenesis. OC, in turn, is an indicator of metabolic activity, whose statistically significant increase would be found in the phase of bone mineralization.

In our research, we have obtained statistically significant changes in the amount of OPG. The average amount of OPG-containing cells in bone tissue before biomaterial grafting was 1.47 ± 0.9 , while after biomaterial grafting in maxillary sinus cavity the amount of OPG-containing cells have statistically significantly increased, reaching 2.14 ± 1.06 ($p=0,08$).

Kobayashi et al (2009) emphasized the role of osteoprotegerin released by osteoblast in regulation of neogenesis. They indicate that OPG is one of the key blockers of osteoclast differentiation. Hofbauer (1999) also believes that OPG is one of the most potent inhibitors of osteoclast differentiation. The author finds that OPG could be used to reduce osteolysis and aseptic inflammation around implants.

The statistically significant increase of OPG obtained in our study, also could prove that the time of samplings of our patient grafts during

sustained bone regeneration process is attributable to the early stage of osteogenesis when the reduction of osteoclast activity and the associated increase in osteoblast differentiation take place.

In our study, the median number of Hsp70-containing cells in bone tissue before biomaterial grafting was 0.823 ± 1.04 and after biomaterial grafting it was 1.03 ± 1.06 . Changes in the amount of Hsp70-containing cells before and after biomaterial grafting was not statistically significant ($p=0.63$).

It is known that the release of Hsp70 takes place during physiological response to stimulation. Shigehara (2006) observed that the amount of Hsp70-containing structures in patients' bone cells during orthodontic treatment was higher than in the control group, suggesting that orthodontic treatment-induced teeth loosening causes degenerative changes in dental pulp cells.

The average number of antimicrobial immunity indicator – defensin-containing cells in bone tissue before biomaterial grafting was 1.5 ± 0.81 , while after biomaterial grafting it was $1.32 \pm .95$. Changes in the amount of defensin-containing cells before and after biomaterial grafting were statistically insignificant ($p=0.59$).

In vitro studies of several authors have shown that the amount of defensin in cell cultures increases by working on cells with pro-inflammatory cytokines, such as interleukin 1 or tumour necrosis factor α (Harder et al, 2000, Singh et al, 1998; Varoga et al, 2005), or with bacteria (Harder et al, 1997; Varoga et al, 2004).

We were able to conclude that six months after biomaterial graftings performed by us, there were no permanent signs of tissue damages expressed in quantitative changes of cell activity indicator – Hsp70 and anti-microbial activity factor – defensin-containing structures.

In our research we were surprised by the large number of apoptotic cells before biomaterial grafting that could indicate bone quality before graftings. In this case, patients suffered from prolonged edentulism and severe

atrophy of posterior maxilla, where we found an explicit bone cell apoptosis. Analysing data of our survey, we obtained lower number of apoptotic cells after biomaterial grafting than it was before grafting. However this difference was not statistically significant. The average number of apoptotic cells in bone tissue was 2.05 ± 1.49 before biomaterial grafting and 1.67 ± 1.04 after implantation of a material in maxillary sinus cavity ($p=0.52$). Atari et al (2011) have conducted studies analysing apoptosis in autograft bone. The researchers have found that regardless of the autograft source and places, there is an explicit bone cell apoptosis – from 96.1 to 97.7% of all cells.

The obtained high levels of apoptosis in atrophic alveolar maxilla render explanation of functional morphology of pathogenetic mechanisms of this pathology, so common and topical in dental practice, and outline positive effects of calcium phosphate biomaterials. The decrease of apoptosis achieved in our study after implantation of hydroxyapatite materials could confirm the beneficial effects of this material on bone remodelling – from atrophy to osteogenesis.

The amount of MMP9-containing structures before and after sinus lift showed no statistically significant differences. The average number of cells in bone tissues, containing MMP9 biomaterial before grafting was 1.03 ± 1.05 , while after biomaterial grafting it was 1.39 ± 1.06 ($p=0.34$).

Vu et al (1998) in their research found that MMP 2 and MMP 9 promote an increase of apoptosis during tissue remodelling and neo-angiogenesis.

However, the results of our study show that six months after implantation of HAp material, biopsies show no permanent signs of degradation in bone intercellular substance.

There are only some studies on comparison of bone functional morphology before and after insertion of biomaterials in maxillary sinus floor. The limitations of such studies are explainable, as it is very difficult to form

necessary study group of patients from whom it would be possible to harvest bone biopsies before sinus lifts and several months thereafter. In order to carry out such clinical trials, it is necessary to provide patients with detailed explanations on the nature of the study. The most important principle for conduct of such studies is to ensure patient safety, as no study may become an end in itself for a scientist while forgetting about patients' health risks. Our morphological study group also included five patients from whom, due to various reasons, we were unable to harvest bone tissue samples after biomaterial grafting regardless to the fact that their biopsies were harvested before sinus lifts. Basically two reasons were behind this – too small volume of augmented bone/biomaterial or too narrow alveolar ridge. In one case, harvesting of bone biopsy was impeded by structures of adjacent teeth.

Our study on the use of bone substitute HAp material confirms the results of studies carried out by other authors on HAp as the main chemical component and bioceramics as the key structural solutions for enhancement of atrophic maxilla. Congeniality of synthetic HAp bioceramic material to biological HAp is confirmed by histological evidence of its osteoclastic biodegradation in which the presence of osteoclast-like macrophage activity on the surface of granules is found. This paves the way for further mechanism of tissue/bioceramic composite integration in normal morphological and physiological processes of bone tissue.

4.2. CT data analysis

Radiological examination which is basically used for assessment of dental implant osseointegration, less for radiologic view of the augmentation site and radiologic changes in residual atrophic alveolar bone, plays an important role in evaluation of maxillary sinus floor augmentation and dental

implantation. Nonetheless, radiological image of the augmentation site itself and radiological changes of residual atrophic alveolar bone has been little assessed.

In our study on measures of maxillary bone radiodensity with CBCT method, we focused on the dynamics of changes in bone radiodensity after biomaterial grafting instead of a single measurement. Statistically significant explicitly increase of bone density in all groups of patients we obtained for biomaterial/bone hybrid comparing to residual bone before biomaterial grafting. Our study did not confirm the promotion of residual bone remineralisation by bioceramic materials grafted, which would have visualized as statistically significant increase of bone density in residual bone after sinus lift surgery. More likely that the reason behind this is the relatively short period of time after biomaterial grafting (6-8 months), which is insufficient for triggering changes in residual bone density detectable by the CBCT method. In the previously performed long-term radiological observation of the augmented site of maxillary sinus floor and the adjacent atrophic alveolar bone we found that mineral density in the bioceramic granule area decreases over the years while in atrophic alveolar bone it increases and smoothes out within 3–5 years. It reaffirms the adaptation of calcium phosphate bioceramic materials in natural process of bone tissue remodelling and opens up a new direction for researches and clinical approbation for application of these materials in osteoporotic bone remineralization and reinforcement. The finding has been approved by the patent of the Republic of Latvia.

Since the cone-beam computed tomography method in assessment of augmented maxillary floor has been used for less than a decade, a number of studies have been carried out to define indications for application of the method, as well as to find an approval for measurement accuracy. Wang et al (2012) in the experiment with animals have shown that the CBCT method is accurate for assessment of bone value around the grafted bone substituting

material. Similar conclusions were found also by Stratemann et al (2008), who in their studies compared the accuracy of measurements of the CBCT method with a physical measurement of a skull and in their results they obtained differences of less than 1%. Also, Patel et al (2012) have concluded that the use of CBCT method provides dentists with highly accurate measurements; they also permit prediction of reliable final outcomes of reconstructive surgery.

The use of cone beam computed tomography method for measuring bone density has its proponents and opponents. Araki et al (2011) have concluded that the adjacent structures such as dental implants may cause inaccurate measurements when the CBCT method is carried out for determination of bone density. Whereas Georgescu et al (2012) have compared quantitative and qualitative measurements of maxillary bone floor by analysing the CBCT and orthopantomograms. Also, Kaya et al (2012) and Nomura (2010) have concluded that the CBCT method can be applied for measuring bone density, and these measurements closely correlate with measurements of bone density performed by classical spiral CT. During the International Congress of Oral Implantologists held in Seoul in 2011, the working group chaired by Benavides (2012) adopted guidelines for application of the CBCT. It was recommended to use this method for planning of dental implants, especially in evaluation of three-dimensional bone topography. While measurements of bone density and evaluation of post-implantation artifacts require further research.

4.3. Patients' survey data analysis

In our study, 292 dental implants inserted in 148 patients showed stable functioning within 3-6 years after initial loading totalling 95.99% of cases in 95.93% of patients. Six (4.07%) patients have lost 12 (4.01%)

implants. One implant was lost due to postoperative maxillary sinus inflammation, one implant was lost due to unstable osseointegration in an explicitly osteoporotic atrophic bone, 10 implants were lost due to periimplantitis within 2-5 years.

The summary of late results, carried out by Wallace and Froum (2003) on data from 43 publications, showed 61.7% to 100% "survival" of dental implants for longer than one year after maxillary sinus augmentation. Periimplantitis is the most common direct cause in studies involving a small number of observations. According to the literature data, its frequency range from 2-10% after dental implantation into alveolar bone sufficient in size and quality in cases when *sinus lift* was not performed (Roos-Jansaker, 2006; Heitz-Mayfield, 2008).

In our patients' survey study, the most frequently used bone replacement biomaterial during the period of analysis was Algipore which was used in 67 patients or 51.15% of cases. The second most frequently used material was the material developed by the Laboratory of Biomaterials of RTU – synthetic HAp bioceramic granules. In the group of synthetic materials, in 17 patients or 12.97% of all sinus lift patients we used biphasic material Bone Ceramic (Straumann) containing HAp/ β TCP in ratio of 60:40, and in 2.29% of patients we used pure β tricalcium phosphate material – Cerasorb. Cerasorb comparing to HAp bioceramic materials shows faster resorption in experimental and clinical histomorphological observations (Khouri, 1999).

The most frequently used xenograft of our study was Bio-Oss having normal bone trabecular structure, 75% to 80% porosity; its chemical composition basically is HAp. Manufacturers claim that the above material is completely deproteinized, which is questioned by some studies (Taylor, 2002). After four days of incubation in osteoclast cell cultures, Bio-Oss showed positive expression of collagen I and the nitrogen concentration on its surface was 0.17 to 0.47% which in normal bovine bone is 6.01 to 9.25%. Comparative clinical

and morphological observations six months after sinus lift with synthetic porous HAp and Bio-Oss showed no significant differences (Mangano, 2007). In the material analysed by us, Bio-Oss was applied in 8-10% cases with a smooth early postoperative period and stable late results.

From the aspect of dental implant survival, the long-term sustainability of the used biomaterial and integration into atrophic alveolar bone, adaption in residual bone and in the newly formed composite/hybrid remodeling process is of a great importance. Wallace and Froum, analysing the results of bone autografting, have concluded that 100% of the use bone autograft or its adaption in the composition with biomaterials has no affect on long-term stability of dental implants.

The summary study of earlier period, (Liljenstein et al, 1998) based on 12 clinical trials, showed that the loss of dental implants with bone autograft in the reinforced jaw, during 1 to 10-year loading period was 14.6% (220 of 1505 implants). Analysing data of ten randomized trials on sinus lift and efficiency of dental implantation following the use of different biomaterials, Esposito (2010) has concluded that bone substitutes can be successfully used instead of bone autografts. Among disadvantages of autografting from the beginning of their analysis to the present days are donor site trauma with possible complications, limited value of autograft and unpredictable resorption (Liljenstein, et al, 1998), totalling around 40% of the volume (Browaeys, 2007). Holmes and Hagler (1988) in their up to four-years observation during the early period of HAp studies, comparing healing of porous HAp graft and bone autograft insertion in maxilla, histometrically found mineralized tissue composition 58.6% after HAp grafting, comparing with 55.8% after the use of bone autograft. On the basis of these observations it was concluded that HAp matrix can be used instead of bone graft. Such option was even more confirmed by observations on the ability of HAp to promote osteogenetic differentiation, attracting circulating bone sialoprotein and osteopontin (Nanci, 2000) or cell

adhesion-promoting peptide P15. Ripamonti (2009), over a one-year observation after heterotopic grafting of HAp in monkeys found spontaneous osteoinduction. In the evaluation group of our late outcomes, bone autografting in conjunction with biomaterials was used in five patients (3.37%), thus troubling drawing of statistically reliable conclusions about the effects of bone autograft on late outcomes.

The largest summative study (Aghaloo et al, 2007) on materials for sinus lift surgeries, based on stability of 5128 dental implants within the period of 12 to 102 months, showed osseointegration of 92% implants in autograft or in combination of autograft with biomaterials, 93.3% - in allogenic/nonautologous composite; 81% - in just alloplastic material or in its combination with xenograft; 95.6% - in xenografts.

None of literature sources on materials for augmentation of maxillary sinus floor followed by dental implantation evidence serious deficiencies because of which autologous, xenogenic, allogenic or alloplastic synthetic materials would be significantly superior, usable or non-usable. The matter can be settled not by the factors of primary importance, but by nuances, such as less post-operative trauma for patients, sufficient stability of a material in the environment of a living organisms, origins from biological and psycho-ethical points of view, manufacturing possibilities, costs and commercial prices of materials. After evaluation of the above nuances, it is difficult to imagine any material closest to the natural ones than an artificially developed material almost identical to the key natural bone mineral HAp.

This material can be syntactically manufactured in any quantity; when preparing biphasic composition, it is possible to program the bioresorption rate tailoring it to the respective bone regeneration potencies. In this respect, HAp biomaterials and the biphasic variants developed at the Rudolfs Cimdin's Biomaterial Innovation and Development Centre of RTU can be reasonably placed among other state-of-art bone substitute biomaterials.

Assessing today's technological possibilities, the prevailing belief currently is the following:

1. In cases of an explicit alveolar bone atrophy with residual height of 1-3 mm – in lateral window sinus lift, using crushed bone autograft in conjunction with bone substituting biomaterials; usually in two steps;

2. In cases of light alveolar bone atrophy with residual alveolar bone height of 6-8 mm, which, however, is insufficient for insertion of dental implant having necessary length – osteotomes technique with or without miniimplantation of biomaterials;

3. In cases of moderate alveolar bone atrophy – lateral window technique, usually in a single stage. Apart from alveolar bone height measurements, horizontal size, i.e., density/width objectively measurable with CT, for example, with the cone beam CT, without any clinical signs, is as important measurement. Apart from alveolar bone volume measurements, alveolar bone quality, mainly its hardness definable by the degree of bone mineralization and osteoporosis.

5. CONCLUSIONS

1. The data base developed for registration outcomes of atrophic edentulous posterior maxilla enhancement with sinus lift surgery, as well as dental implantation late results and analysis of the data confirm high efficiency of the applied materials and technologies that have been affirmed by the low quantity of post-surgical complications (1%) and loss of dental implants (4%), as well as by the intention of patients to continue treatment at the Institute of Dentistry of RSU.

2. The CBCT radiodensitometric investigation of grafting site before and 6 to 8 months after grafting shows *sinus lift* area as radiodensitometrically denser compared to residual alveolar bone area where radiodensitometric density has increased during this period, however these measurements are not statistically significant which is explainable by comparatively short time for remineralisation of atrophic bone.

3. In great majority of cases, residual alveolar ridge and biomaterial/bone hybrid biopsies 6 to 8 months after grafting show osseointegration of biomaterials without signs of inflammation and connective tissue proliferation observed in isolated cases with Tutodent and Bio-Oss grafting.

4. The quantity of the immunohistochemically detected bone morphogenetic protein (BMP2/4), transforming growth factor beta (TGF β), bone extracellular matrix proteins osteopontin (OP) and osteocalcin (OC), degrading enzyme metalloproteinase 9 (MMP9), heat shock protein (Hsp70), anti-microbial protein defensin (DF) containing structures in trepan biopsies of atrophic alveolar maxilla before grafting and after *sinus lift* surgery with bone substituting biomaterial grafting has no statistically significant difference showing functional morphological similarity of the newly formed biomaterial/tissue hybrid with living bone.

5. The amount of the indicator of bone remodelling activities osteoprotegerin-containing structures in bone biopsies 6 to 8 months after bone substituting biomaterial grafting in maxillary sinus floor is statistically significantly higher than in atrophic alveolar ridge before biomaterial grafting thus suggesting continuation of active bone remodelling initiated by the bone substituting material implanted.

6. Relative frequency of apoptotic cells in biopsies show large individual fluctuations without statistical significance between females and males in atrophic alveolar bone before and in biomaterial/tissue hybrid after *sinus lift* surgery with a tendency of apoptosis to decrease in hybrid thus indicating on body's ability to eliminate cells through a programmed death, preventing formation of connective tissue.

6. RESEARCH PUBLICATIONS AND REPORTS

6.1 Scientific research papers

1. Neimane L., Skagers A., Salms G., Berzina-Cimdina L. Radiodensitometric Analysis of Maxillary Sinus-Lift Areas Enforced with Bone Substitute Materials Containing Calcium Phosphate // *Acta Chirurgica Latviensis*, 2013; 12(1): 41–44.
2. Zalite V., Groma V., Jakovlevs D., Locs J., Salms G. Ultrastructural characteristics of tissue response after implantation of calcium phosphate ceramics in the mandible of rabbit // *IFMBE Proceedings*, 2012; 194-197.
3. Pilmane M., Salms G., Salma I., Skagers A., Locs J., Loca D., Berzina-Cimdina L. Time-dependent cytokine expression in bone of experimental animals after hydroxyapatite (Hap) implantation // *IOP Conf.Series: Materials Science and Engineering*, 2011; 23, 012022, doi:10.1088/1757-899X/23/1/012022.
4. Vamze J., Pilmane M., Skaģers A., Šalms Ģ. Kaulaudu reģeneratīvo procesu noteicošo proteīnu izmaiņas truša apakšžokļa kaulā pēc hidroksiapatīta implantācijas // *RSU Zinātniskie raksti*, 2011; 167-174.
5. Salms G., Salma I., Skagers A., Locs J. 3D Cone beam radiodensitometry in evaluation of hydroxyapatite (HAP)/tissue hybrid after maxillary sinus floor elevation // *Advanced Materials Research*, 2011; 222:251-254; *Trans Tech Publications*, Switzerland, doi:10.4028/www.scientific.net/AMR.222.251.
6. Salms G., Skagers A., Zigurs G., Locs J., Berzina-Cimdina L., Feldmane L. Clinical, radiographic and pathohistological outcomes of hydroxyapatite (hap) ceramics and dental implants in atrophic posterior maxilla // *Acta Chirurgica Latviensis*, 2010; 9(1): 62–66.

7. Salms G., Skagers A., Salma I., Locs J., Berzina- Cimdina L., Feldmane L. Long term outcomes of HAp ceramics and dental implants in atrophic posterior maxilla // Bioceramics, 2009; 22:725 – 728.

6.2 Scientific research abstracts

1. Salms G., Salma I., Pilmane M., Skagers A., Locs J., Berzina-Cimdina L. Bone regenerative potential after HAp implantation in to maxillary sinus using immunohistochemistry // J Tissue Engineering Regenerat Med, 2012; 6(1):10, Abstracts of the 3rd TERMIS World Congress, September 5-8, 2012, Vienna, Austria.
2. Неймане Л., Скагрес А., Шалмс Г. Денситометрический анализ атрофированной альвеолярной кости после повышения дна верхне-челюстной пазухи и зубной имплантации // XVII Международная конференция челюстно-лицевых хирургов и стоматологов, 15-17 мая, 2012, Санкт-Петербург, Россия, стр. 126-127.
3. Шалмс Г., Скагерс А., Бирестанс А., Корневс Э., Лаускис Г., Жигурс Г., Озолиня С. Отдалённые клинические результаты после одно-моментного повышения дна верхнечелюстной пазухи и зубной имплантации // XVII Международная конференция челюстно-лицевых хирургов и стоматологов, 15-17 мая, 2012, Санкт-Петербург, Россия, стр. 194-195.
4. Šalms Ģ., Skaģers A., Bīgestāns A., Korņevs E., Lauskis G., Žīgurs G., Grieznis L., Ozoliņa S. Vēlīnie klīniskie rezultāti pēc vienmomenta augšžokļa dobuma pamatnes paaugstināšanas un zobu implantācijas // Tēzes, 303.lpp., RSU Zinātniskā konference 29.-30. marts.2012., Rīga, Latvija.

5. Salms G., I.Salma, A.Skagers, M.Pilmane, J.Locs, L.Berzina-Cimdina. Evaluation of maxillary bone quality before and after sinus lift operations using immunohistochemistry and computertommography // Int J Oral and Maxillofac Surg, SUPPL.(11); Abstracts of the 20th International Conference on Oral and Maxillofacial Surgery, November 1-4, 2011, Santiago, Chile.
6. Neimane L., Šalms Ģ., Skaģers A. Densitometriska analīze atrofiskam augšžoklim, kas pastiprinās ar kaulaudus aizvietojošiem materiāliem zobu implantācijas gadījumos // Tēzes, 62. lpp., Apvienotais pasaules latviešu zinātnieku 3. kongress un Letonikas 4. kongress, 24.-27.oktobris, 2011., Rīga, Latvija.
7. Šalms Ģ., Šalma I., Pilmane M., Skaģers A., Ločs J., Bērziņa-Cimdiņa L., Neimane L. Imūnhistoķīmijas un koniskā stara datortomogrāfijas metožu izmantojums kaula kvalitātes novērtēšanā pirms un pēc augšžokļa paaugstināšanas operācijām // Tēzes, 97. lpp., Apvienotais pasaules latviešu zinātnieku 3. kongress un Letonikas 4. kongress, 24.-27.oktobris, 2011., Rīga, Latvija.
8. Skagers A., Salma I., Pilmane M., Salms G., Feldmane L., Neimane L., Berzina-Cimdina L. Tripple confirmation for bioactivity of synthetic hydroxyapatite (Hap) in bony environement // Abstracts of TERMIS EU 2011 Annual Meeting Tissue Engineering&Regenerative Medicine International Society, June 7-10,2011, Granada, Spain.
9. Neimane L., Šalms Ģ., Skaģers A. Atrofiska augšžokļa pastiprināšana ar kaulaudus aizvietojošiem materiāliem zobu implantācijas pacientiem: densitometriska analīze // Tēzes, 329.lpp., RSU Zinātniskā konference, 14.-15.aprīlis, 2011., Rīga, Latvija.
10. Šalms Ģ., Neimane L., Skaģers A., Žīgurs G. Koniska stara datortomogrāfija augšžokļa dobuma pamatnes paaugstināšanas un zobu implantācijas

vēlīno rezultātu izvērtēšanā // Tēzes, 298.lpp., RSU Zinātniskā konference, 2010., Rīga, Latvija.

11. Salms G., Skagers A., Feldmane L., Pilmane M. Biopsy and 3D cone beam radiodensitometry in evaluation of hydroxyapatite (HAP)/tissue hybrid after maxillary sinus floor elevation // Book of Digest, p.1027, XX EACMFS Congress, September 14-17, 2010, Bruges, Belgium.
12. Salms G., Skagers A., Feldmane L., Pilmane M., Neimane L. Cone beam 3D and histomorphological evaluation of HAP/tissue hybrid after maxillary sinus floor elevation // Abstracts of the 7th congress of BAMPS, May 20-22, 2010, Riga, Latvia, p.30.
13. Salms G., Salma I., Skagers A., Berzina-Cimdina L., Pilmane M. Evaluation of bone regeneration after maxillary sinus floor elevation with HAP using Cone Beam volume tomography (CBVT) and histomorphological analysis // Book of Digest, p. 99, Biostar 2010.
14. Salms G., Salma I., Skagers A., Locs J. 3D Cone beam radiodensitometry in evaluation of hydroxyapatite (HA)/tissue hybrid after maxillary sinus floor elevation // Book of Digest, pp.198-199, The 9th International Conference on Global Research and Education, Inter-Academia 2010.
15. Salms G., Salma I., Skagers A., Berzina-Cimdina L., Pilmane M. Evaluation of bone regeneration after maxillary sinus floor elevation with HAP using Cone Beam volume tomography (CBVT) and histomorphological analysis // Book of Digest, p. 99, Biostar 2010.
16. Salms G., Feldmane L., Skagers A. Biopsy of biomaterial/host tissue composite after maxillary sinus floor elevation// Stomatologija, 2009; 6:34, Abstracts of the 10th Joint Symposium Rostock-Riga, May 07-10, 2009, Riga, Latvia.
17. Grybauskas S., Stacevicius M., Salms G. The use of bone substitutes for multisegment Le Fort I procedures // Stomatologija, 2009; 6:42, Abstracts

- of the 10th Joint Symposium Rostock-Riga, May 07-10, 2009, Riga, Latvia.
18. Šalms Ģ., Feldmane L., Skaķers A. Kaulaudus aizvietojošo biomateriālu integrācija augsžokļa dobuma pamatnē pēc biopsijas datiem // Tēzes, 205.lpp., RSU Zinātniskā konference, 2.-3.aprīlis, 2009., Rīga, Latvija.
 19. Salms G., Skagers A., Priednieks J., Zigurs G., Berzina-Cimdina L. Quantitative radiodensitometry for estimation of implant integration in atrophic posterior maxilla // Stomatologija, 2007; 1(4):39-40, Abstracts of the Baltic Dental scientific Conference, November 08-11, 2008, Riga, Latvia.
 20. Skagers A., Salms G., Salma I., Zigurs G., Pilmane M., Vetra J., Groma V., Berzina – Cimdina L. Augmentation of jaw with synthetic hydroxyl-apatite (HA) ceramics // Stomatologija, 2008; 10(5):14, Abstracts of the 3rd Baltic Scientific conference in Denistry, November 6-8, 2008, Vilnius, Lithuania.
 21. Skagers A., Salms G., Salma I., Zigurs G., Pilmane M., Vetra J., Groma V., Feldmane L. Application of synthetic calcium phosphate bioceramic materials in oral and maxillofacial surgery // Abstracts of the 7th Scanbalt forum & Scanbalt biomaterials days, September 24-26, 2008, Vilnius, Lithuania, p.44.

6.3 Congress and conference reports

1. Salms G., Salma I., Pilmane M., Skagers A., Sokolova M. Integration of calcium phosphate bioceramics in maxillary sinus floor // oral presentation, conference Bioceramics and cells for reinforcement of bone, October 18-20, 2012, Riga, Latvia.
2. Salms G., Salma I., Pilmane M., Skagers A., Locs J., Berzina – Cimdina L. Bone regenerative potential after HAp implantation in to maxillary sinus

- using immunohistochemistry // poster presentation, The 3rd TERMIS world congress, Tissue engineering and regenerative medicine, September 5-8, 2012, Vienna, Austria.
3. Šalms Ģ., Skaģers A., Bīgestāns A., Korņevs E., Lauskis G., Žīgurs G., Grieznis L., Ozoliņa S. Vēlīnie klīniskie rezultāti pēc vienmomenta augšžokļa dobuma pamatnes paaugstināšanas un zobu implantācijas // mutisks referāts, RSU Zinātniskā konference, 2012., Rīga, Latvija.
 4. Salms G., Salma I., Skagers A., Pilmane M., Locs J., Berzina-Cimdina L. Evaluation of maxillary bone quality before and after sinus lift operations using immunohistochemistry and computertommography // oral presentation, abstract, Int J Oral Maxillofac Surg, 2011; SUPPL.(11); Abstracts of The 20th International Conference on Oral and Maxillofacial Surgery, Santiago, Chile, November 1-4, 2011.
 5. Salms G., Skagers A., Feldmane L., Pilmane M. Neimane L. Biopsy and 3D cone beam radiodensitometry in evaluation of hydroxyapatite (HAp)/tissue hybrid after maxillary sinus floor elevation // abstract, Bruge; Electronically Poster No 110, September 16-19, 2010, Bruge, Belgium.
 6. Salms G., Skagers A., Feldmane L., Pilmane M., Neimane L. Cone beam 3D and histomorphological evaluation of HAp / tissue hybrid after maxillary sinus floor elevation // oral presentation, 7th congress of BAMPS, May 20-22, 2010, Riga, Latvia.
 7. Šalms Ģ., Neimane L., Skaģers A., Žīgurs G. Koniska stara dator-tomogrāfija augšžokļa dobuma pamatnes paaugstināšanas un zobu implantācijas vēlīno rezultātu izvērtēšanā // mutisks referāts, RSU Zinātniskā konference, 2010., Rīga, Latvija.
 8. Salms G., Feldmane L., Skagers A. Biopsy of biomaterial/host tissue composite after maxillary sinus floor elevation // oral presentation, 10th Joint Symposium Rostock-Riga, May 07-10, 2009, Riga, Latvia.

9. Šalms G., Feldmane L., Skaģers A. Kaulaudus aizvietojošo biomateriālu integrācija augsžokļa dobuma pamatnē pēc biopsijas datiem // mutisks referāts, RSU Zinātniskā konference, 2009., Rīga, Latvija.
10. Salms G., Skagers A., Zigurs G., Groma V., Berzina-Cimdina L. Granules of synthetic porous hydroxyapatite (HA) ceramics for restoration of alveolar bone // poster presentation, Functional materials and nanotechnologies, April 2-4, 2007, Riga, Latvia.
11. Salms G., Skagers A., Priednieks J., Berzina L., Cimdins R. Radiodensity of alveolar bone and floor of maxillary sinus after sinus lift with granules of synthetic hydroxyapatite // oral presentation, The 1st Baltic Scientific Conference in Dentistry, October 19-21, 2006, Tervis Spa, Parnu, Estonia.

7. ACKNOWLEDGMENTS

I would like to express my gratitude to my principal supervisors Dr. habil. med., Prof. *Māra Pilmane* and Dr. habil. med., Prof. *Andrejs Skāģers* for their supervision, advices, support and the great patience throughout the process of writing this thesis.

I thank employees of Anatomy and Anthropology Institute of RSU, especially lab assistant *Natālija Moroza* who practically helped me to effect morphological part of this thesis, and engineer *Jānis Brēde* for his assistance in taking microphotographs.

I am most grateful to Prof. *Uldis Teibe* and *Irēna Rogovska* for their help and advices during statistical processing and assessment of the research results.

I thank *Solveiga Ozoliņa* – the nurse of Institute of Dentistry for her help in patients' survey research.

I am grateful to *Ieva Greitāne* for her help in editing of this thesis.

I would like to express the greatest and dearest gratitude to my family for their invaluable support and true interest in this thesis.

8. ANNEX

QUESTIONNAIRE for dental implantation patient's poll

Dear _____

At Institute of Dentistry of RSU you have undergone _____
grafting and /or maxilla enhancement with bone substituting material

For assessment of dental implantation results please answer to the following questions by striking out wrong answers:

1. Have you lost any of the inserted dental implants?
No Yes
2. If any, how many _____ and when _____
3. Have you suffered any disorders at the grafting site (pain, bleeding)
No Yes
4. Is your prosthesis supported on implants stable (implant screw loosening)
No Yes
5. Have you experienced any disorders at maxillary sinus (elevated sensitivity, pain) No Yes
6. Have you had any nasal secretions (excluding acute infection, rhinitis)
No Yes
7. Are you satisfied with functionality of your implants
No Yes
8. Are you satisfied with aesthetics of your implant prosthesis
No Yes

9. Would you continue treatment at Oral and Maxillofacial Surgery Clinic of Institute of Dentistry of RSU

No Yes

10. How many times a year do you visit dental hygienist

Your comments

In case of any disorders related to implants or prosthesis supported on implants (loosening of prosthesis), for free consultations please refer to Institute of Dentistry, room 306 and for free X-ray exam please call 67455523.

In case of no disorders please be reminded to visit a professional oral hygiene at least twice a year, we recommend dental hygienists at Dental Prosthetics Clinic of Institute of Dentistry. Please call for application 67455165 or mobile phone 27002892.