



Faculty of Medicine

Pēteris Priedītis

**CAPABILITIES OF ULTRASOUND DOPPLEROGRAPHY
IN DIAGNOSIS OF LIVER FIBROSIS AND STEATOSIS IN
PATIENTS WITH CHRONIC VIRAL HEPATITIS C**

Summary of Doctoral Thesis for obtaining a Doctor of Medicine degree

Sub branch: radiology

Scientific Supervisors:

Habilitated Doctor of Medicine, Professor Gaida Krūmiņa

Habilitated Doctor of Medicine, Professor Ludmila Vīksna

Riga, 2011.

Thesis was developed in:

Riga Stradins University
VSIA “P.Stradina Clinical University Hospital”
v/a “ Infectology Center of Latvia”

Scientific supervisors:

Dr. habil. med., Professor **Gaida Krūmiņa**

Dr. habil. med., Professor **Ludmila Vīksna**

Reviewers:

Dr.med., Asoc. Professor **Ardis Platkājis**

Dr.med., Asoc. Professor **Jāzeps Keišs**

Dr.med. Professor **Algirdas Edvardas Tamosiunas** (Lietuva)

Defence of thesis will take place during the open session of Riga Stradins University Scientific Council of Internal Medicine on June 29th, 2011 at 3.00 pm. in Hippocrates auditorium of Riga Stradins University, Dzirciema str. 16, Riga.

Head of Scientific Council:

Dr. habil. med., Professor **Ludmila Vīksna**

Secretary of Scientific Council:

Dr. habil. med., Professor **Maija Eglīte**

Contents

1. Introduction.....	5
1.1. Importance of the Problem.....	5
1.2. Hypotheses Proposed for the Presentation.....	7
1.3. Objective of the Present Study.....	7
1.4. Tasks of the Present Study.....	7
1.5. Scientific Novelty of the Research and Its Practical Importance.....	7
1.6. Research Facilities and Equipment.....	8
2. Patients and Methods.....	9
2.1. Design of the Study.....	9
2.2. Patients Selection.....	9
2.3. The Equipment Used and Study Methods Applied.....	10
2.4. Data Statistical Processing.....	12
3. Results.....	14
3.1. Age and sex of the study patients.....	14
3.2. Incidence of VHDx Doppler waveforms.....	14
3.3. Relationship among type of liver blood flow and the patient's age and gender.....	15
3.4. Degree of liver fibrosis and its relationship with gender of patients.....	16
3.5. Degree of liver steatosis and its relationship with gender of patients.....	17
3.6. Relationship of liver blood flow with the degree of liver fibrosis.....	17
3.7. Relationship of liver blood flow with the degree of liver steatosis.....	22
3.8. Relationship of liver blood flow to activity of hepatitis.....	27
3.9. Relationships among body weight, liver fibrosis and steatosis.....	28
3.10. Relationship between blood flow in liver veins and patient's body weight.....	29
4. Analysis of the Results and Discussion.....	31
4.1. Subject of the discussion.....	31
4.2. Puncture biopsy technique and complications.....	31

4.3.	Reliability of the biopsy results.....	32
4.4.	Diagnostic potentialities of ultrasound imaging of liver fibrosis.....	33
4.5.	Diagnostic potentialities of ultrasound imaging of liver steatosis.	37
4.6.	Influence of body weight to hemodynamics of liver veins.	39
4.7.	Influence of inflammatory activity of liver veins.....	40
4.8.	Practical recommendations for ultrasonographic examination of diffuse liver damage and data evaluation.	41
5.	Conclusions.....	46
6.	References.....	47
7.	Reports a Publications by the Author	53
7.1.	Reports in Recognized Journals and Medical Magazines.....	53
7.2.	Scientific Reports in Congresses and Conferences	54
8.	List of Figures.....	56
9.	List of Tables	57
10.	Abbreviations Used.....	58

1. Introduction

1.1.Importance of the Problem

Chronic viral hepatitis C is widespread disease all over the world which causes such severe liver lesion as liver cirrhosis, oesophageal varices and their bleeding, hepatocellular cancer and liver failure, which often leads to liver transplant or death. Incidence of viral hepatitis in the developed countries fluctuates in the range of 1-3%, else even reaching up to 35% (Wasley A et al. 2000). Mortality of chronic hepatitis C virus patients is determined by liver cirrhosis which is the final result of progressive fibrosis. Therefore, assessment of liver fibrosis progress is prognostically important for each patient in determining the risk of life - threatening complications. Definition of optimal fibrosis screening strategy is especially important because nowadays there are available effective medicines for fibrosis mitigation. Such products for chronic viral hepatitis C are pegylated interferon and ribavirin (Poynar T et al. 2003, etc.), lamivudine for chronic viral hepatitis B, limitation of alcohol abuse for alcohol liver disease, etc. For assessment of liver morphological status as the gold standard liver puncture biopsy is still considered. However, it has several restrictions: a sufficiently high incidence of false negative results, risk of complications, discomfort and hospitalization costs (Nord JH 1982). For indirect assessment of the liver fibrosis development a series of laboratory tests are used. It is believed that the extracellular matrix serum markers are reliable indicators of liver fibrosis (Franck P. et al. 1992.). To diagnose fibrosis there are used combinations of several simple biochemical indicators, as protrombin index, serum gamma-glutamyltranspeptidase, apolipoprotein, etc. which form the test system Fibrtest, Fibrometer, Fibrospect etc. (Poynard T et al. 2004, Myers RP et al. 2003, Naveau S 2005, Cale P 2005, etc.). Their effectiveness is considered to be ambiguous and they are expensive for Latvia conditions. Despite the generally acknowledged limitations ultrasonography is still the most widely used method to diagnose liver cirrhosis, mainly due to its wide availability. Surface and echostructure alterations as well as periportal fibrosis are the key symptoms of liver cirrhosis, but sometimes their expression is poor or they are not present at all. Symptoms of portal hypertension, as ascites, splenomegaly and portocaval venous shunts appear only at the end-stages of the disease (Hakanir A et al. 2005). Liver fibrosis causes regional hepatic hemodynamic disturbances in the form of changes of flow velocity and

resistance index in the portal vein and hepatic arteries during Doppler ultrasound examinations. These changes can occur also in cases when common grey scale ultrasound (B mode) findings are unaltered; therefore, hepatic hemodynamic Doppler ultrasound examinations can play an important role in early diagnosis of liver fibrosis. A number of studies regarding chronic viral hepatitis C as well as liver blood flow impairment caused by liver fibrosis of different origins and liver cirrhosis comprehends analysis of various parameters of Doppler ultrasound measurements, as modified hepatic index, congestion index, arteriportal ratio (Hirata M et al. 2001 etc.), as well as portal hypertension index (Piscaglia F. et al. 1996., 2001). Their clinical assessment is ambiguous. One of the parameters analyzed in several studies is the direction of blood flow in hepatic veins. The Doppler waveform of hepatic veins in healthy subjects shows triphasic curve with a reverse peak, which reflects retrograde blood flow of v. cava inf. and hepatic veins during the right atrial systole. Increase in liver density and decrease in elasticity, as in the case of liver cirrhosis, results in disappearance of the retrograde flow and causes Doppler waveform to lose its reverse peak and to smooth out. This is one of criteria to reveal liver cirrhosis in Doppler ultrasound. However, there are several more factors which also affect blood flow in hepatic veins. They are alterations of physical parameters of liver tissue in cases of liver steatosis, intra-abdominal and intra-thoracic pressure as well as habitual properties of the human. Interrelationship of these factors, which may affect the Doppler ultrasound measurement data of hepatic veins in diagnosis of liver fibrosis and cirrhosis, so far has not been adequately investigated. Also, possibilities of use of Doppler ultrasound measurements and diagnostic importance of differentiation of fibrosis degree and prediction of the course of the disease have not been assessed. Data from published global studies are diverse, sometimes contradictory. In Latvia for imaging of liver disease there is widely used conventional ultrasonography. There is not any research on Doppler ultrasound examinations, their theoretical and clinical importance of liver disease held in Latvia.

1.2. Hypotheses Proposed for the Presentation

- 1) Liver fibrosis and steatosis, by altering hepatic density and elasticity, change the blood flow type in hepatic veins which is reflected in the shape of the Doppler waveform of hepatic veins.
- 2) Changes in Doppler waveform of hepatic veins in chronic hepatitis C virus patients are different in different stages of hepatic fibrosis and steatosis

1.3. Objective of the Present Study

To determine potentialities of Doppler ultrasound imaging in diagnosis of diffuse liver disease - fibrosis and steatosis in patients with chronic viral hepatitis C.

1.4. Tasks of the Present Study

- 1) To assess characteristic changes of Doppler ultrasound waveform for liver fibrosis in the right liver vein in patients with chronic hepatitis C and compare them with the degree of fibrosis assessed in the biopsy specimen.
- 2) To evaluate the effect of steatosis of different severity on blood flow types in hepatic veins and to characterize the typical alterations in Doppler waveform.
- 3) To determine influence of anthropometric factors on the degree of fibrosis, steatosis and the hemodynamics in liver veins for the groups of study and control patients.
- 4) To determine influence of inflammatory activity to the hemodynamics in liver veins.
- 5) To develop practical recommendations for ultrasound and Doppler ultrasound imaging assessment of diffuse liver lesions and considerate, informative liver biopsy under guidance of US.

1.5. Scientific Novelty of the Research and Its Practical Importance

- 1) The diagnostic sensitivity and specificity of Doppler ultrasound imaging in determination of liver fibrosis and steatosis of various severities in patients with chronic viral hepatitis C has been assessed
- 2) Correlation of particular anthropometric parameters with hemodynamics of liver veins has been found.

- 3) Recommendations developed for clinical practice allow expanding diagnostic informativity and quality of ultrasound imaging in primary investigation of chronic viral hepatitis C patients and evaluation of the disease course dynamics.
- 4) Demonstrating the rate of disease progression results of Doppler ultrasound imaging leads to reductions of number of repeated liver puncture biopsy.

1.6. Research Facilities and Equipment

The work was carried out in Chair of Radiology, Riga Stradins University. Clinical basesb were State Agency “Infectology Center of Latvia” and P. Stradin’s Clinical University Hospital. Investigations in the Infectology Center of Latvia were performed with the ultrasound systems Philips HDI 11 and Philips 15, in P.Stradin’s Clinical University Hospital – with Toshiba Aplio and Philips iU22. Histological investigation of the specimens was carried out in the Institute of Pathology of P.Stradins Clinical University Hospital. Statistical processing of the study data was performed in Chair of Physics at Riga Stradins University with the computer program SPSS 16.0 (company SPSS , USA).

2. Patients and Methods

2.1. Design of the Study

The research facilities are State Agency “Infectology Center of Latvia” and P. Stradin’s Clinical University Hospital. The study includes prospective analysis of anthropometric data of chronic viral hepatitis C patients and liver puncture biopsy results. Investigations were carried out in patients of Infectology Center of Latvia who were scheduled for the liver puncture biopsy in order to determine the stage and severity of the disease. Before performing the procedures there was received authorization from RSU Ethics Commission and written consent of every patient. The results were compared with the data from patients of P. Stradin’s Clinical University Hospital who came from various wards and who had screening abdominal ultrasound examination and had no anamnestic, clinical and laboratory indications on liver or heart disease.

2.2. Patients Selection

The study included a total of 216 patients - 117 males (54.2%) and 99 females (48.5%). The study group included 176 viral hepatitis C patients from Infectology Center of Latvia who in 2006. (95 patients) and 2009. (81 patients) underwent liver ultrasound examination and liver puncture biopsy. The number of males and females was 97 (55.1%) and 79 (44.9%) accordingly. The diagnosis of chronic hepatitis C was confirmed by the elevated ALT levels and positive anti HCV and HCV-RNA in serum.

The control group consisted of 40 patients from P. Stradin’s Clinical University Hospital who, for various reasons, underwent abdominal US imaging. The number of males and females was equal - 20. The average age of patients was 54.3 ± 17.8 years. The study included patients who had no anamnestic or laboratory data on liver or heart disease and who had a normal ECG and normal levels AST, ALT and bilirubin. US imaging did not show any evidence on liver disease. Patients with chronic pancreatitis were not included in the study.

2.3. The Equipment Used and Study Methods Applied

All ultrasound examinations and liver puncture biopsy was carried out by one and the same radiologist with more than 20 years of experience in liver ultrasonography and invasive manipulations under guidance of ultrasound. In the Infectology Centre of Latvia examinations were performed with ultrasound systems HDI 11 and HDI15 (Philips Health Care, Bothell, Wa.), using a convex multifrequency array probe (2.5 - 5 MHz) and selecting the operating frequency, which provides the best possible image quality. Doppler ultrasound examinations for hepatic were performed at the lowest possible pulse repetition frequency in order to obtain an optimal filling of hepatic veins and, avoiding aliasing artefacts, a qualitative Doppler waveform. In P. Stradin's Clinical University Hospital examinations were carried out on two ultrasound systems Aplio XG (SSA 790A, Toshiba Medical Systems Corporation, Japan) with convex array multi-frequency probe (frequency range 2 to 5.6 MHz), and iU22, (Philips Health Care, Bothell, Wa) with convex array multi-frequency probe (2 - 6 MHz), using similar technical principles of imaging parameter settings. The puncture biopsies were performed with an automatic biopsy device (Vitesse gun, Opti-Med GmbH, Germany) using 18 G (1.2 mm) cutting (core) biopsy needles. Tissue sample column length was set at the maximum, i.e. 2.2 cm.

Patients from the study group were hospitalized for puncture biopsy; the examination was performed either on the day of hospitalization or on the next day. In some cases, the patients were in hospital for a longer time to perform extended examination and to provide treatment. The study included all patients being investigated and meeting the inclusion criteria. Two cases failed to get a qualitative VHDx Doppler waveform; these patients were not involved in the study. Before puncture biopsy in all patients coagulogram was analysed and assessment of the potential risk of complications was performed. The puncture biopsy was contraindicated if deviation of blood coagulation was more than 10 -15% from the norm and there was presence of ascites. The study did not involve focal liver lesion patients, for whom puncture biopsy was performed to clarify the nature of these lesions. All patients included in the study had their body weight and height registered and body mass index (BMI) was calculated according to the equation $BMI = \text{body weight (kg)}/\text{height (m}^2\text{)}$. BMI less than 20 was rated as low, 20-25 as normal, 26-30 as elevated, > 30 as obese.

Investigations were performed on an empty stomach (fasting for at least 8 hours). Before the procedure patients received intramuscular sedative therapy (1 ml *Sol. Promedoli* 2% and *Sol. Sibasoni* 2 mg.) After the procedure the patients were ordained bed rest and monitoring of the medical staff until the next day morning.

In all cases the procedure started with a routine abdominal ultrasound examination according to the generally accepted standard protocol. When evaluating liver, sonographic signs of liver steatosis (increased liver echogenicity, deteriorated visualization of deep-located liver tissue and diaphragm were registered). Hepatic vein Doppler ultrasound imaging was performed in patient lying on the left side with raised right hand over the head. To minimize the impact of cardiac motion artefacts the right main hepatic vein was chosen for the examinations. Patients in whom the bottom right hepatic vein was found, also the record of Doppler waveform was performed to assess potential differences. In order to standardize examination conditions the waveforms were recorded during a light expiration after non-forced inspiration.

Doppler waveforms were classified into three groups: a normal waveform was presumed to be a triphasic curve with reverse peak, which reflects retrograde or hepatopetal blood flow in hepatic veins during atrial systole. Pathological waveforms were presumed to be biphasic curves which within the entire cycle showed antegrade, or hepatofugal, but with variable flow speed, and monophasic waveforms when the flow was steady and hepatofugal.

Liver puncture biopsy was made during the same examination under local anaesthesia using for the anaesthesia *Sol. Marcaini* 0.5% 5-10 ml. Tissue samples were taken from various depths of the right liver lobe guiding the needle through the intercostal space along *lin. axillaris ant.* or *media*. For each patient two visually qualitative specimens were yielded and fixed in formalin solution. In cases of fractionation of the resulting tissue sample or when it was small, the biopsy was repeated. In neither case more than four stabs were necessary to be performed. The histological assessment of the specimens was made in Institute of Pathology of P. Stradin's Clinical University Hospital by one and the same experienced pathologist, who knew the clinical diagnosis of the patient, but was neither familiar with the data from US imaging nor knew whether the patient was enrolled in the study. Tissue samples were processed according to a standardized liver biopsy histochemical visualization protocol which includes colouring with haematoxylin and eosin, with Masson's

trichrome method, Perls method and PAS method. Morphological changes were assessed using hepatitis activity semiquantitative score recommended by Knodell. For comparison in the study the common Knodell hepatitis activity index (HAI) and degree of hepatic fibrosis were used in following gradation: 0 - no fibrosis, 1 - mild fibrosis (spread of porto-portal fibrosis), 3 - moderate fibrosis (porto-portal or porto-central bridging fibrosis), 4 – cirrhosis.

Severiness of liver steatosis was expressed on a scale of four grades: no steatosis (affects less than 5% of hepatocytes), mild steatosis (affects 5% - 25% of hepatocytes), moderate steatosis (25 - 50% of hepatocytes) and severe steatosis (more than 50% of hepatocytes). Liver puncture biopsy was well tolerated. There were no major complications that require intensive therapy, blood transfusion or surgical intervention. In some cases patients experienced soreness at the puncture site, irradiation of the pain towards the shoulder, soreness during inspiration, which resolved on their own or after a single administration of analgesic medication.

Abdominal US imaging for the patients from the control group was performed according to the conventional standard protocol requiring fasting at a minimum of 8 hours. The study did not comprehend patients with US evidence on some of liver diseases, heart disease, pancreatitis, splenomegaly, ascites. Like with the study group patients, the examination was performed with a patient lying on the left side with the right hand raised overhead. Registration and evaluation of Doppler waveform of liver veins were similar to the study group. In the control group, for obvious reasons, liver puncture biopsy was not performed. All patients included in the study were assessed to record the body weight, height, and the body mass index was calculated.

2.4. Data Statistical Processing

The goal of the study data statistical analysis was to evaluate the data using appropriate descriptive and conclusive statistical methods to justify the role of the shape of VHDx Doppler curve in diagnosis of liver diseases.

The thesis includes calculation of generally established statistical parameters used in medical studies: 1) central trends (mean, median, etc.), 2) parameters describing data distribution (standard deviation, standard error of the mean, etc.).

To test the hypotheses there were used data appropriate tests - an independent - sample t test of two normally distributed data to compare the mean values, analysis of variance (ANOVA) to compare three or more independent samples of mean value of normally distributed data, Pearson chi-squared test for to establish cases of equality of distribution. If the data distribution defied normal probability distribution, nonparametric statistical methods were applied.

To assess closeness of the relationship between variables there were applied methods of correlation analysis.

In all cases the criterion of the significance level, which rejected the null hypothesis was $p < 0.05$. In some cases there were assessed confidence interval limits of 95%, too.

3. Results

3.1. Age and sex of the study patients

The study included a total of 216 patients - 117 (54.2%) males and 99 (48.5%) females. The patients were aged 18 to 78 years with the mean age of 41.6 ± 14.8 years. The average age of males and females was 40.0 ± 14.1 years and 43.5 ± 15.4 years, accordingly. Following the independent-sample t test, the average age for males and females did not show statistically significant difference ($t = 1.751$, $p = 0.081$). The study population included 176 patients, of whom 97(55.1%) were males and 79(44.9%) females. The average age was $38,6 \pm 12,5$ years. The control group included 40 patients, 20 females and 20 males aged 20 to 78, the average of 53.3 ± 17.2 years.

3.2. Incidence of VHDx Doppler waveforms

Triphasic shape of VHDx Doppler waveform in study group was established in 128(73%) cases, biphasic – in 26(15%) cases, monophasic – in 22(13%) cases.

In the control group of 40 patients triphasic waveform was recorded in 29(72.5%) cases, biphasic - in 7(17.5%) cases, monophasic - in 4(10 %) cases. Incidence of VHDx Doppler waveforms in the study is shown in Table 1. for the study group and Table 2. for the control group.

Shape of VHDx Doppler waveform	Number	%	Cumulative %
Triphasic	128	72,7	72,7
Biphasic	26	14,8	87,5
Monophasic	22	12,5	100,0
Total number	176	100,0	

Table 1. Absolute and relative frequency of VHDx Doppler waveform in the study group patients.

Shape of VHDx Doppler waveform	Number	%	Cumulative %
Triphasic	29	72,5	72,5
Biphasic	7	17,5	90,0
Monophasic	4	10,0	100,0
Total number	40	100,0	

Table 2. Absolute and relative frequency of VHDx Doppler waveform in the control group patients.

3.3. Relationship among type of liver blood flow and the patient's age and gender.

The average age of patients who showed triphasic VHDx Doppler waveform was $37,0 \pm 12.6$ years, the average age of patients with biphasic waveform was 42.96 ± 10.1 years, and for patients with monophasic waveform the average age was 43.7 ± 12.8 years.

Verifying the hypothesis on the uniformity of average age in different groups of VHDx Doppler waveform type groups with the analysis of variance (ANOVA), it was established that the average age within the groups showed statistically significant difference ($F = 4.714$, $p = 0.01$) and correlation (Spearman's rank correlation coefficient $r = 0.0320$, $p = 0.002$).

Among the males from the study group the average age of patients with triphasic, biphasic and monophasic VHDx Doppler waveform type was 35.6 ± 11.6 years, 42.9 ± 9.6 years and 41.5 ± 12.1 years, accordingly. The average ages of females were 38.5 ± 13.6 , 41.51 ± 11.51 and 43.0 ± 13.7 years, accordingly.

Statistically significant correlation between frequency of VHDx Doppler waveform types and patient age was found in males, (ANOVA $F=8,063$ $p < 0.001$). The average age of females with triphasic curve shape was lower (38.5 years) than of those whose curve was

biphasic (43.0 years) or monophasic (46.4 years), but the differences were not statistically significant, $p = 0.178$.

3.4. Degree of liver fibrosis and its relationship with gender of patients

In the study group liver fibrosis was not found, i.e., Knodell fibrosis score was 0 in 42(23.9%) patients. Of these, 19(46%) were females, 23(54%) were males. Mild fibrosis, i.e. Knodell score 1, was found in 96(54.5%) patients. Of these, 42(44%) were females, 54(56%) were males. Severe fibrosis, i.e. Knodell score 3, was found in 32(18.2%) patients. Of these, 15(47%) were females and 17(53%) were males. Cirrhosis, i.e. Knodell score 4, was found in 6(3.4%) patients. The numbers of females and males were equal - 3. The number of patients in groups with fibrosis is shown in Table 3.

Knodell fibrosis score	Number	%
F - 0	42	23,9
F - 1	96	54,5
F - 3	32	18,2
F - 4	6	3,4
Total number	176	100.0

Table 3. Absolute and relative distribution of patients in groups of fibrosis.

Pearson Chi-square test shows that frequency of fibrosis in all groups did not show statistically significant difference between men and women. ($\chi^2 = 0,167$; $df=3$; $p=0,983$)

3.5. Degree of liver steatosis and its relationship with gender of patients

The study group of patients with mild steatosis and patients with no steatosis was similar, 69 and 67 respectively. Moderate steatosis was found less frequently, in 31 patients. Severe steatosis was found in 9 patients. The relative frequency of steatosis is shown in Table 4.

Degree of steatosis	Number	%
None	67	38,1
Mild	69	39,2
Moderate	31	17,6
Severe	9	5,1
Total number	176	100,0

Table 4. Absolute and relative distribution of patients in groups of steatosis.

Comparison of the frequencies in males and females showed that it was similar in all severity groups. Pearson Chi-square test shows that the frequency of steatosis in all groups of males and females did not differ significantly ($\chi^2=5,325$; $df=3$; $p=0,150$).

3.6. Relationship of liver blood flow with the degree of liver fibrosis

The frequency of abnormal VHDx Doppler waveform in the study group patients without liver fibrosis, with mild to moderate fibrosis showed no significant differences (28.6%, 23.9% and 25%, respectively). A significant difference among frequencies of pathological

forms of Doppler waveforms was found in patients without fibrosis or with mild to moderate fibrosis, and in patients with severe fibrosis (83.3%), however, due to the small number of patients with severe fibrosis, this difference was not statistically significant. Frequency of abnormal VHDx Doppler waveform curves did not differ significantly in the control group (27.5%) and study in groups patients without fibrosis and with mild to moderate fibrosis (28.6%, 23.9% and 25%, respectively).

Frequency of abnormal curves VHDx curves in fibrosis groups is shown in Table 5. Figure 1 shows increment of frequency of pathological waveforms associated with the degree of fibrosis.

Knodell fibrosis score	Number of patients	Pathological VHDx waveform		95% CI limits	
		n	%	Lower	Upper
F- 0	42	12	28,6	17,2	43,6
F- 1	96	23	23,9	16,5	33,4
F- 3	32	8	25,0	13,3	42,1
F- 4	6	5	83,3	43,6	97,0

Table 5. Frequencies of pathological VHDx curves depending on the degree of liver fibrosis.

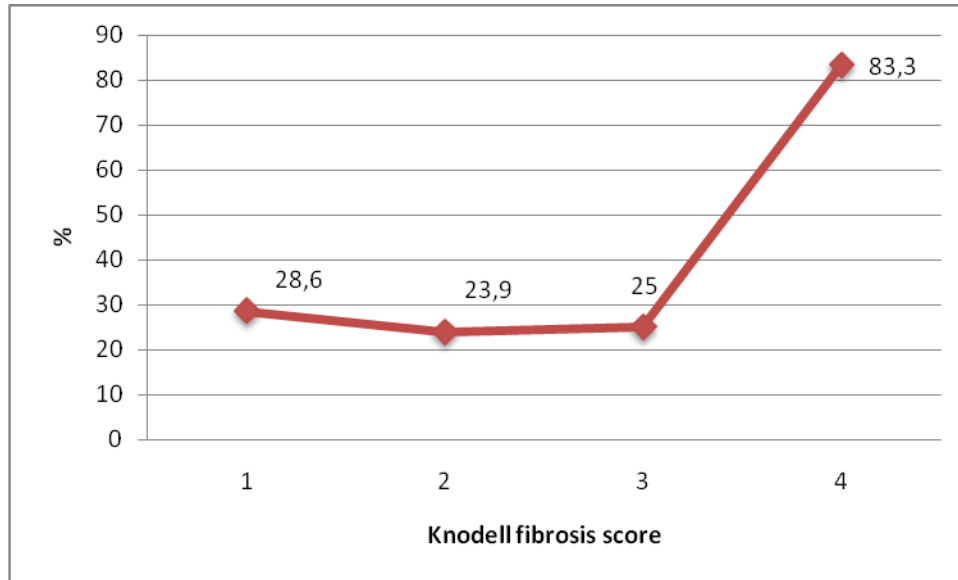


Figure 1. Pathological VHDx frequency curves depending on the degree of liver fibrosis.

To determine the effects of fibrosis on liver blood flow in liver veins in relationship to steatosis grade, frequency of VHDx Doppler waveform was analyzed in each steatosis group separately.

In patients without liver steatosis abnormal VHDx waveforms in F-0 F-1, F-3 and F-4 groups were found in 7 out of 21 cases, 6 of 37 cases, 1 in 7 cases and 2 of 2 cases (Table 6.). In the mild steatosis group such finding was in 3 of 15, 10 of 41, 2 of 10 and 2 out of 3 cases, respectively (see Table 7.). In the group of moderate steatosis abnormal VHDx waveform form was found in 1 case of 3, 5 of 9, 4 of 13 and 1 of 1, accordingly (Table 8.). In the severe steatosis group, severe fibrosis was found in none of the patients. Shapes of abnormal VHDx Doppler waveforms in the moderately severe fibrosis group was found in 1 case of 2, in the mild fibrosis group - in 2 cases of 4, in the patients without fibrosis - in 1 case of 3 (Table 9.). As seen from the tables, frequencies of abnormal curves in patients with fibrosis degree F-0, F-1 and F-3 did not differ in any of the steatosis groups. In the F-4 group frequency of abnormal waveform was higher in all groups, however, due to the low number of patients in each of them the difference was not statistically significant.

Type of VHDx Doppler waveform	Degree of liver fibrosis (Knodell)			
	F- 0	F- 1	F- 3	F- 4
Triphasic	14	31	6	0
Biphasic	5	3	0	1
Monophasic	2	3	1	1
Abnormal (%)	33,3	16,2	14,3	100,0

Table 6. Frequency of VHDx Doppler waveform types depending on the degree of liver fibrosis in patients without liver steatosis (n-67).

Type of VHDx Doppler waveform	Degree of liver fibrosis (Knodell)			
	F- 0	F- 1	F- 3	F- 4
Triphasic	12	31	8	1
Biphasic	0	3	1	2
Monophasic	3	7	1	0
Abnormal (%)	20,0	25,0	20,0	66,6

Table 7. Frequency of VHDx Doppler waveform types depending on the degree of liver fibrosis in patients with mild liver steatosis (n-78).

Type of VHDx Doppler waveform	Degree of liver fibrosis (Knodell)			
	F- 0	F- 1	F- 3	F- 4
Triphasic	2	9	9	0
Biphasic	1	5	0	1
Monophasic	0	0	4	0
Abnormal (%)	33,3	35,7	25,0	100,0

Table 8. Frequency of VHDx Doppler waveform types depending on the degree of liver fibrosis in patients with moderate liver steatosis (n-31).

Type of VHDx Doppler waveform	Degree of liver fibrosis (Knodell)			
	F- 0	F- 1	F- 3	F- 4
Triphasic	2	2	1	0
Biphasic	1	2	1	0
Monophasic	0	0	0	0
Abnormal (%)	33,3	50,0	50,0	0.0

Table 9. Frequency of VHDx Doppler waveform types depending on the degree of liver fibrosis in patients with severe liver steatosis (n-9).

Our results shows that the shape of VHDx Doppler waveform does not allow to differentiate patients without liver fibrosis from mild fibrosis as well as the mild forms from each other. When comparing patients without liver fibrosis with patients with severe fibrosis and cirrhosis, irrespectively of the degree of liver steatosis, the method sensitivity is 83.3%, specificity 71.4%, the positive predictive value (PPV) is 29.4%, and the negative predictive value (NPV) is 96.8%. Analyzing these parameters in the group of patients without liver steatosis, the sensitivity of the method is 100%, specificity 66.7%, PPV 22.2%, NPV 100%. The capability of the method to distinguish mild forms of fibrosis from medium and severe forms is burdened by the low frequency of abnormal waveform types in the group of moderate fibrosis. The total sensitivity of the potentiality of the method to differentiate patients without liver fibrosis from patients with moderate to severe fibrosis is 34.2%, specificity 65.2%, PPV - 52%, NPV - 54.5%. When analyzing these parameters in the group of patients without liver steatosis, the sensitivity of the method is 66.7%, specificity 70%, PPV 70%, NPV 30%.

3.7. Relationship of liver blood flow with the degree of liver steatosis

Abnormal VHDx waveform in the patients without steatosis was found in 16(23.9%) cases out of 67, in the patients with mild steatosis - in 17(24.6%) cases of 69, in the patients with moderate to severe degree of steatosis - in 11(35.5%) cases of 30, in the patients with severe steatosis – in 4(44%) cases out of 9. Correlations between the degree of liver steatosis and the VHDx waveform are shown in Table 10. and Figure 2.

Steatosis		Type of VHDx Doppler waveform		Total number
		Normal	Abnormal	
None	Rate	51	16	67
	% in the group of VHDx waveform	39,8	33,3	38,1
Mild	Rate	52	17	69
	% in the group of VHDx waveform	40,6	35,4	39,2
Moderate	Rate	20	11	31
	% in the group of VHDx waveform	15,6	22,9	17,6
Severe	Rate	5	4	9
	% in the group of VHDx waveform	3,9	8,3	5,1
Total number	Rate	128	48	176
	% in the group of VHDx waveform	100,0	100,0	100,0

Table 10. Type of VHDx Doppler waveform in relation with the degree of liver steatosis.

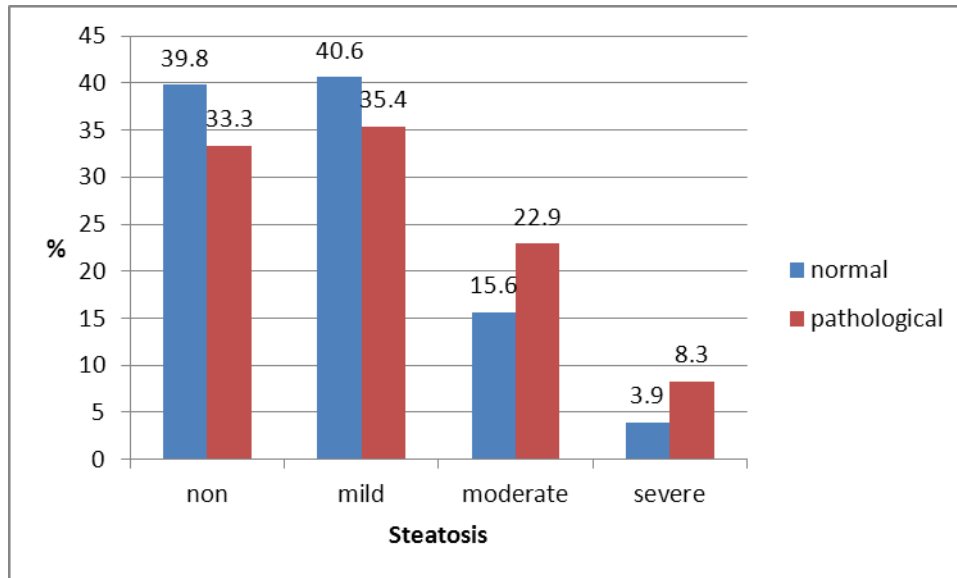


Figure 2. Proportion of patients according to the type of VHDx waveform depending on the severity of liver steatosis.

With the increase of the degree of liver steatosis, the frequency of abnormal VHDx waveform is showing an upward trend; although the increase is not statistically significant (Pearson's χ^2 tests $\chi^2 = 11,282$; $df = 6$; $p = 0.08$). Frequency of abnormal curves in groups of steatosis can be seen in Table 11 and Figure 3.

Steatosis	Number of patients	Pathological VHDx waveform		95% CI limits	
		n	%	Lower	Upper
S-0	67	16	23,9	15,3	35,3
S-1	69	17	24,6	16,0	36,0
S-2	31	11	35,5	21,9	54,5
S-3	9	4	44,0	18,9	73,3

Table 11. Frequencies of pathological VHDx curves depending on the degree of liver steatosis.

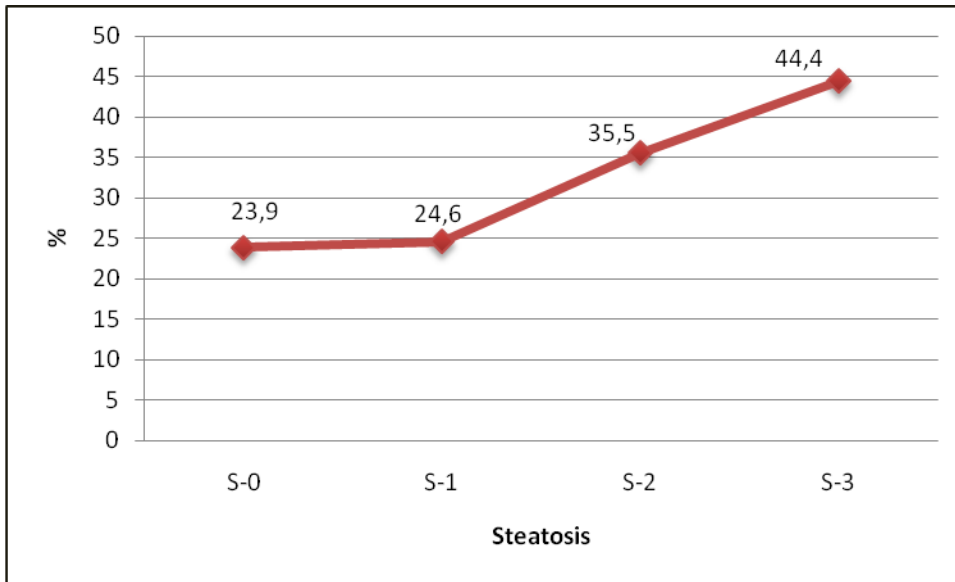


Figure 3. Increase of the frequency of abnormal VHDx Doppler waveform in relation with the degree of liver steatosis.

To determine the impact of steatosis on blood flow in liver veins, regardless of the degree of fibrosis, the frequency of pathological form of waveforms was evaluated separately in groups of patients without fibrosis and its mild form, as well as in patients with moderately severe form of fibrosis. With the increase of the degree of steatosis from S-0 to S-3 in the F 0-1 group of patients with fibrosis abnormal forms of VHDx waveform were found respectively in 13 cases of 58 (22.4%) in the S-0 group, in 13 cases of 56 (23.3%) in the S-1 group, in 6 out of 17 cases (35.3%) in the S-2 group and in 3 cases out of 7 (42.8%) in S-3 group. In patients with moderate fibrosis such findings were found in 1 case of 7 (14.3%), 2 cases of 10 (20%), 4 cases no13 (38.4%) and in one case out of two (50%), respectively.

Due to the small number of patients in the group of severe fibrosis or cirrhosis (n-6) such subjects were not included in the analysis. Distribution of VHDx waveform in groups of degrees of steatosis in relationship with the degree of liver fibrosis is shown in table 12. and 13.

Shape of VHDx waveform	Degree of steatosis (n-138)			
	S-0	S-1	S-2	S-3
Triphasic	45	43	11	4
Biphasic	8	3	6	3
Monophasic	5	10	0	0
Rate of abnormal forms, %	22.4	23.3	35.3	42.8

Table 12. Frequency of types of VHDx waveform in relation to the degree of liver steatosis in patients without liver fibrosis or those with mild forms (F 0-1).

Shape of VHDx waveform	Degree of steatosis (n-32)			
	S-0	S-1	S-2	S-3
Triphasic	6	8	9	1
Biphasic	0	1	0	1
Monophasic	1	1	4	0
Rate of abnormal forms, %	14.3	20	38.4	50

Table 13. Frequency of VHDx Doppler waveform types in relation to the degree of liver steatosis in patients with moderate liver steatosis (F-3).

Frequency of abnormal waveform in groups of fibrosis with the increase of the degree of liver steatosis shows a tendency to increase, but this rise is not statistically significant ($p < 0.05$). Increase of frequency of abnormal VHDx waveform in the groups of fibrosis according to the degree of steatosis is shown in Figure 4.

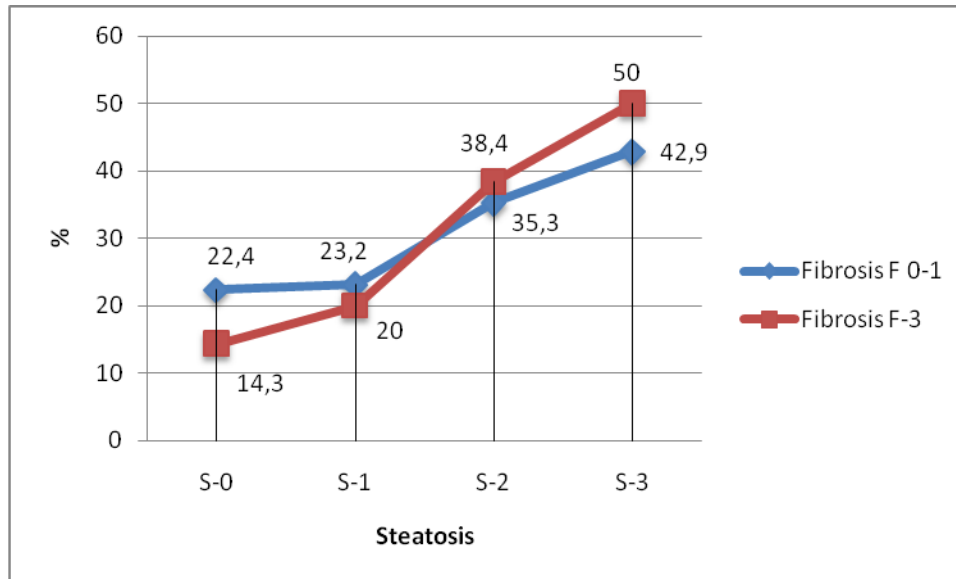


Figure 4. Increase of frequency of abnormal VHDx curves in relation to the degree of steatosis in the groups of fibrosis.

Sensitivity of Doppler ultrasound imaging of hepatic veins in detection of severe steatosis is 44.4%, specificity - 76.1%, PPV - 20%, and NPV - 91.1%. When the diagnostic amount gets increased to moderate and severe steatosis, the sensitivity decreases to 37.5%, remaining at the previous specificity. PPV increases to 48.4%, however, NPV decreases to 67.1%.

3.8. Relationship of liver blood flow to activity of hepatitis

All patients were assessed for hepatitis activity index (HAI) according to Knodell score. Its value ranged from 1 to 15. The most common HAI values were 6 - in 36 (20.6%) cases and 8 – in 32(18.3%) cases. The less common Knodell score values 15, 9, 7 and 1 were found in 1, 2, 3 and 3 cases, respectively. Compared to hepatitis activity index and frequency of VHDx waveform types, the correlation was not found, there is no statistically significant increase of abnormal Doppler waveform with the acceleration of activity of hepatitis.

Since the distribution of HAI does not conform to the normal distribution of probabilities to find HAI in VHDx waveform groups Kruskal-Wallis test of nonparametric statistics was used. It was established that median ranks (average spot arranged in row) in VHDx groups did not show statistically significant difference ($\chi^2 = 0,394$; $df = 2$; $p = 0,821$).

3.9. Relationships among body weight, liver fibrosis and steatosis

Comparing the patients' weight and degree of liver fibrosis we did not find any reliable correlation ($p = 0,271$), however, the small number of patients in the groups with severe fibrosis, cirrhosis and the group with significantly increased body weight or obesity must be taken into account.

For patients with severe hepatic steatosis a remarkably increased body weight or obesity was found significantly more often than in other groups of degrees of steatosis - in 5 (55.5%) cases out of nine. In patients without steatosis $MI > 30$ was found in 14 (13.1%) cases out of 107, in patients with mild steatosis - in 13(18.8%) cases out of 69, in patients with moderate steatosis - in 9(29%) cases out of 31.

Frequency distribution of varying severity of liver steatosis in groups of body mass index is shown in Table 14.

BMI	S-0		S-1		S-2		S-3		Total number	
	n	%	n	%	n	%	n	%	n	%
<20	3	4.4	1	1.4					4	2.3
20-25	45	67.2	33	47.9	12	38.8	3	33.3	93	52.8
26-30	15	22.4	22	31.9	10	32.3	1	11.1	48	27.3
>31	4	6,0	13	18.8	9	29,0	5	55.6	31	17.6
Total	67	100	69	100	31	100	9	100	176	100

Table 14. Severity rate of liver steatosis in relation to body mass index.

When determining the Spearman nonparametric rank correlation coefficient it was found that the correlation between the degree of steatosis and body mass index group is intermediate and statistically significant ($r=0,340$, $p < 0.001$).

Comparing the frequency of moderate and severe forms of steatosis in BMI groups it was found that moderate and severe hepatic steatosis in patients with significantly increased body weight occurred significantly more frequently than in patients with normal or slightly increased weight (See Figure 5.).

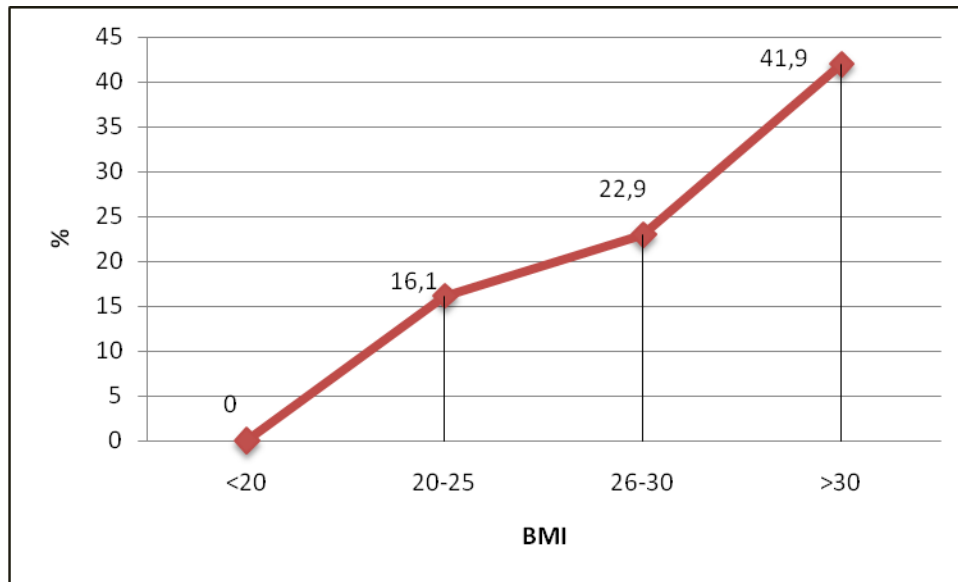


Figure 5. Increase in frequency of moderate to severe hepatic steatosis depending on body weight.

3.10. Relationship between blood flow in liver veins and patient's body weight

Body weight assessed according to body mass index in almost half of patients enrolled in the study was normal – 107(49.5%) cases, or high - 64 (29.6%) cases. Reduced body weight was found in 4(1.9%) patients, markedly increased weight or obesity was found in 41(18.9%) patients.

Checking the statistical hypothesis on body weight differences in male and female it was found that according to the independent - sample t test the mean values of BMI between males and females showed no statistically significant difference ($t = 0.622$, $p = 0.535$).

To assess the impact of weight on the blood flow type in liver veins, a comparison of VHDx waveforms and body weight was made. For patients with triphasic VHDx waveform, it was 25.77 ± 4.767 , with biphasic and monophasic waveforms - 26.73 ± 4.96 and 27.00 ± 5.005 , accordingly. The mean body mass index among VHDx waveform groups is shown in Table 15.

VHDx waveform	Number	Mean MI	Standard-Deviation	Standard-Error	95% Confidence interval		Min	Max
					Lower limit	Upper limit		
Triphasic	128	25,77	4,767	0,421	24,94	26,61	19	43
Biphasic	26	26,73	4,960	0,973	24,73	28,73	20	36
Monophasic	22	27,00	5,005	1,067	24,78	29,22	20	40
Total number	176	26,42	4,890	0,333	25,77	27,08	19	43

Table 15. Type of VHDx waveform in relation with the average body mass index (kg/m²).

Analyzing frequency correlations between patients' body weight and types of VHDx waveforms it was found that frequency of abnormal Doppler waveform does not correlate with body mass. In patients with normal and abnormal waveforms BMI showed no statistically significant difference ($p = 0.364$).

4. Analysis of the Results and Discussion

4.1. Subject of the discussion

The actuality of the selected research theme was, on the one hand, the increasing morbidity and on the other hand – potentials of new medicinal treatment methods. The number of chronic VHC patients in the last decade in Latvian has been steadily growing. If in 2002 this diagnosis was established in 506 patients, in 2006 and 2007 it was found in 1339 and 1611, respectively. A small decrease in number was observed in 2008 – 2009. (1352 and 1271 cases)

Chronic viral hepatitis B and C, together with alcoholic steatohepatitis and non-alcoholic fatty liver disease are the main causes of progressive liver damage leading to cirrhosis, liver failure, bleeding and liver cancer. Progressive fibrosis is the major pathogenic mechanism, leading to development of the disease. Assessment of severity of fibrosis, i.e., stage of disease, is of fundamental importance for ruling the treatment tactics. Currently in the world liver puncture biopsy is considered to be the main method or the "gold standard" for verification of fibrosis. Although the method is highly informative, it has some disadvantages: it is invasive and associated with a risk of certain complications, limitations in diagnostic accuracy and follow-up. It leads to searching for non-invasive diagnostic methods, which should diminish amount of liver biopsy and potentially replace them. Ultrasonography suppose to be one of such method.

4.2. Puncture biopsy technique and complications.

Liver puncture biopsy in our study was used as “golden standart” for assessment of other diagnostic techniques. As the most important factors increasing complication risk of puncture biopsy are considered to be patients’ age, operator’s experience, needle thickness and the number of sticks (Buscarini E, Di Stasi M 1999). In our study all puncture biopsies were performed by one and the same doctor - the author of the research. For the biopsy we chose 1,2 mm (18G) needle, which, although classified as a needle of relatively large bore ($\emptyset > 1$ mm), belongs to the group of thinner needles suitable for liver biopsies in diffuse liver disorders. For comparison, the diameter of needles used by Bravo and co-authors, for

instance, was 1.4 to 1.8 mm (Bravo AA et al. 2001). 2001.). There was nor lethality in our study, neither major complications nor strong pain during the puncture, which are frequently present in patients with liver tumors. (Cadarnel JF et al. 2000).

4.3. Reliability of the biopsy results.

Diagnostic accuracy is one of the factors limiting reliability of liver biopsy. In our study the morphological analysis was made by one and the same experienced morphologist, who analyses more than 1,000 liver specimens per year. Our study comprehends analysis of such morphological parameters characterizing the state of the liver, which, according to data from literature, show the lowest inter- and intraobserver variability. That is Knodell fibrosis score and level of steatosis. According to the French Cooperative Study Group METAVIR report, (1994.) only the cirrhosis and portal fibrosis had higher correlation: coefficient of agreement 0.91 and 0.8 respectively. Correlation evaluated as almost perfect. For Knodell fibrosis score and level of steatosis coefficient of agreement were 0.78 and 0.63 evaluated as significant. Third parameter used in our study was Knodell HAI with coefficient of agreement of 0.48, evaluated as moderate. Thereby main morphological parameters used in our study should be estimated as highly reliable.

Another limiting factor of diagnostic accuracy is sampling error. Results of morphological analysis are highly dependent of size and amount of samples, and of puncture site. For the biopsy we chose 1,2 mm (18G) needle with 22 mm sample length. Sample size of 25 mm were assessed as optimal in several works. (Bedosa P et al. 2003, Colloredo G et al. 2003). Authors conclude, that extension of sample length over 25 mm failed to increase the effectiveness; it remains at 75% correlation level. Shorter tissue columns (1 to 1.5 cm) or smaller diameter of the needle (1 mm) leads to underestimation of inflammatory activity and severity of fibrosis. For a reference point authors use liver resection material. By contrast, Hohlund with co-authors in early research (Hohlund P et al., 1980) recognizes 15 mm long tissue samples to be sufficiently valuable for diagnostics. As a reference point the authors used 25 mm long specimens, not taking into account any inaccuracies possible even in them. Sample size used in our study provides the sufficiently high diagnostic accuracy. Increasing of the size should lead to higher risk of complications.

Spread of disease is not equal in all parts of liver. Puncture site and number of samples have influence to the result of analyses. In our study in all cases specimens were sampled from different sites of the right liver lobe, guiding the needle through a single puncture hole. Biopsies were repeated until intact and visually qualitative tissue columns were yielded, but in none of the cases their number was smaller than two or exceeded four. The histological result was determined assessing all tissue specimens.

In a number of studies there was analyzed the influence of the puncture site and the number of specimens on the histological results. In an early study Maharaj with co-authors (Maharaj B et al. 1986) by means of biopsy in cirrhotic patients took three samples from different sites through a single puncture hole. A similar result in all three samples was found in only 50% of cases. In another study (Abdi W et al 1979) by means of biopsy *post mortem* (Latin), their results were compared with the assessment of macro-specimens. Reproducibility in case of one biopsy tissue specimen was found in 16 cases from 20 (80%), while in case of three samples it was 100%. In the research of Baunsgaard and co-authors (Baunsgaard P et al. 1997) evaluation of two biopsy specimens matched only in 36 cases out of 50 (72%). Regev and co-authors assessed biopsy materials obtained from both lobes during the laparoscopic operations. Difference in disease stage at least in one level was found in 33.1% of cases, and in grade of disease in 24% of cases. Thus, in our study, the reliability of histological assessment is similar to the results from other authors. Possible uncertainty of the method could reach 20% -30%.

4.4. Diagnostic potentialities of ultrasound imaging of liver fibrosis

Doppler spectral waveform of liver veins is recognized to be the most useful parameter of ultrasound imaging for assessment of liver cirrhosis and fibrosis in the numerous researches is Dopplerography of hepatic veins (Schneider et al. 2005, O'Donohue et al. 2004, Bernatik T et al.2002, C. Aube et al. 2004, Dietrich CF et al.1998, von Herbay et al.2001). In healthy humans liver is a flexible organ which is compliable to pressure changes in VCI and liver veins caused by functions of the right atrium of the heart. This reflects on the shape of Doppler spectral waveform and can be seen as a reversal of flow during the heart cycle. Advanced architectural changes of liver tissue with development of cirrhosis

with increase of fibrosis and fat tissue growth reduce this compliance and leads to flattening of the curve (Bolondi L et al.1991, Colli A et al 1994).

Our study aimed to clarify the extent to which these changes in the Doppler spectral waveform show course of development of liver fibrosis and its severiness. The measurements were performed on the right hepatic vein (VHDx) to reduce the movement-related artefacts caused by heart motions. Triphasic waveform was characteristic to patients without fibrosis, as well as for patients with mild to moderate form of fibrosis. Their frequency within these groups did not differ. In the fibrosis group of F0, F1 and F3 it was 71.4%, 76.9% and, 75%, accordingly.

Certain amount of abnormal waveforms was found in all groups of patients with fibrosis. In the F0 group it was in 28.6% of cases, in the group of mild fibrosis - 23.9% of cases and in the group with moderate fibrosis - in 25% of cases. A similar frequency of abnormal waveforms was also found in the control group - 27.5%.

In order to exclude the influence of liver steatosis, we evaluated frequency of flattened waveform in each group of steatosis separately. In all groups the incidence of flattened waveforms in patients without fibrosis and with mild or moderate form of fibrosis did not significantly differ ($p>0,05$). Small number of patients with severe steatosis didn't allow perform precise analysis of this group.

Thus, the study shows that the Doppler ultrasound imaging of liver veins does not allow differentiating between mild and moderate forms of liver fibrosis from each other or between mild fibrosis and conditions without fibrosis. In our study Knodel fibrosis severity grading system was used in which mild fibrosis was concerned in case of portal expansion of the fibrosis, and as fibrosis of moderate severiness bridging fibrosis (porto-portal or porto-central) were concerned. In our opinion, the magnitude of the changes is too small to significantly increase the overall hardness of the liver tissue and to significantly reduce their ability to resist to wall pulsations of liver veins caused by the heart.

Other studies on this issue are controversial. Similarly to our study, differentiation between degrees of fibrosis was unsuccessful also for Bernatik with colleagues (Bernatik T et al. 2002). Significantly more abnormal waveforms in case of moderate fibrosis were found by Schneider (Schneider et al.2005) – in 38.2% of cases, while in patients with cirrhosis they were found by authors only in 52.9% of cases. Increase of abnormal waveform with an

increase of severity of hepatitis is shown in Lim study (Lim A et al. 2005) in 29%, 55% and 60%, respectively. In this study, some degree of fibrosis is not isolated, but the hepatitis activity index is estimated as a whole. Most studies on the subject for morphological assessment of liver use other scoring systems: usually METAVIR or its modification, where the degree of fibrosis is divided more subtly than in the Knodel system used by us. This could lead to different types of abnormal waveforms in groups with moderately severe fibrosis. However, in all the analyzed studies, including our study, Dopplerography of liver veins is not enough efficient in diagnosis and differentiation of early forms of fibrosis, as well as in the differentiation between mild fibrosis and healthy liver.

Within the group of severe fibrosis/cirrhosis abnormal waveform was found significantly more frequently – in 83.3%. These results suggest that revealing of mild fibrosis and differentiation between them according to liver vein Doppler ultrasound data is not possible while cirrhosis is characterized by such form.

The sensitivity of ability to differentiate F0-1 from F-4 in our study is 83.3%, specificity - 71.4%, the positive predictive value (PPV) - 29.4%, the negative predictive value (NPV) - 96.8%.

With regard to the detection of cirrhosis such results correlate which the data from other authors Sensitivity, specificity, PPV and NPV in detecting cirrhosis in the study of A. Colli (Colli A et al. 1994) were respectively 75%, 78%, 60% and 88%; in the study of K. Arad (Arad, K. et al. 1997) the sensitivity and specificity was 73% and 100%, in the study of Christoph Aube (Aube Ch. et al. 2004) the diagnostic accuracy of this study was 76.8%. Critically comparing the results of the study with data from other authors it must have noted that our study results are influenced by the small number of patients with cirrhosis.

In all studies in certain amount of cirrhotic patients triphasic waveform was registered, in some cases their frequency can reach up to 50% (Bolondi L.). In our study, it was smaller, 22.7% of cases.

In our study within the control group abnormal waveforms were present to 27.5% of patients, which differs significantly from those of other trials. Bolondi (Bolondi L. et al. 1991) reported triphasic waveform for healthy subjects in all 100%. The authors have not provided the control group selection criteria. O'Donohue (O'Donohue et al. 2004.) detects abnormal curve in 2.1% of cases, Oguzkurt with co-authors (Oguzkurt L et al. 2005) – in 2%

of cases, Hamath with colleagues (Hamath N et al 1997) – in 4.7 % of cases. In studies of Barkat (M Barkat 2004), Arad (Arad K et al 1997) and von Herbay (von Herbay et al. 2001) all subjects showed triphasic curve. Those studies differ from data by Dieterich (Dieterich CF et al.1998). Abnormal waveform within the control group of 74 patients was found in 25% of cases. For understandable reasons, no control group patient morphological investigation has been verified. Mean age of patients ranged from 32 (Barkat M) to 47 (Bolondi L.). In our study it was 53.3 years. In all studies, the control groups consisted of volunteers, sometimes also hospital staff (O'Donohue), who did not suffer from heart or liver disease, alcoholism and, in most cases, presented normal liver biochemical parameters. One study indicated that the patients had normal liver US (Barkat M), other studies do not present such message. By contrast, in Dietrich's (Dieterich CF) study, all 19 patients with abnormal waveform had elevated liver echogenicity indicative of steatosis. In our study selection criteria of the control group were similar, but patients came from the inpatient centre. Medical reasons, i.e., the diagnoses, were different, in all cases not related with eventual liver diseases, but, of course, without morphological evidence. Since changes in liver veins in Doppler ultrasound are quite frequently found in liver diseases, a question rises on treatment strategy if such waveforms are found in patients without known liver or heart disease. This issue was focused by the Danish researcher Pedersen and colleagues (Pedersen JF et al. 2005).The authors during two-month period recorded liver vein waveforms for all patients who were examined with abdominal US. Abnormal shape of the waveform was found in 31% of cases (in 43 of 139 patients). In further analysis 26 of them were found a variety of liver diseases. Of the remaining 17 patients three presented gallstones, two - liver cysts, but no changes were found in 12 cases. In our study, control patients with abnormal waveforms were not further analyzed. Therefore, it cannot be excluded that at least part of those patients had an undiagnosed liver lesion, possibly, liver steatosis, which might have been a reason for abnormal Doppler spectral waveform. It must be taken into account that in our study the age of control patients was higher.

To sum up our data and the results from other similar studies it can be concluded that abnormal shape of Doppler waveform of liver veins reliably indicates the likelihood of liver disease. It is a characteristic symptom of liver cirrhosis, which sometimes occurs even before cirrhotic stages of the disease, but does not allow differentiating between them.

4.5. Diagnostic potentialities of ultrasound imaging of liver steatosis.

Liver steatosis, which generally is the most common type of liver damage (Marchesini G et al.2006) in chronic VHC patients is found significantly more frequently than in average population , around 50% to 75% of cases. It is a significant factor influencing the course of the disease and its prognosis, therefore proper attention shall be addressed to the diagnosis of steatosis (Fiore G et al.1996, Hourigan LF et al. 1999, Rubbia-Brandt L et al.2004, Lonardo A, et al. 2006).With increasing amount of fat in the liver alterations in liver tissue elasticity and increase in intrahepatic pressure can be expected which could affect the type of blood flow in liver veins and the relevant Doppler imaging results

In our study in patients with mild steatosis or no steatosis at all abnormal waveforms were found in the same frequency, at around 24% of cases. Thus, accumulation of fat in less than 25% of liver cells do not significantly affect tissue hardness and elasticity, they retain the ability to respond to pulsations of liver veins. Increase of steatosis severity indicates a tendency for increase of frequency of pathological forms, although the level of statistical significance is not achieved ($p = 0.08$). In the group with moderate steatosis this rate is 35.5%, in the group of patients with severe steatosis - 44%.

Our results are in line with research data from other investigators described in literature. A very strong impact of steatosis on the flow in liver veins is found by Dieterich (CF Dieterich et al. 1998). Patients with severe liver steatosis (> 50% of hepatocytes were affected by fat), monophasic Doppler waveform was found in 44 cases out of 49 (90%), and only in 3 cases out of 57 (5%) - in patients with mild steatosis (fat affected <25% hepatocytes), or no steatosis at all. Types of the waveform did not correlate with histological form of steatosis: micronodular, macronodular or mixed. In this study, abnormal waveforms in patients from the control group were found in 19 cases out of 75 (25.3%). In all these cases ultrasound imaging revealed increased liver echogenicity, which indicated steatosis, while the remaining 56 patients had normal US results. In those cases steatosis, of course, was not proven. In the study the degree of steatosis was not associated with the degree of liver fibrosis, which also may affect the flow type in liver veins. Steatosis as the single liver disease was revealed in 11 patients in the study of von Herbay (von Herbay et al. 2001). Abnormal shape of VH waveform was found in three patients (27%). The severity of steatosis in this study has not been determined. Impact of steatosis on the flow of liver veins

was evaluated also by Schneider and co-authors (Schneider ARJ et al.2005). The authors analyse VHC patients with various degrees of liver fibrosis and steatosis, but they were not analysed separately. Frequency of abnormal VHDx curves had a better correlation with the degree of steatosis than with liver fibrosis. In patients with mild steatosis abnormal shapes of waveforms were found in 25.5%, in patients with severe steatosis 90.2%.

Sensitivity of detection of severe steatosis in our study was 44,4%, specificity 76,1%, PPV 20%, NPV 91,1%

Sensitivity and specificity of Doppler ultrasound in evaluation of severe steatosis in Schneiders study (Schneider ARJ et al.2005) was 88.2% and 74.5%, accordingly. The authors concluded that the triphasic shape of the curve reliably excludes opportunity of presence of severe steatosis, while the monophasic or biphasic shape are high sensitive to reveal such expressed steatosis. The drawback of the method is the low PPV - 36.6%. In our study, in patients with severe steatosis the frequency of abnormal shape of waveforms is lower than in a number of listed trials. This could be explained by different grading system of steatosis severity, which considered a severe steatosis to be of > 66% involvement of hepatocytes. In another study the threshold of involvement of hepatocytes in expressed steatosis is considered to be 33% (Brunt EM et al.1999). Results in the group of severe steatosis are affected by the small number of patients in this group.

To assess the impact of steatosis on flow in the liver veins, regardless of the other major factor - liver fibrosis, the frequency of pathological shapes of waveforms was analyzed in patients with equal degree of fibrosis. Such analysis was found only in McPherson's study (2009) on the use of MRI to diagnose liver steatosis. In conjunction with ultrasonography, we did not find any such data available from earlier studies. Both in the group of patients without fibrosis or mild form, or in the group with moderate fibrosis the frequency of abnormal shape of waveforms shows a trend to raise with the increase of the severity of steatosis, although in none of the groups their frequency exceeded 50%. The number of patients with cirrhosis in the study was 6, which was too small to be included in the analysis.

Thus, from our study it can be concluded that liver steatosis is an important factor influencing VH hemodynamics, which generally corresponds to the data from other studies. Liver steatosis in VHC patients is found significantly more frequently than over the average population; it is an essential factor to predict the course of the disease and its prognosis. In

our study, severity of fibrosis and steatosis significantly correlated, which increases diagnostic importance of Doppler imaging of liver veins.

4.6. Influence of body weight to hemodynamics of liver veins.

Traditionally it is believed that the flow in hepatic veins is affected by intra-abdominal pressure. One of the most important determinants of this pressure is the body mass.

In our study for patients with triphasic VHDx waveform the average BMI is 25.77 ± 4.7678 , with a biphasic waveform - 26.73 ± 4.96 , with monophasic - $27.0 \pm .5.005$. Body mass index does not show significant correlation with the type of VHDx waveform (Spearman's rank correlation coefficient 0.132, $p = 0.103$). Body mass does not show significant impact on the flow type in liver veins

Effects of body mass on blood flow in the liver vasculature are relatively little analyzed. O'Donohue (O'Donohue et al. 2004.) in his study analyzed flow parameters in the liver artery and in the portal veins of healthy individuals. Body mass index did not correlate neither with RI in the hepatic artery, nor with the flow rate in the portal vein, nor with its diameter. Hepatic venous flow types in relation to body obesity were analyzed by Karabulut and co-authors (Karabulut N et al. 2004).The authors compared VHDx curves for patients with normal weight (BMI <25) and obesity (BMI> 30). Abnormal wave form frequency was 1.1% (one in 84) and 45.1% (46 out of 102), respectively. Authors explain this difference with liver steatosis which in the study is evaluated according to US parameters however, they are not sufficiently accurate indicators. The study does not include liver morphological analysis. The authors do not find independent relationship between the body and the type of the waveform.

It can be concluded from this studies, that increased intraabdominal pressure created by high body weight or obesity is not large enough to alter blood flow in the liver.

Another factor influencing intra-abdominal pressure is breathing. In the deep inhalation it is increased, so the flow in liver veins should level. In our study respiratory effects of VHDx curve have not been analyzed although differences in waveform types in different respiratory phases were observed repeatedly. To reduce the potential respiratory impact on the results, all Doppler examinations were made in a single respiratory cycle phase

- in a light expiration following an easy inspiration. In most studies on this problem authors have done likewise.

Special investigation on the dependence of the respiratory phase on the flow type in the liver veins has been carried out by Altinkaya with co-authors (Altinkaya N et al. 2010). The study analyzes 100 patients without known heart or liver disorders, with BMI <25, without history of alcoholism or other conditions that could affect flow in the liver veins. During normal breathing triphasic VHDx curve was found in 93% of cases. During slight expiration it was 91%, during deep inspiration the frequency of normal waveform decreased to 80%. Flow rate in the liver vein during normal breathing was found to be greater than during expiration and during expiration greater than during deep inspiration. Similar results were also reported by Teichgraber with co-authors (Teichgraber UK et al. 1997).

The role of intra-abdominal pressure on hepatic circulation is also demonstrated by the change of the shape of waveform during pregnancy. Roobottom and co-authors (Roobottom CA et al. 1995), in their study analysed 75 women in early time of pregnancy (up to 20 weeks), and found triphasic VHDx waveform in 64% of cases. During the second trimester, 20-30 weeks – in 32% of cases, after more than 30 weeks - in only 20% of cases. Such results demonstrate the role of intra-abdominal pressure, which expresses during later periods of pregnancy. They stimulate to look for some additional determinants of liver venous flow, as during early pregnancy, when the uterine volume effect on the pressure in the abdomen is still very little, the frequency of flattened waveforms (36%) significantly over exceeds normal values in all other studies. There were no pregnant patients in our study.

4.7. Influence of inflammatory activity of liver veins.

A separate, specific factor which might affect liver hemodynamics, is inflammatory activity. In our study to clarify the role of inflammatory activity frequency of abnormal VHDx waveforms were compared to HAI together. To reduce the potential impact of fibrosis on the result, the frequency of waveform types was compared apart from the sum of necroinflammatory parameters. Correlation was found in none of the cases. Spearman's rank correlation coefficient Knodell HAI totally was 0.047, $p = 0.533$. Sum of the necroinflammatory parameters was 0.04, $p = 0.603$. It can be concluded that the impact of

inflammatory and necrotic processes on the physical state of liver is not high enough to cause increase of resistance against hepatic venous pulsations.

Results of several other studies are in line with our. Schneider with co-workers (Schneider ARJ et al. 2005) assessed the inflammatory activity on the flow parameters in the portal vein and found correlation neither with the flow rate in the portal vein nor with pulsatility of the spectrum. Similar results were found also in the study by Lim (Lim AKP et al. 2005), assessing the type of Doppler spectral waveform of hepatic veins in patients with cirrhosis, moderate or severe hepatitis and mild hepatitis. Abnormal waveforms within the first and the second groups were found with more increasing frequency, to 60% and 56% of cases, than within the third group, in which abnormal shape of waveforms was observed in 29% of patients. In this study, Ishak semiquantitative scoring system was used to assess the liver condition. Hepatitis activity indices were not separated from the degree of fibrosis, i.e., it was not possible to assess independent effect of inflammatory activity. Detailed analysis of relationship between inflammatory activity and Doppler waveform was analyzed by Dieterich (Dieterich CF et al. 1998). In total, the flow of hepatic veins did not correlate with hepatitis activity index according to Knodel score, but splitting it into components the authors found a correlation with the degree of periportal changes (with or without the occurrence of hepatocellular bridge-like necroses). Other inflammatory factors in relation to the flow of liver veins were not observed. The authors found no explanation to this phenomenon. No correlation between inflammatory activity and type of VHDx waveforms was suggested also by Haktanir (Haktanir A et al. 2005).

From all abovementioned facts it must be concluded that hepatitis activity, namely, the degree of the disease, has no significant effect on hemodynamics in liver veins, and this method is not applicable to assess inflammatory activity.

4.8. Practical recommendations for ultrasonographic examination of diffuse liver damage and data evaluation.

No one specialty in modern medicine can exist without imaging diagnostic. Hepatology also is not an exception. Range of radiology methods and their importance in hepatology is of continuous change. Puncture biopsies, which for long time have been the most accurate method, are getting successfully replaced with alternative modalities. Liver

fibrosis is effectively determined with complex assistance of the pulse elastography and laboratory tests. MRI provides the maximum accuracy in assessment of liver steatosis. However, these methods are expensive and of limited availability, and hence efficiently applied only in highly specialized centers of hepatology. Wide incidence of diffuse liver diseases, in particular - steatosis, raises necessity for a simple and readily available diagnostic methods for primary selection.

In most cases the first radiological evidence experienced by the patient is ultrasonography. Many trials have offered a large number of different investigative techniques, the diagnostic efficacy of which is variable. From this range for routine tests the most effective ones must be chosen. Effectiveness of them is determined by sufficiently high diagnostic accuracy with a relatively low time capacity and technological simplicity, which does not require complicated additional hardware or software.

Requirements for the equipment.

Examinations must be done with a standard ultrasound system equipped with transducers for examination of abdominal and superficial structures with average frequencies around 3.5 MHz and 7.5 MHz, respectively. High-definition color Doppler and pulsed wave spectral Doppler imaging capabilities are required. Procedure must be performed in a sufficiently short time so that they might be used for daily workflow.

Aim of examination.

Based on our study and the literature analysis recommendations are suggested for routine ultrasound examinations that would allow:

1. to identify patients with suspicions of a possible diffuse liver damage;
2. within limits to set hypothesis of the diagnosis, which would guide the further diagnostic path.

Characteristic symptoms.

Diagnostic performance during the investigation must be targeted for detection of the two most common diffuse liver lesions: liver steatosis and liver fibrosis or cirrhosis at a possibly early stage.

It is recommended to divide ultrasound characteristics to be evaluated in abdominal US into two groups: First group - features that should be evaluated in the upper abdomen

during the routine US procedure; Second group – features that should be sought by finding the first signs of change in the 1st group. These signs should also be assessed in cases when the aim of the US investigation is a clinical suspicion of an existing diffuse liver damage.

During each upper abdominal US it is recommended to evaluate the following characteristics:

1. homogeneity of liver tissue;
2. echogenicity of the structure;
3. surface (capsule) smoothness;
4. attenuation of the signal reflected from structures located in different depths;
5. visualization of portal vascular walls and diaphragm;
6. type of blood flow in the right hepatic in color and spectral dopplerography;
7. size of the spleen;
8. ascitis.

Finding changes in any of these parameters, further assessment of the following characteristics must be performed:

1. structural homogeneity in subcapsular parts (of about 2 cm depth), assessing with high-frequency (around 7.5 MHz) linear probe;
2. diameter of the portal vein, type of the blood flow in the portal vein with colour Doppler and spectral Doppler imaging;
3. portocaval anastomoses.

Interpretation.

Echostructure of healthy liver is homogenous in all its parts. Coarsening of echostructure and tiny nodularity are early signs of liver cirrhosis, which better can be assessed with a high-frequency probe in subcapsular areas.

Liver tissue echogenicity normally is moderately high. This is compared with the echogenicity of the right kidney in terms of one and the same depth. Echogenicity of the renal cortex must be equal or slightly lower. Here we should also take into account eventual alterations of echogenicity of the renal cortical layer in case of various diffuse renal damage.

Increase of echogenicity of liver parenchyma is caused by fat deposits in the liver, which increase the amount of reflective surface echoes. This symptom is typical to steatosis that is greater than 20% -33%.

Roughness of liver surface (capsule) is an early sign of cirrhosis, which coincides with the tiny nodularity of the structure. This symptom is better assessed with a high frequency linear probe.

The signal intensity reflected from deeper and shallower fields in a healthy liver is the same. Symptom of "shading" of deep fields caused by increased attenuation of the signal in case of steatosis, is to be found along with an increase of echogenicity of superficial parts. Application of this feature might be affected by the accuracy of ultrasound system settings.

Worsening of visualization of portal vein walls and the diaphragm line in case of steatosis can be explained with the reduction in acoustic density difference between liver parenchyma and duct walls.

Biphasic or monophasic waveform of liver veins is a sensitive, but non-specific symptom which can indicate both liver steatosis as well as fibrosis. It should be noted that changes in hepatic venous Doppler spectrum might also be caused by some other conditions and disorders, such as heart disease or pregnancy. Finding a biphasic or monophasic VHDx Doppler waveform in patients with a normal liver B mode image, hepatic steatosis should be concerned as the first most likely reason. Data on probability of finding an abnormal VHDx waveform in healthy subjects in various studies are controversial.

Spleen size may increase in many diseases. In cases of liver cirrhosis, it is one of the earliest symptoms, especially valuable in patients with chronic hepatitis.

In healthy subjects, blood flow in the portal vein is hepatopetal. Hepatofugal flow reliably indicates a portal hypertension. Finding a hepatopetal flow does not rule out the possibility of liver cirrhosis, which can be explained with shunting through portocaval branches of the portal veins. Portal vein size, its change during respiratory cycle phases, flow rate of the portal vein, pulsatility of the Doppler waveform and its characteristic indexes as well as congestion index are other parameters that are used in the diagnosis of liver cirrhosis. Their diagnostic value in different studies is variable. These parameters are suggested to be used only in complex with other features.

Finding signs of liver steatosis (increase of the structure echogenicity, ‘shadowing’ of the deepest fields, burdened visualization of the diaphragm line and of portal vein wall, flattening of VHDx Doppler waveform) the diagnosis of steatosis is considered to be reliable. Further investigations should be performed as clinically indicated. Ultrasound assessment of severity of steatosis in B mode, which usually is performed according to three-grade system (mild, moderate, severe), is considered as insufficiently reliable. The usual US findings is more typical for the form of macronodular steatosis, however, precise differentiation among the morphology variations on the basis of US data is not possible. Assessing the role of US in the detection of liver steatosis, subjectiveness of the US method must be noted as well as relatively high inter- and intraobserver variability. Based solely on US data, up to 33% steatosis may remain undiscovered.

Coarsened echostructure, surface roughness, tiny nodularity of subcapsular tissues, abnormal shape of VHDx Doppler waveform and spleen enlargement are symptoms that reliably indicate the likelihood of liver cirrhosis in its early stages. Alterations of the portal flow, portal hypertension symptoms, and size of certain liver parts and changes of relationship among them are characteristic to more advanced stages of cirrhosis. Ability of ultrasound to assess liver fibrosis in pre-cirrhotic stages of the disease should be assessed critically, although some studies have obtained data on potentialities of the Doppler imaging of liver veins to differentiate degrees of fibrosis from each other. In assessment of the degree of fibrosis in pre-cirrhotic stages the preferred method is a combination of transient elastography (Fibroscan) and a complex of laboratory analysis (Fibrotest etc.) which is not yet available in Latvia. Puncture biopsy still remains the “gold standard” to diagnose liver fibrosis.

5. Conclusions

1. Ultrasound spectral Doppler imaging is a highly informative radiological diagnostic method to determine certain stages and forms of liver fibrosis and steatosis in chronic hepatitis C patients.
2. A high degree hepatic fibrosis affects blood flow in the veins in the form of a flattened (biphasic or monophasic) Doppler waveform.
3. Diagnostic sensitivity of Doppler ultrasound in case of detection of severe fibrosis or cirrhosis is 83.3%, specificity 71.4%, PPV 29,4%, NPV 96,8%.
4. Dopplerography of liver veins does not make possible to distinguish mild and moderate fibrosis and healthy liver, neither to differentiate among early forms of fibrosis.
5. Moderate and severe liver steatosis increases frequency of abnormal levelled waveforms; for mild steatosis levelled Doppler waveform is not typical.
6. Diagnostic sensitivity of Doppler ultrasound imaging in determination of medium and severe steatosis is 37.5%, specificity 76.1%, NPV 91.1%, PPV 20%.
7. Gender and body weight of a patient has no statistically significant effect on the shape of Doppler waveform.
8. Inflammatory activity in patients with viral hepatitis C does not affect blood flow in liver veins and raises no alterations in VHDx Doppler waveform.

6. References

1. Abdi W, Millan JC, Mezey E et al. Sampling variability on percutaneous liver biopsy. *Arch Intern Med* 1979;139:667-669.
2. Altinkaya N, Koc Z, Ulsan S et al. Effects of respiratory manoeuvres on hepatic vein Doppler waveform and flow velocities in a healthy population. *Eur J Radiology* 2010 in press.
3. Arada K, Ofelli M, Calikoglu U et al. Hepatic vein Doppler waveform changes in early stage (Child-Plugh A) chronic liver parenchymal diseases. *J Clin Ultrasound* 1997;25:15-19.
4. Aube Ch, Winkfield B, Oberti F et al. New Doppler ultrasound signs improve non-invasive diagnosis of severe liver fibrosis. *Eur J Gastroenterol Hepatol* 2004;16:743-751.
5. Barkat M. Non-pulsatile hepatic and portal vein waveforms in patients with liver cirrhosis: concordant and discordant relationships. *British J of Radiology* 2004;77:547-550.
6. Baunsgaard P, Sanchez GC, Lundborg CJ et al. The variation of pathological changes in the liver evaluated by double biopsies. *Acta Pathol Microbiol Scand* 1979;87:21-57.
7. Bedosa P, Dargere D and Paradis V. Sampling variability of liver fibrosis in chronic hepatitis C. *Hepatology* 2003;38:1449-1457.

8. Bernatik T, Strobel D, Hahn EG, Becker D. Doppler measurements: a surrogate marker of liver fibrosis? *Eur J Gastroenterol Hepatol* 2002;14:383-387.
9. Bolondi L, Bassi SL et al. Liver cirrhosis: changes of Doppler waveform of hepatic veins. *Radiology* 1991;178:513-516.
10. Bravo AA, Sheth SG, Chopra S. Liver biopsy. *NEJM* 2001;344:495-500.
11. Brunt EM, Janney CG, Di Bisceglie AM et al. Nonalcoholic steatohepatitis: a proposal for grading and staging the histological lesions. *Am J Gastroenterology* 1999;94:2467-2474.
12. Buscarini E, Di Stasi M. Complications of abdominal interventional ultrasound. *Poieto edizioni* 1996;34-47.
13. Cadarnel J-F, Rufat P, Degos F. Practices of liver biopsy in France: results of a prospective nationwide survey. *Hepatology* 2000;32:744-481.
14. Cales P, Oberti F, Michalak S et al. A novel panel of blood markers to assess the degree of liver fibrosis. *Hepatology* 2005;42:1373-1381.
15. Colli A, Cocciolo M, Riva C, Martinez E et al. Abnormalities of Doppler waveform of the hepatic veins in patients with chronic liver disease: correlation with histological findings. *AJR* 1994;162:833-837.
16. Colloredo G, Guido M, Sonzogni A, Leandro G. Impact of liver biopsy size on histological evaluation of chronic viral hepatitis: the smaller the sample, the milder disease. *J of Hepatology* 2003; 39/2 :239-244.

17. Couinaud C. Le foie. Études anatomiques et chirurgicales. Paris: Masson et Cie. 1957:187-208 (Fre).
18. Dietrich CF, Lee J-H, Gottschalk R, Herrmann C et al. Hepatic et portal vein flow pattern in correlation with intrahepatic fat deposition and liver histology in patients with chronic hepatitis C. AJR 1998;171:437-443.
19. Fiore G, Fera G, Napoli N et al. Liver steatosis and chronic hepatitis C: a spurious association? Eur J Gastroenterol Hepatol 1998;8:125-129.
20. Franck P, Hahn EG. Significance of serum matrix proteins in the diagnosis of cirrhosis. Montrouge, France: John Libbey Eurotext 1992;216:333-343.
21. The French METAVIR cooperative study group. Intraobserver and interobserver variations in liver biopsy interpretation in patients with chronic hepatitis C. Hepatology 1994;20:15-20.
22. Haktanir A, Songul B, Celenk C et al. Value of Doppler sonography in assessing the progression of chronic viral hepatitis and in the diagnosis and grading of cirrhosis. J Ultrasound Med. 2005;24:311-321.
23. Hamato N, Moriyasu F, Someda H, Nishikawa K, Chiba T et al. Clinical application of hepatic venous haemodynamics by Doppler ultrasonography in chronic liver disease. Ultrasound Med Biol 1997;23:829-835.
24. Von Herbay A, Frieling T et al. Association between duplex Doppler sonographic flow pattern in right hepatic vein and various liver diseases. J Clin Ultrasound. 2001;29:25-30.

25. Hirata M, Akbar SM, Noriike N et al. Noninvasive diagnosis of degree of hepatic fibrosis using ultrasonography in patients with chronic liver disease due to hepatitis C virus. *Eur J Clin Invest*; 2001;31:528-535.
26. Hohlund B, Poulsen H, Schlichting P. Reproducibility of liver biopsy diagnosis in the relation to the size of specimen. *Scand J Gastroenterol* 1980;15:129-235.
27. Hourigan LF, Macdonald GA, Purdie D et al. Fibrosis in chronic hepatitis C correlates significantly with body mass index and steatosis. *Hepatology* 1999;29:1215-1219.
28. Karabulut N, Kazil S, Jagaci B. et al. Doppler waveform of the hepatic veins in an obese population. *Eur Radiology* 2004;14:2268-2272.
29. Knodell RG, Ishak KG, Black WC et al. Formulation and application of a numerical scoring system for assessing histological activity in asymptomatic chronic active hepatitis. *Hepatology* 1981;1:431-435.
30. Lim AKP, Patel N, Eckersley RJ et al. Can Doppler sonography grade the severity of hepatitis C-related liver disease? *AJR* 2005;184:1848-1853.
31. Lonardo A, Loria P, Adinolfi LE et al. Hepatitis C and steatosis: a reappraisal. *J Viral Hepatitis* 2006;13:73-80.
32. Maharaj B, Maharaj RJ, Leary WP et al. Sampling variability and its influence on diagnostic yield of percutaneous needle biopsy of the liver. *Lancet* 1986;1:523-525.
33. Marchesini G, Brisi M, Morselli-Labate AM et al. Association of nonalcoholic fatty liver disease with insulin resistance. *Am J Med* 1999;107:450-455.

34. McPherson S, Jonsson JR, Cowin GJ et al. Magnetic resonance imaging and spectroscopy accurately estimate the severity of steatosis provided the stage of fibrosis is considered. *J of Hepatology* 2009;51:389-397
35. Myers RP, Tainturier MH, Ratziu V et al. Prediction of liver histological lesions with biochemical markers in patients with chronic hepatitis B. *J of Hepatology* 2003;39:222-230.
36. Naveau S, Raynard B, Ratziu V et al. Biomarkers for prediction of liver fibrosis in patients with chronic alcoholic liver disease. *Clin Gastroenterol Hepatol* 2005;3(2);167-174.
37. Nord JH. Biopsy diagnosis of cirrhosis: blind percutaneous versus guided direct vision techniques. A review. *Gastrointest Endosc* 1982;28:102-104.
38. O'Donohue J, Chaan NG, Catnach Ng.C et al. Diagnostic value of Doppler assessment of the hepatic and portal vessels and ultrasound of the spleen in liver disease. *Eur J Gastroenterol Hepatol* 2004;16:147-155.
39. Oguzkurt L, Yildirim T, Torun D et al. Hepatic vein Doppler waveform in patients with diffuse fatty infiltration of the liver. *Eur J Radiol* 2005;54:253-257.
40. Piscaglia F, Gaiani S, Calderoni D. et al. Influence of liver fibrosis on hepatic artery Doppler resistance index in chronic hepatitis of viral origin. *Scand J Gastroenterol* 2001;36:647-652.
41. Piscaglia F, Gaiani S, Zironi G et al. Intra and extrahepatic arterial resistance in chronic hepatitis and liver cirrhosis. *Ultrasuond Med Biol* 1997;23:675-682.

42. Poynard T, Imbert-Bismut F, Munteanu M et al. Overview of the diagnostic value of the biochemical markers of liver fibrosis (FibroTest, HCV-Fibrosure) and necrosis (ActiTest) in patients with chronic hepatitis C. *Comp Hepatol* 2004;3:8.
43. Poynard T, Ratziu V, McHutchison J et al. Effect of treatment with peginterferon or interferon alfa-2b and ribavirin on steatosis in patients infected with hepatitis C. *Hepatology* 2003;38:75-85.
44. P.Priedītis, G.Krūmiņa, L.Vīksna. Doplerogrāfijas iespējas aknu fibrozes diagnostikā C vīrusu hepatīta pacientiem. *RSU Zinātniskie raksti* 2008:61-66
45. Regev A, Berho M, Jeffers LJ et al. Sampling error and intraobserver variations in liver biopsy in patients with chronic HCV infection. *Am J Gastroenterology* 2004;97:2614-2618.
46. Roobottom CA, Hunter JD, Westson MJ et al. Hepatic venous Doppler waveforms: changes in pregnancy. *J Clin Ultrasound* 1995;23:477-482.
47. Rubbia-Brandt L, Qadri R, Abid K et al. Hepatocyte steatosis is a cytopathic effect of hepatitis C virus genotype 3. *J of Hepatology* 2000;33:106-115.
48. Schneider ARJ, Teuber G, Kriener S, Caspary WF. Noninvasive assessment of liver steatosis, fibrosis and inflammation in chronic hepatitis C virus infection. *Liver international* 2005; 25:1150-1155.
49. Techgraber UK, Gebel M, Benter T et al. Effect of respiration exercises and food intake on hepatic vein circulation. *J Ultrasound Med* 1997;16:549-554.
50. Wasley A, Alter MJ. Epidemiology of hepatitis C: geographic differences and temporal trends. *Semin Liver Dis* 2000;20:1-16.

7. Reports a Publications by the Author

7.1. Reports in Recognized Journals and Medical Magazines

L.Vīksna, V.Sondore, A.Jēruma, P.Priedītis, I.Štrumfa et al. Liver biopsy. Book1. Noninvasive alternatives of liver biopsy. ISBN 978-953-307-308-8. (accepted).

P.Priedītis, G.Krūmiņa, L.Vīksna, I.Štrumfa. Hepatic veins circulation impacting conditions: Dopplerographic and morphological correlation in chronic virus hepatitis C patients. Medicinos teorija ir praktika 2011. Vol 17, no 2 (accepted)

Tulin A, Prieditis P, Strumfa I, Kornilova-Filusina VV. Carcinoid of the Jejunum with Liver Metastases and Metachrone Gastric Cancer. Ann Surg Hepatol 2010;15:90-95. (rus)

A.Ozolins, Z.Narbutis, I.Strumfa, P.Prieditis, J.Gardovskis. Diagnosis and Management of the Thyroid Nodules. Acta Chirurgica Latviensis 2010 ;10/2:86-90.

P.Priedītis, G.Krūmiņa, L.Vīksna, I.Štrumfa. Steatozes un ķermeņa masas ietekme uz hemodinamiku aknu vēnās hroniska vīrushepatīta C slimniekiem. RSU Zinātniskie raksti 2010. (accepted)

A.Vanags, M.Pavārs, P.Priedītis, I.Strumfa et al. Biliary Cystic Tumors with Mesenchymal Stroma. Acta Chirurgica Latviensis 2009;9:95-99

P.Priedītis, G.Krūmiņa, L.Vīksna. Doplerogrāfijas iespējas aknu fibrozes diagnostikā C vīrusu hepatīta pacientiem. RSU Zinātniskie raksti 2008:61-66

A.Vanags, M.Pavārs, P.Priedītis. Biliary Cystadenocarcinoma: a Case Study of a Rare Tumor. Acta Chirurgica Latviensis 2008;8:90-93

P.Priedītis, A.Strazdiņa. Steatohepatozes radioloģiskās diagnostikas iespējas. Latvijas ārsts 2009;5:18-21

P.Priedītis. Angiogēno erektilo disfunkciju ultrasonogrāfiskā diagnostika. Doctus 2004;8:34-37

P.Priedītis. Nefrokalciņoze un citi hiperehogēnie nieru bojājumi. Latvijas Ārsts 1995; 2:42-44

P.Priedītis.Vairogdziedzera punkcijas ultraskaņas kontrolē. Latvijas Ārsts 1993;3:281-282

7.2. Scientific Reports in Congresses and Conferences

P.Priedītis. Liver Fibrosis and Steatosis: the Role of Radiology.3rd Baltic Congress of Radiologists, Riga, 2010. Abstract

P. Priedītis, G. Krūmiņa, I.Štrumfa, L. Vīksna. Impact of Steatosis and Body Obesity on Hemodynamic of Liver Veins in Patients with Chronic Viral Hepatitis C. RSU Scientific Conference. Riga, 2010. Abstract 165.

P. Priedītis. Diagnostic Capabilities of Diffuse Liver Disease – steatohepatosis and Viral Hepatitis C. Interdisciplinary Conference of Latvian Society of Doctors, Riga 2008.

P.Priedītis, G.Krumina, I.Strumfa, L.Viksna. Hepatic Vein Flow Pattern in Patients with Chronic Hepatitis C. Correlation with Degree of Liver Steatosis and Fibrosis. XXth Congress of European Federation of Societies for Ultrasound in Medicine and Biology. 2008, Timisoara, Romania. European J of Ultrasound 2008; 29:S4

P. Priedītis, G. Krūmiņa, L. Viksna. Value of Dopplerography in Determining the Severity of Liver Fibrosis in Viral Hepatitis C Patients - pilot study. RSU Scientific Conference, 2008, Riga. Abstract 124

S.Tkhor, P.Priedītis Treatment of Recurrent Varicose Vein. 48.Deutschen Geselleschaft für Phlebologie. Rostock 2006. Phlebologie 2006;35:A-51

A.Tulin, K.Kupcs, P.Priedītis, R.Rībenieks. Percutaneous Transcatheteral Endobiliar Diagnostic and Treatment. Ann Surg Hepatol. 2005;10(2),65

P.Priedītis. Thyroid Disease – the Chernobyl Experience. VII Naukowy Zajazd Polskego Towarzystwa Ultrasonograficznego poland, Kielce 2004. Ultrasonografia 2004;17:12

P.Priedītis. Hydatid Disease of the Liver. VII Naukowy Zajazd Polskego Towarzystwa Ultrasonograficznego. Poland, Kielce 2004. Ultrasonografia 2004;17:24

A.Tuļins, J.Gardovskis, P.Priedītis. Surgery of Non-parasitary Liver Cysts. 1st Latvian Congress of Surgeons, Riga 2000. Abstract 36.

A.Tulin , K.Kupcs, P.Priedītis, R.Ribenieks, J.Proskurina. First Experience of Biliary Nitinol Stent Implantation. Baltic Congress of Surgery, 2004;Liepaja, Latvia.

S.Dzelzīte, J.Jansons, D.Krieviņš, K.Kupčs, P.Priedītis. Potentialities of Non-invasive Investigations of Carotid Arteries. World Congress of Latvian Doctors, Riga 2001.

P. Priedītis. Ultrasonographic Diagnosis of Erectile Dysfunction. World Congress of Latvian Doctors, Riga 2001.

8. List of Figures

Figure 1. Pathological VHDx frequency curves depending on the degree of liver fibrosis. .	19
Figure 2. Proportion of patients according to the type of VHDx waveform depending on the severity of liver steatosis.....	24
Figure 3. Increase of the frequency of abnormal VHDx Doppler waveform in relation with the degree of liver steatosis.....	25
Figure 4. Increase of frequency of abnormal VHDx curves in relation to the degree of steatosis in the groups of fibrosis.....	27
Figure 5. Increase in frequency of moderate to severe hepatic steatosis depending on body weight.....	29

9. List of Tables

Table 1. Absolute and relative frequency of VHDx Doppler waveform in the study group patients.....	14
Table 2. Absolute and relative frequency of VHDx Doppler waveform in the control group patients.....	15
Table 3. Absolute and relative distribution of patients in groups of fibrosis.....	16
Table 4. Absolute and relative distribution of patients in groups of steatosis.....	17
Table 5. Frequencies of pathological VHDx curves depending on the degree of liver fibrosis.	18
Table 6. Frequency of VHDx Doppler waveform types depending on the degree of liver fibrosis in patients without liver steatosis (n-67).....	20
Table 7. Frequency of VHDx Doppler waveform types depending on the degree of liver fibrosis in patients with mild liver steatosis (n-78).....	20
Table 8. Frequency of VHDx Doppler waveform types depending on the degree of liver fibrosis in patients with moderate liver steatosis (n-31).	21
Table 9. Frequency of VHDx Doppler waveform types depending on the degree of liver fibrosis in patients with severe liver steatosis (n-9).....	22
Table 10. Type of VHDx Doppler waveform in relation with the degree of liver steatosis...	23
Table 11. Frequencies of pathological VHDx curves depending on the degree of liver steatosis.	24
Table 12. Frequency of types of VHDx waveform in relation to the degree of liver steatosis in patients without liver fibrosis or those with mild forms (F 0-1).....	26
Table 13. Frequency of VHDx Doppler waveform types in relation to the degree of liver steatosis in patients with moderate liver steatosis (F-3).	26
Table 14. Severity rate of liver steatosis in relation to body mass index.....	29
Table 15. Type of VHDx waveform in relation with the average body mass index (kg/m ²).	30

10. Abbreviations Used

BMI – Body Mass Index

CT – Computed Tomography

CVHC – chronic virus hepatitis C

HAI – hepatitis activity index

MRI - Magnetic Resonance Imaging

NPV – Negative Predictive Value

PPV – Positive Predictive Value

US – Ultrasonography

VCI – *Vena Cava Inferior*

VH – Hepatic Veins

VHDx – *V.Hepatica Dextra*

VHDxI – *Vena Hepatica Dextra Inferior*