

# RADIOGRAPHIC AND FUNCTIONAL OUTCOME AFTER TOTAL HIP ARTHROPLASTY (THA) IN DYSPLASTIC HIPS DUE TO THE PLACEMENT OF ACETABULAR COMPONENT

S. Zebolds<sup>1,2</sup>, A. Jumtins<sup>1</sup>, Z. Pavare<sup>1</sup>

<sup>1</sup> Rīga Stradiņš University,

<sup>2</sup> State Hospital of Traumatology and Orthopaedics | Riga, Latvia

## INTRODUCTION

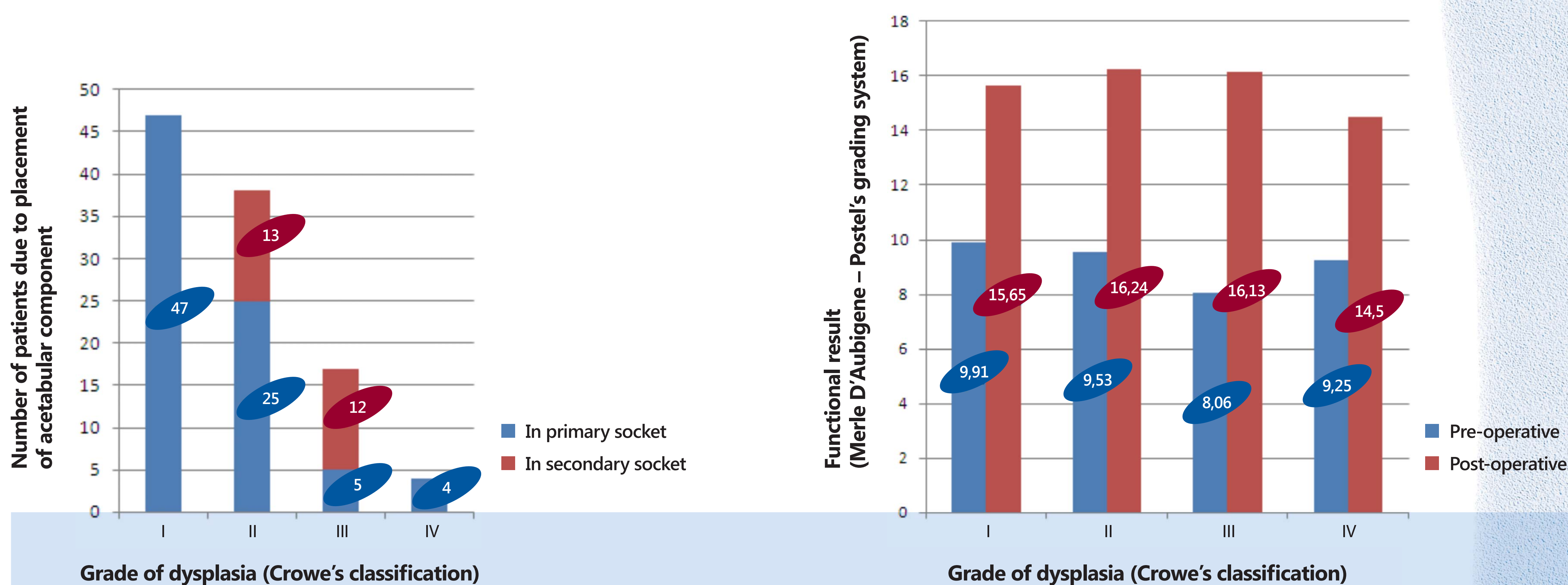
Due to severe changes in the anatomy in dysplastic hip patients (pts) there is not always possible to place the acetabular component of endoprosthesis (EP) in the primary (anatomic) socket. Another choice in Crowe type III,IV dysplasia patients is the placement of acetabular cups in the secondary socket. The aim of the study was to analyze and compare the radiographic and functional outcome after THA in dysplastic hips in association with the placement of acetabular component.

## MATERIALS AND METHODS

In 2008-2011 106 THAs were performed in 88 dysplastic hip patients in Riga State Hospital of Traumatology and Orthopaedics. The follow-up period was 12 – 60 months. Crowe's classification was used for the evaluation of the grade of dysplasia. Pre- and post-operative digital measurements were done using special orthopaedic programmes (AGFA, IMPAX). Merle d'Aubigne and Postel's grading system was used for the functional assesment of the hip joint. In 28 cases instrumental gait analysis (IGA) was done 1 year postoperatively. Gait deviation index (GDI) was calculated for each patient.

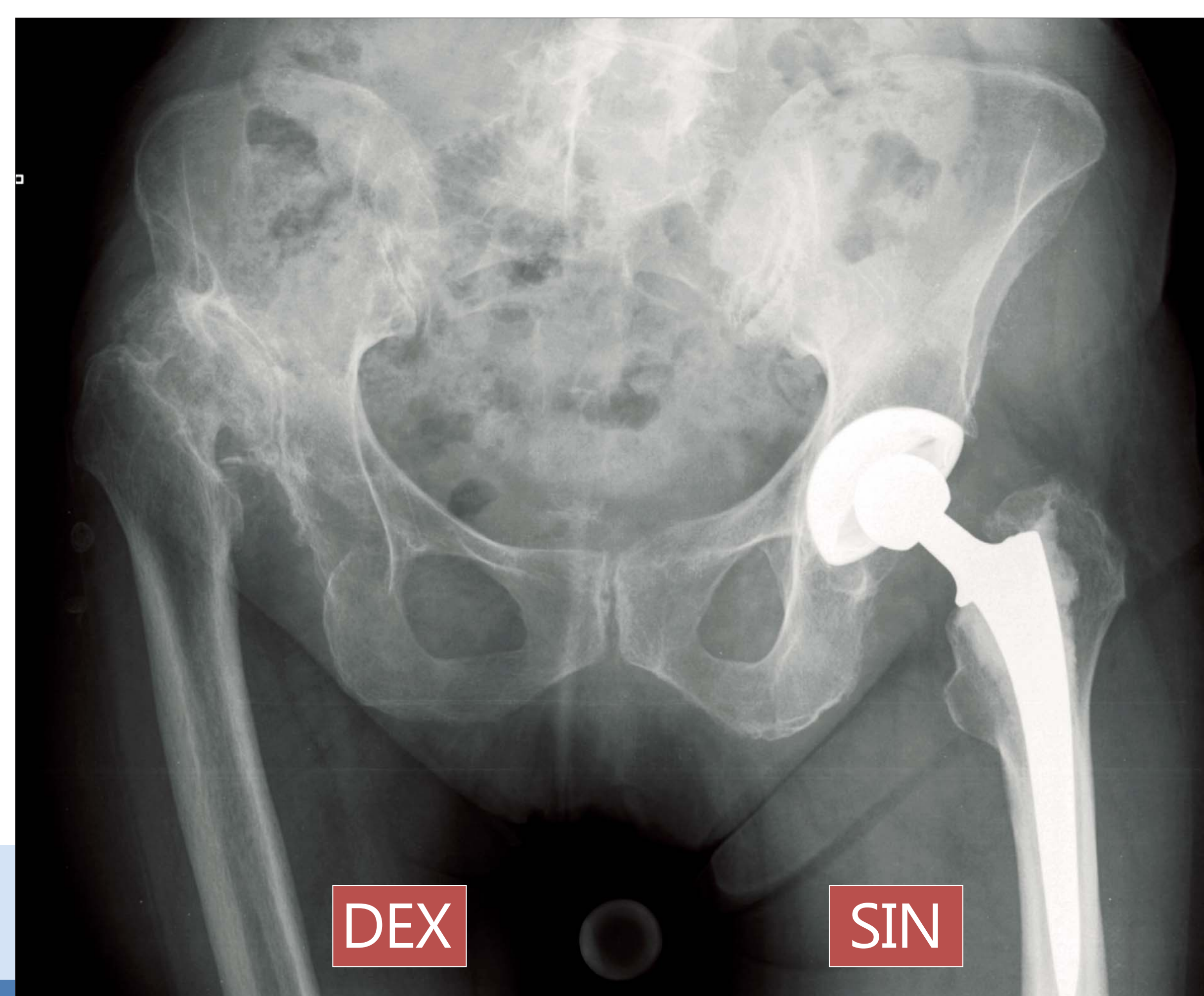
## RESULTS

70 patients(pts) underwent unilateral THA, 18 bilateral. 80.7% were females, 19.3% males. Mean age was 44.4 years. Due to Crowe's classification 47 were type I, 38 with II, 17 type III and 4 type IV dysplasia pts. 81 cups (76.4%) were placed in the primary socket, 25 (23.6%) in the secondary. Our study 1 year after THA showed slightly better functional outcome for those with a cup placed in the secondary socket than in the primary (16.31 against 15.80 points according to Merle d'Aubigne – Postel's scoring system). Calculated GDI was also little better in the group with the acetabular components placed in the secondary socket than in the primary (86.3 points against 83.14). The difference between both groups was not statistically significant (p=0,235).

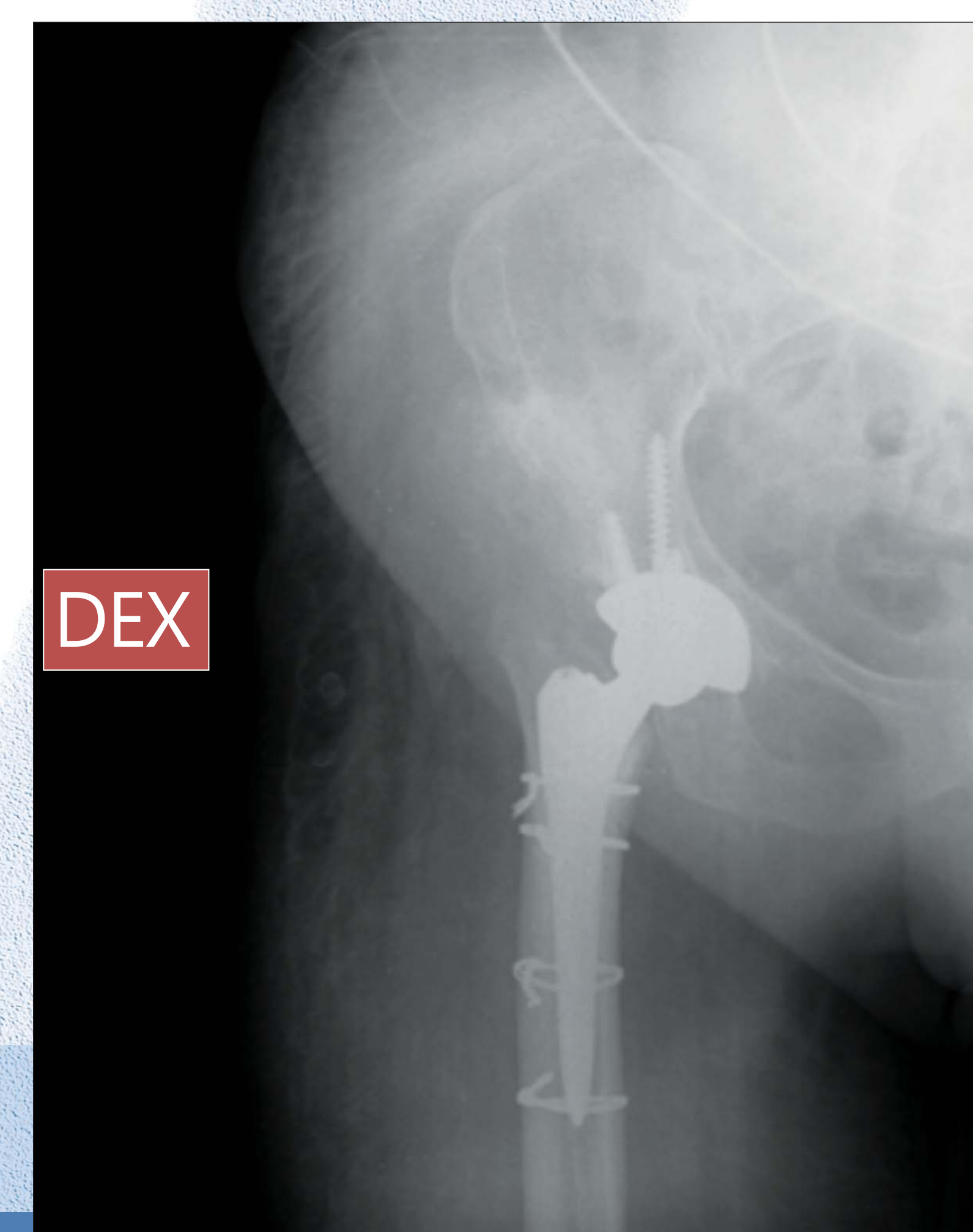


## COMPLICATIONS

Totally complication rate (in both groups) was 9.83%. Most of them were fractures of the proximal femur (7 cases), but also 1 fracture of ischial bone and 2 nerve palsies. All complications were in the patients group with the cup's placement in the primary socket.



Crowe type IV dysplasia of the right hip joint. Female, 68 y.o.



Fracture of proximal femur during THA (osteosynthesis with 4 cerclages) Female, 68 y.o.

## CONCLUSIONS

- In severe dysplasia cases the positioning of acetabular component in the primary socket can increase the complication rate.
- Low complication rate and also good functional result in Crowe type III, IV dysplasia cases is possible to achieve by placing acetabular cups into the secondary socket.